

ACTA MYOLOGICA

(Myopathies, Cardiomyopathies and Neuromyopathies)

Vol. XXXVII - March 2018

Official Journal of
Mediterranean Society of Myology
and
Associazione Italiana di Miologia

Founders: Giovanni Nigro and Lucia Ines Comi

Three-monthly

EDITOR-IN-CHIEF

Luisa Politano

ASSISTANT EDITOR

Vincenzo Nigro

CO-EDITORS

Lefkos Middleton

Gabriele Siciliano

Giuseppe Novelli

Haluk Topaloglu

Reinhardt Rüdel

Antonio Toscano



PACINI
EDITORE
MEDICINA

Established in 1982 as *Cardiomyology*

ACTA MYOLOGICA

(Myopathies, Cardiomyopathies and Neuromyopathies)

**Official Journal of
Mediterranean Society of Myology
and
Associazione Italiana di Miologia**

Founders: Giovanni Nigro and Lucia Ines Comi

Three-monthly

EDITORIAL BOARD

Corrado Angelini, Padova
Enrico Bertini, Roma
Serge Braun, Paris
Kate Bushby, Newcastle upon Tyne
Kevin P. Campbell, Iowa City
Marinos Dalakas, Athens
Feza Deymeer, Istanbul
Salvatore Di Mauro, New York
Denis Duboc, Paris
Victor Dubowitz, London
Massimiliano Filosto, Brescia
Fayçal Hentati, Tunis
Frank Lehmann-Horn, Ulm
Michelangelo Mancuso, Pisa
Giovanni Meola, Milano
Eugenio Mercuri, Roma
Carlo Minetti, Genova

Clemens Müller, Würzburg
Francesco Muntoni, London
Carmen Navarro, Vigo
Gerardo Nigro, Napoli
Anders Oldfors, Göteborg
Elena Pegoraro, Padova
Heinz Reichmann, Dresden
Filippo Maria Santorelli, Pisa
Serenella Servidei, Roma
Piraye Serdaroglu, Istanbul
Yeuda Shapira, Jerusalem
Osman I. Sinanovic, Tuzla
Michael Sinnreich, Montreal
Andoni J. Urtizberea, Hendaye
Steve Wilton, Perth
Massimo Zeviani, London
Janez Zidar, Ljubljana



EDITOR-IN-CHIEF

Luisa Politano, Napoli

ASSISTANT EDITOR

Vincenzo Nigro, Napoli

CO-EDITORS

Lefkos Middleton, Nicosia

Giuseppe Novelli, Roma

Reinhardt Rüdel, Ulm

Gabriele Siciliano, Pisa

Haluk Topaloglu, Ankara

Antonio Toscano, Messina

EDITORIAL STAFF

TBA

BOARD OF THE MEDITERRANEAN SOCIETY OF MYOLOGY

H. Topaloglu, *President*

L.T. Middleton, G. Siciliano, *Vice-presidents*

K. Christodoulou, *Secretary*

L. Politano, *Treasurer*

E. Abdel-Salam, M. Dalakas, F. Deymeer, F. Hentati, G. Meola, Y. Shapira, E. Tizzano, A. Toscano,

J. Zidar

Co-opted Members: V. Askanas, S. Di Mauro, R. Rüdel

Acta Myologica publishes 4 issues per year in March, June, September, December. The Journal is available in OPEN ACCESS at: www.actamyologica.it

Acta Myologica is cited in Index Medicus/MEDLINE, Medicine, Excerpta Medica Database (EMBASE), Index Copernicus and monitored for coverage in Chemical Abstracts Service. The Journal is available on PubMed Central (<http://www.ncbi.nlm.nih.gov/pmc/journals/1221/>).

All correspondence should be addressed to: Mediterranean Society of Myology - Cardiomyology and Medical Genetics - Primo Policlinico - Piazza Miraglia - 80138 Naples, Italy - Tel. +39 081 566 5300 - Fax +39 081 566 5101.

Editor in Chief: Luisa Politano

Tribunal Authorization, Napoli N. 3827, January 10, 1989 - Journal registered at "Registro pubblico degli Operatori della Comunicazione" (Pacini Editore srl registration n. 6269 - 29/8/2001).

The editor remains at the complete disposal of those with rights whom it was impossible to contact, and for any omissions.

© 1981 Gaetano Conte Academy. All rights reserved.

The Journal and the individual contributions contained in it are protected by the copyright of Gaetano Conte Academy and the following terms and conditions apply to their use:

Photocopies, for personal use, are permitted within the limits of 15% of each publication by following payment to SIAE of the charge due, article 68, paragraphs 4 and 5 of the Law April 22, 1941, No 633.

Reproductions for professional or commercial use or for any other other purpose other than personal use can be made following a written request and specific authorization in writing from AIDRO, Corso di Porta Romana, 108, 20122 Milan, Italy, E-mail: segreteria@aidro.org and web site: www.aidro.org.

Publisher

Pacini
Editore

Via A. Gherardesca - 56121 Pisa, Italy

Published by Pacini Editore Srl - Pisa, Italy, May 2018

CONTENTS

EDITORIAL

Luisa Politano	1
----------------------	---

ORIGINAL ARTICLE

<i>SIGMAR1 gene mutation causing Distal Hereditary Motor Neuropathy in a Portuguese family</i> Luciano José Almendra Frias Vieira, Francisco Eduardo Da Rocha Laranjeira and Luís Jorge Mendonça Peres Negrão	2
---	---

CASE REPORT

<i>Usefulness of the external loop recorder in a patient with Myotonic Dystrophy type 1 and recurrent episodes of palpitations: evaluation of the follow-up from diagnosis to 6 month-post-cardiac interventional treatment</i> Anna Rago, Andrea Antonio Papa, Dario Galante, Antonio Cassese and Paolo Golino	5
--	---

PROCEEDINGS OF THE XVIII CONGRESS OF THE ITALIAN ASSOCIATION OF MYOLOGY **Genoa, Italy – June 6-9, 2017**

Scientific Programme	9
Abstracts of invited lectures	35
Abstracts of oral communications	46
Muscle Club Session	58
Abstracts of poster communications	60
Informazioni Scientifiche	90

NEWS FROM AROUND THE WORLD

AIM	98
MSM	98
WMS	98

FORTHCOMING MEETINGS	99
-----------------------------------	----

Author Index	111
--------------------	-----

Instructions for Authors	116
--------------------------------	-----

EDITORIAL

With the first issue of the year 2018, a new chapter opens for *Acta Myologica*.

After 35 years of continuous direction of the journal by Prof. Giovanni Nigro, it is my honour and duty to carry on his work.

In this difficult task, the new entries Gabriele Siciliano, Haluk Topaloglu and Antonio Toscano will be of great help as Associate Editors. However, I also count very much on the contribution of the new members of the Editorial Board, Massimiliano Filosto, Michelangelo Mancuso, Giovanni Meola, Eugenio Mercuri, Elena Pegoraro, Filippo M. Santorelli and Massimo Zeviani.

Vincenzo Nigro – Assistant Editor of the Journal – and I decided to set up an “editorial staff” composed of

young and talented colleagues who will surely bring the enthusiasm and propulsion necessary for the further development of the Journal. Applications are open.

This issue hosts the Proceedings of the Congress of the Italian Association of Myology, which this year celebrates its eighteenth birthday in the splendid setting of Genoa.

My thanks to all those who have agreed to share this journey with us.

Luisa Politano
Editor-in-Chief of Acta Myologica

ORIGINAL ARTICLE

SIGMAR1 gene mutation causing Distal Hereditary Motor Neuropathy in a Portuguese family

LUCIANO ALMENDRA¹, FRANCISCO LARANJEIRA², ANA FERNÁNDEZ-MARMIESSE³,
LUÍS NEGRÃO¹

¹ Consulta de Doenças Neuromusculares, Centro Hospitalar e Universitário de Coimbra, Praceta Mota Pinto, 3000-075 Coimbra, Portugal; ² Centro de Genética Clínica, Centro Hospitalar do Porto;

³ Unidad de Diagnóstico y Tratamiento de Enfermedades Metabólicas Congénitas (UDyTEM), Hospital Clínico Universitario de Santiago de Compostela

SIGMAR1 gene encodes a non-opioid endoplasmic reticulum (ER) protein which is involved in a large diversity of cell functions and is expressed ubiquitously in both central and peripheral nervous systems. Alterations of its normal function may contribute to two different phenotypes: juvenile amyotrophic lateral sclerosis (ALS 16) and distal hereditary motor neuropathies (dHMN). We present the case of a female patient, of 37-years-old, with distal muscle weakness and atrophy beginning in childhood and slowly progressive in the first two decades of life. Neurological examination revealed a symmetrical severe muscle wasting and weakness in distal lower and upper limbs, with claw hands, footdrop with equinovarus deformity and hammer toes, generalized areflexia and normal sensory examination. The electrodiagnostic study revealed a pure chronic motor peripheral nerve involvement without signs of demyelination. The molecular study found the deletion c.561_576del on exon 4 and a deletion of all exon 4, in the **SIGMAR1** gene.

Key words: **SIGMAR1** gene, motor neuron disease, distal hereditary motor neuropathy

Introduction

The Distal Hereditary Motor Neuropathies (dHMN) comprise a heterogeneous group of diseases that share the common feature of a length-dependent predominantly motor neuropathy (1). To date 19 causative genes and four loci have been identified with autosomal dominant, recessive and X-linked patterns of inheritance (2). Despite advances in the identification of novel gene muta-

tions, 80% of patients with dHMN have a mutation in an as-yet undiscovered gene (3).

The sigma-1 receptor (s1R) encoded by the **SIGMAR1** gene, is a non-opioid endoplasmic reticulum (ER) protein, with a molecular mass of 24 kDa, which is involved in a large diversity of cell functions and is expressed ubiquitously in both central and peripheral nervous systems (4, 5). It is enriched in motor neurons of the brainstem and spinal cord and plays a role in wide variety of cellular functions being critical for neuronal survival and maintenance (6). Protein abnormal function has been implicated in several diseases such as Alzheimer's disease, schizophrenia, stroke, cognition and depression (5). More recently it has been associated with two different phenotypes of motor neuron disease: juvenile amyotrophic lateral sclerosis (ALS 16) (7) and distal hereditary motor neuropathy (dHMN) (2).

We present the clinical, neurophysiologic and molecular findings of a Portuguese patient with dHMN caused by a heterozygous compound mutation in the **SIGMAR1** gene.

Case report

The patient is a 37-year-old woman, the second offspring of a non-consanguineous couple. The patient's delivery was normal and she presented normal motor and intellectual development in the first years of life. She attended school successfully until the age of 15. There was no history of neuromuscular diseases in the family.

At the age of 4 it was noticed a different way of walk-

ing, clumsier with increasing falls. By the same time, she developed progressive distal muscle wasting and weakness of the lower limbs, more evident on the right foot. Her medical records from the pediatric orthopedic appointments reported feet orthopedic corrective surgeries performed at 8 and 10 years of age.

At the age of 16, the muscle weakness had progressed to involve the distal parts of upper limbs, with significant difficulty with fine hand movements. Since the end of the second decade, her neurological condition became stable.

At the age of 37, she presented symmetrically severe muscle wasting and weakness in distal lower and upper limbs, bilateral footdrop with equinovarus deformity and claw hands (Fig. 1). Walking was impossible on tiptoes

and heels. There was no evidence of fasciculation or upper motor neuron signs, nor signs of bulbar involvement. Muscle stretch reflexes were abolished throughout. Sensory examination was normal.

Neurophysiologic study showed normal sensory responses and unobtainable motor responses when recorded over the intrinsic muscles of the hands and feet. Muscle needle examination showed a few fibrillations potentials and positive sharp waves in the intrinsic muscles of the hands and feet and in the tibialis anterior bilaterally. These muscles were not voluntarily activated and motor unit potentials of increased duration and amplitude were recorded in the arm and forearm muscles and in the vastus medialis muscles, together with a significantly reduced muscle recruitment pattern. Ventilatory parameters were all normal, as well the cardiac evaluation. The parents had a normal clinical and neurophysiologic examination.

The molecular study (Fig. 2) included polymerase chain reaction and sequencing of the entire coding region, including the adjacent intronic regions, of the *SIGMAR1* gene (chromosome 9). Reference sequence: NM_005866.

It was found a frameshift/truncating hemizygous mutation, variant c.561_576del on exon 4 (p.Asp188Profs*69), and a macrodeletion encompassing all exon 4. These alterations were identified on father and mother, respectively. The c.561_576del on exon 4 (p.Asp188Profs*69) mutation is predicted to be pathogenic as it introduces a premature stop codon 69 aminoacids downstream, producing a truncated protein.

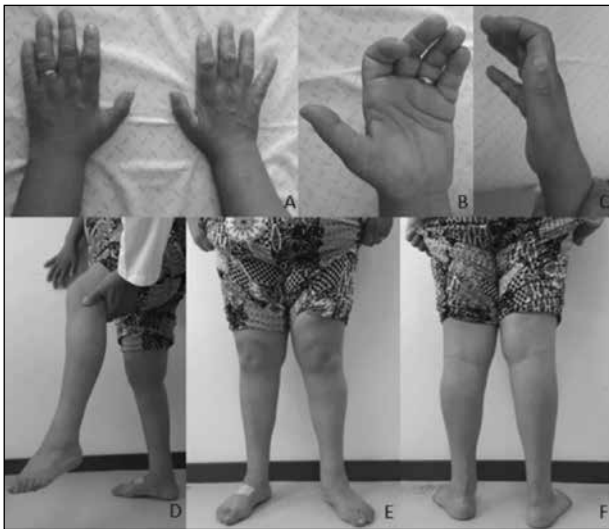

Figure 1. Claw hands with atrophy of the intrinsic hand muscles (**A**, **B**, **C**); Circumferential atrophy of distal legs with footdrop (**D**, **E**, **F**).

Discussion

The s1R plays an important role in cell maintenance and survival and its loss or malfunction causes

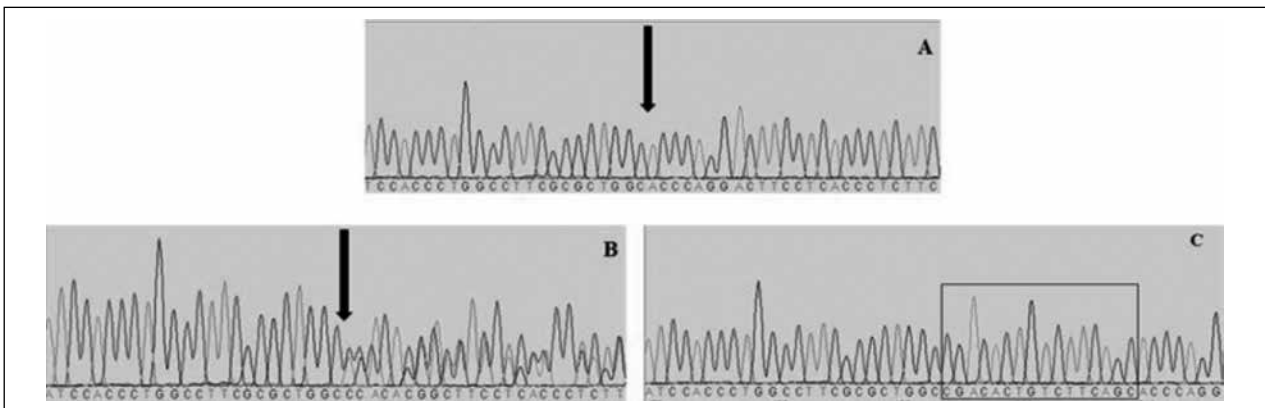


Figure 2. Sequencing electropherograms of proband (**A**) and both parents (**B**: father; **C**: mother). The deletion c.561_576del (arrow) is evident on both proband (**A**) and father (**B**). There is no evidence of the same deletion on mother's electropherogram (box) leading to the conclusion of a macrodeletion of all exon 4.

ER-mitochondria disconnection and ER stress activation and disrupts mitochondrial function and axonal transport, leading to axonal motor neuron degeneration with consequent cell death (8). This dying-back degeneration process would be consistent with the distal predominant pattern of motor involvement observed in patients with *SIGMAR1* gene mutations (9).

The clinical presentation of the first Portuguese patient with dHMN caused *SIGMAR1* gene mutations, has been previously reported (2). Similar to our patient, there was a clinical onset of a pure motor peripheral nerve involvement in the first decade of life, predominantly distal in lower limbs associated with feet deformities and subsequent progression to the upper limbs. There were no sensory symptoms or cognitive impairment, upper motor neuron signs or bulbar involvement. Our patient is still able to walk without support and she participated in the community activities.

However, recent reports suggest that *SIGMAR1* gene mutations should take part of the pool of genes that can cause overlapping motor neuron/nerve phenotypes, much like *BSCL2*- and *REEP1*-related disorders (9), as well as the recently described *KIF5A* (10), on either case there might be a combination of dHMN and pyramidal tract signs.

The rarity of dHMN and the even more rare dHMN caused by mutations of the *SIGMAR1* gene, with the few clinical cases described in the literature, make it difficult to be certain about the phenotypes that are associated with mutations of the *SIGMAR1* gene.

References

1. Rossor A, Kalmar B, Greensmith L, et al. The distal hereditary motor neuropathies. *J Neurol Neurosurg Psychiatry* 2012;83:6-14.
2. Li X, Hu Z, Liu L, et al. A *SIGMAR1* splice-site mutation causes distal hereditary motor neuropathy. *Neurology* 2015;84:2430-7.
3. Dierick I, Baets J, Irobi J, et al. Relative contribution of mutations in genes for autosomal dominant distal hereditary motor neuropathies: a genotype-phenotype correlation study. *Brain* 2008;131:1217-27.
4. Hayashi T, Su TP. Sigma-1 receptor chaperones at the ER-mitochondrion interface regulate Ca²⁺ signaling and cell survival. *Cell* 2007;131:596-610.
5. Maurice T, Su TP. The pharmacology of sigma-1 receptors. *Pharmacol Ther* 2009;124:195-206.
6. Mavlyutov T, Epstein M, Andersen K, et al. The sigma-1 receptor is enriched in postsynaptic sites of C-terminals in mouse motoneurons: an anatomical and behavioral study. *Neuroscience* 2010;167:247-55.
7. Al-Saif A, Al-Mohanna F, Bohlega S. A mutation in sigma-1 receptor causes juvenile amyotrophic lateral sclerosis. *Ann Neurol* 2011;70:913-9.
8. Bernard-Marissal N, Medard J, Azzedine H, et al. Dysfunction in endoplasmic reticulum-mitochondria crosstalk underlies *SIGMAR1* loss of function mediated motor neuron degeneration. *Brain* 2015;138:875-90.
9. Horga A, Tomaselli P, Gonzalez M, et al. *SIGMAR1* mutation associated with autosomal recessive Silver-like syndrome. *Neurology* 2016;87:1607-12.
10. Brenner D, Yilmaz R, Müller K, et al. Hot-spot *KIF5A* mutations cause familial ALS. *Brain* 2018;141:688-97.

CASE REPORT

Usefulness of the external loop recorder in a patient with Myotonic Dystrophy type 1 and recurrent episodes of palpitations: evaluation of the follow-up from diagnosis to 6 month-post-cardiac interventional treatment

ANNA RAGO, ANDREA ANTONIO PAPA^{1,2}, DARIO GALANTE², ANTONIO CASSESE¹ AND PAOLO GOLINO¹

¹ Department of Cardiology, University of Campania "Luigi Vanvitelli", Naples, Italy - Monaldi Hospital, Naples, Italy;

² Cardiology and Medical Genetics, Department of Experimental Medicine, University of Campania "Luigi Vanvitelli", Naples, Italy; ³ Department of Anesthesia and Intensive Care, University Hospital Ospedali Riuniti, Foggia, Italy

A patient with Myotonic Dystrophy type 1 and recurrent episodes of palpitations is reported, in which the application of an external loop recorder (ELR) was useful for the diagnosis and post radiofrequency ablation follow-up of typical atrial flutter.

Key words: Myotonic Dystrophy, atrial flutter, atrial fibrillation, cavo-tricuspid isthmus radiofrequency ablation, mapping technology, external loop recorder

A 17-year-old male patient affected by Myotonic Dystrophy type 1 (DM1) and recurrent episodes of palpitations was referred to our Division for an arrhythmologic evaluation. He didn't take antiarrhythmic medications. ECG showed sinus rhythm at 65 beats/minute (bpm), atrio-ventricular (PR interval: 120 ms) and intraventricular (QRS duration: 90 ms) conduction within the normal limits, and no ST-T abnormalities (QTc interval: 360 ms). The transthoracic echocardiogram showed a normal ventricular systolic function (Simpson's biplane ejection fraction: 60%) and normal left atrial size. Three conventional 24-hour Holter monitoring, performed during the previous three months, didn't show significant arrhythmias.

Considering the persistence of the symptomatology, a thirty-day high capacity memory external-loop-recorder (ELR, SpiderFlash-T R, Sorin CRM, France) was applied. The recorder was connected to the thorax by lead wires and disposable adhesive electrodes. The patient was trained to

change them daily after taking a bath, as far as to press a button on the recorder to store ECG tracings in case of symptoms. Otherwise, no other manipulation was required. The patient was asked to also annotate on a special diary, the onset of palpitations. After twenty days, the ELR interrogation showed a sustained episode of supraventricular tachycardia at 155 bpm with the common features of typical atrial flutter, in concomitance with the onset of palpitations (Fig. 1).

The patient underwent electrophysiological study (EPS) which confirmed the diagnosis of cavo-tricuspid isthmus (CTI)-dependent atrial flutter (AFI) (Fig. 2). A voltage-directed cavo-tricuspid isthmus ablation was performed using a novel ablation catheter mapping technology (IntellaTip MiFi, Boston Scientific, Natick, MA) in order to only ablate the conducting bundles of the CTI (Fig. 3). In fact, according to previous experiences (1) we avoid to ablate the intervening non-conducting fibrous tissue. The procedure was completed without complications.

At discharge from the hospital, an ELR was applied to the patient for post-ablation ECG monitoring. At six months follow-up, no experienced episodes of palpitations were reported by the patient nor supraventricular arrhythmias were documented at the ELR monitoring.

Discussion

DM1 is the most common muscular dystrophy of the adult life. The cardiac involvement is noticed in about 38-

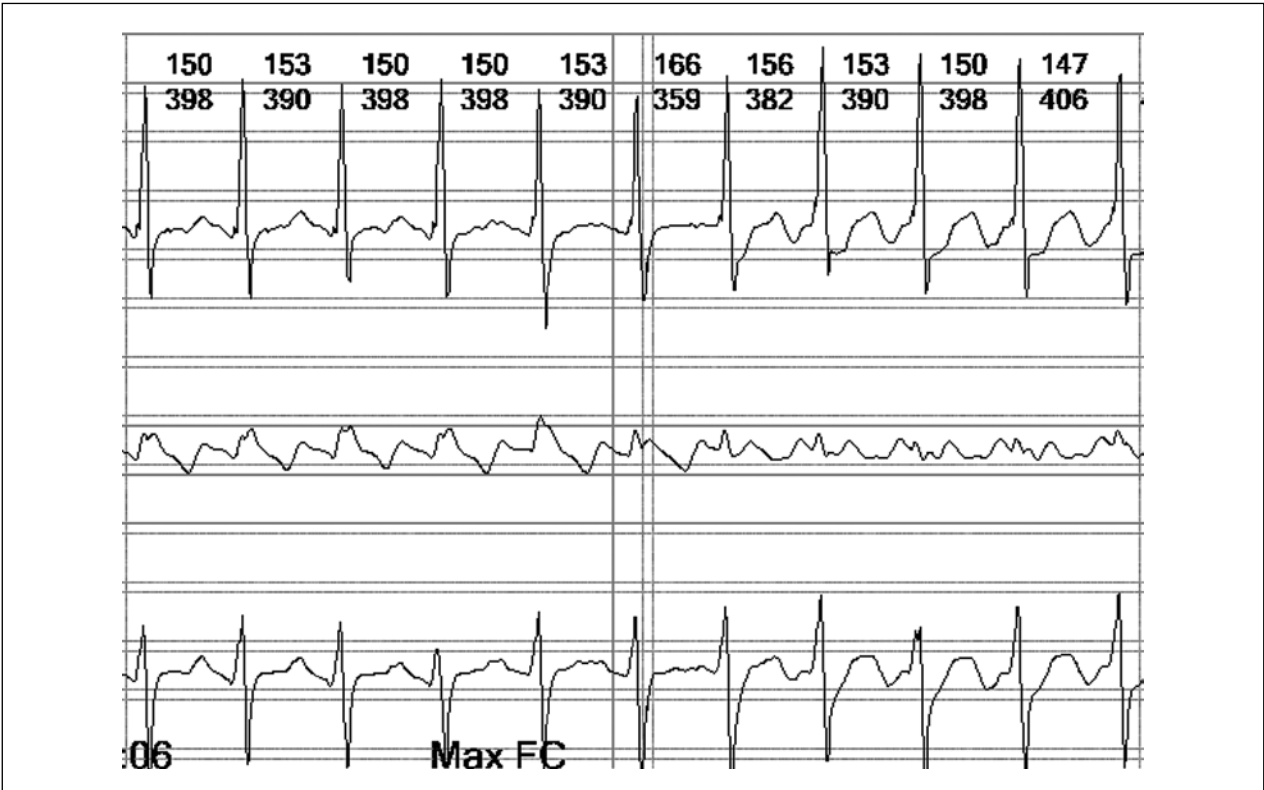


Figure 1. Sustained episode of supraventricular tachycardia compatible with typical atrial flutter diagnosis.

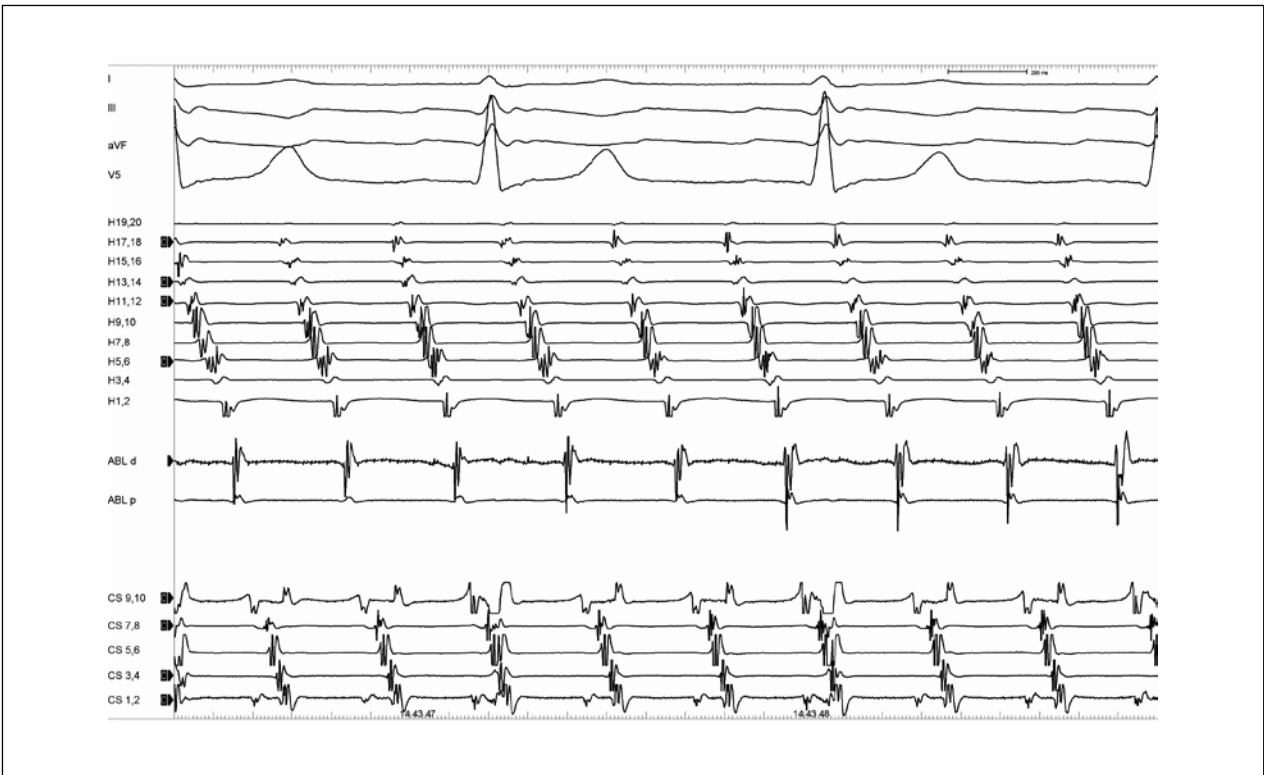


Figure 2. Typical counterclockwise atrial flutter electrograms at electrophysiological study.

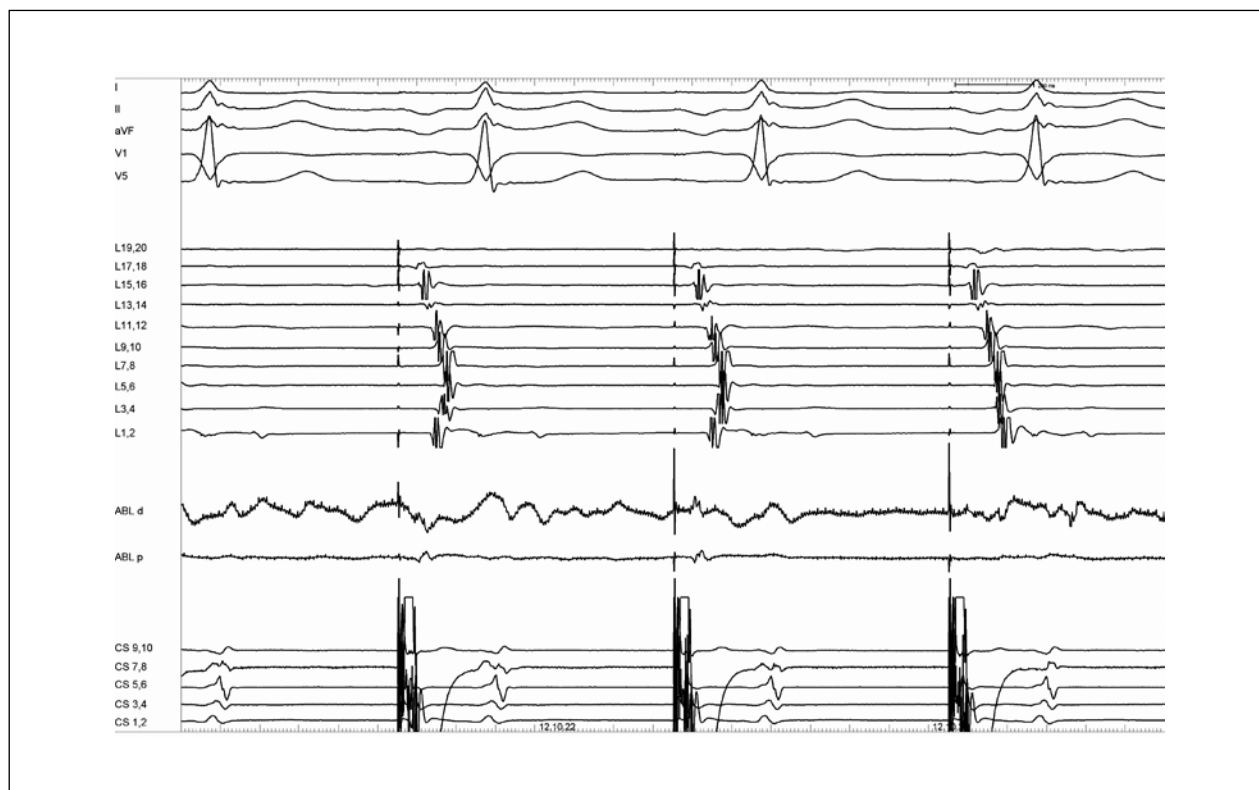


Figure 3. Abrupt change with complete reversal of depolarization sequence on the multipolar mapping catheter during RF energy application.

80% of cases, and it often precedes the skeletal muscle one. It occurs as a degenerative process with progressive fibrosis and fatty replacement not only limited to the specialized conduction system, but also to initially unaffected areas of the atrial myocardium (2). This anatomopathological substrate, causing the discontinuous and inhomogeneous propagation of sinus impulses (3, 4) and the prolongation of atrial conduction time (5, 6), may facilitate the onset and the perpetuation of atrial arrhythmias in these patients (7-15), as in other clinical conditions (16-24). Paroxysmal atrial arrhythmias such as atrial fibrillation, atrial flutter and atrial tachycardia show a prevalence up to 25% in DM1 patients and seem to increase mortality in this population (25).

Considering the arrhythmic risk and its consequences, an early identification of patients with high arrhythmic risk is of pivotal importance for the optimization of the clinical follow-up and medical therapy. For its auto-trigger capability that automatically detects and records predefined and programmable rhythm disturbances such as pauses, bradycardia, or supraventricular/ventricular tachy-arrhythmias, ELR represents a useful tool for early diagnosis of arrhythmic disorders in patients with recurrent palpitations, not diagnosed by conventional 24-h ECG Holter monitoring (26).

The early detecting of supraventricular arrhythmias in DM1 patients consents in turn to earlier evaluate the opportunity of interventional or pharmacologic approach. Furthermore, considering the high prevalence of supraventricular arrhythmias in these patients and the low diagnostic yield of conventional 24-hour Holter monitoring, the early use of ELR in recurrent palpitations might be a feasible and useful strategy, to detect patients with high risk of arrhythmias.

In the case report here described, the use of ELR allowed us to early detect and treat a symptomatic atrial flutter in a young patient with DM1 and to confirm during the follow-up the successful of the radiofrequency ablation procedure.

References

1. Russo V, Rago A, Papa AA, et al. Voltage-directed cavo-tricuspid isthmus ablation using a novel ablation catheter mapping technology in a myotonic dystrophy type I patient. *Acta Myol* 2016;35:109-13.
2. Nigro G, Comi LI, Politano L, et al. Cardiomyopathies associated with muscular dystrophies. In: Engel AG, Franzini-Armstrong C, (eds). *Myology*. 3rd ed. New York: McGraw-Hill; 2004. pp. 1239-56.
3. Russo V, Papa AA, Rago A, et al. Increased heterogeneity of ventricular repolarization in myotonic dystrophy type 1 population. *Acta Myol* 2016;35:100-6.

4. Russo V, Meo F, Rago A, et al. Paroxysmal atrial fibrillation in myotonic dystrophy type 1 patients: P wave duration and dispersion analysis. *Eur Rev Med Pharmacol Sci* 2015;19:1241-8.
5. Russo V, Rago A, Ciardiello C, et al. The role of the atrial electromechanical delay in predicting atrial fibrillation in Myotonic Dystrophy type 1 patients. *J Cardiovasc Electrophysiol* 2016;27:65-72.
6. Russo V, Rago A, Nigro G. Atrial electromechanical delay in Myotonic Dystrophy type 1 patients. *Eur Rev Med Pharmacol Sci* 2015;19:3991-2.
7. Russo V, Rago A, Nigro G. Sudden cardiac death in neuromuscular disorders: time to establish shared protocols for cardiac pacing. *Int J Cardiol* 2016;207:284-5.
8. Russo V, Nigro G, Papa AA, et al. Adenosine-induced sinus tachycardia in a patient with myotonic dystrophy type 1. *Acta Myol* 2014;33:104-6.
9. Russo V, Rago A, Meo F, et al. Ventricular fibrillation induced by coagulating mode bipolar electrocautery during pacemaker implantation in Myotonic Dystrophy type 1 patient. *Acta Myol* 2014;33:149-51.
10. Russo V, Rago A, D'Andrea A, et al. Early onset "electrical" heart failure in myotonic dystrophy type 1 patient: the role of ICD biven-tricular pacing. *Anadolu Kardiyol Derg* 2012;12:517-9.
11. Nigro G, Russo V, Vergara P, et al. Optimal site for atrial lead im-plantation in myotonic dystrophy patients: the role of Bachmann's Bundle stimulation. *PACE* 2008;31:1463-6.
12. Nigro G, Russo V, Politano L, et al. Right atrial appendage versus Bachmann's bundle stimulation: a two year comparative study of electrical parameters in myotonic dystrophy type 1 patients. *PACE* 2009;32:1192-7.
13. Nigro G, Russo V, Rago A. Right atrial preference pacing algo-rithm in the prevention of paroxysmal atrial fibrillation in myotonic dystrophy type 1 patients: a long term follow-up study. *Acta Myol* 2012;31:139-43.
14. Russo V, Nigro G, Rago A. Atrial fibrillation burden in Myotonic Dystrophy type 1 patients implanted with dual chamber pacemaker: the efficacy of the overdrive atrial algorithm at 2 year follow-up. *Acta Myol* 2013;32:142-7.
15. Russo V, Rago A, Papa A, et al. The effect of atrial preference pac-ing on atrial fibrillation electrophysiological substrate in Myotonic Dystrophy type 1 population. *Acta Myol* 2014;33:127-35.
16. Rago A, Russo V, Papa AA, et al. The role of the atrial electrome-chanical delay in predicting atrial fibrillation in beta thalassemia major patients. *J Interv Card Electrophysiol* 2016;48:147-57.
17. Russo V, Di Meo F, Rago A, et al. Impact of continuous positive airway pressure therapy on atrial electromechanical delay in obesi-ty-hypoventilation syndrome patients. *J Cardiovasc Electrophysiol* 2016;27:327-34.
18. Russo V, Rago A, Di Meo F, et al. Atrial septal aneurysms and su-praventricular arrhythmias: the role of atrial electromechanical de-lay. *Echocardiography* 2015;32:1504-14.
19. Russo V, Rago A, Pannone B, et al. Atrial fibrillation and beta thalassemia major: the predictive role of the 12-lead electrocardio-gram analysis. *Indian Pacing Electrophysiol J* 2014;25:121-32.
20. Russo V, Rago A, Palladino A, et al. P-wave duration and disper-sion in patients with Emery-Dreifuss muscular dystrophy. *J Investig Med* 2011;59:1151-4.
21. Russo V, Rago A, Pannone B, et al. Early electrocardiographic eval-uation of atrial fibrillation risk in beta-thalassemia major patients. *Int J Hematol* 2011;93:446-51.
22. Russo V, Rago A, Papa A, et al. Cardiac resynchronization im-proves heart failure in one patient with Myotonic Dystrophy type 1. A case report. *Acta Myol* 2012;31:154-5.
23. Russo V, Rago A, D'Andrea A, et al. Early onset "electrical" heart failure in Myotonic Dystrophy type 1 patient: the role of ICD bi-ventricular pacing. *Anadolu Kardiyol Derg* 2012;12:517-9.
24. Russo V, Nigro G., Papa AA. Far field R-wave sensing in Myotonic Dystrophy type 1: right atrial appendage versus Bachmann's bundle region lead placement. *Acta Myol* 2014;33:94-9.
25. Brembilla-Perrot B, Schwartz J, Huttin O, et al. Atrial flutter or fi-brillation is the most frequent and life-threatening arrhythmia in myotonic dystrophy. *Pacing Clin Electrophysiol* 2014;37:329-35.
26. Locati ET, Vecchi AM, Vargiu S, et al. Role of extended external loop recorders for the diagnosis of unexplained syncope, pre-syn-cope, and sustained palpitations. *Europace* 2014;16:914-22.

**PROCEEDINGS OF THE XVIII CONGRESS
OF THE ITALIAN ASSOCIATION OF MYOLOGY**

Genoa, Italy

June 6-9, 2018



XVIII Congresso Nazionale

AIM

Associazione Italiana di Miologia

JOINT SESSION

Associazione Italiana di Miologia
Société Française de Myologie

From Basic Muscle Science
to Translational Myology

GENOVA

6 - 9 Giugno 2018

Magazzini del Cotone

Con il patrocinio di:

Sin
SOCIETÀ ITALIANA DI NEUROLOGIA

 Società
Italiana di
Pediatria

SINP
Società Italiana
di Neurologia Pediatrica



XVIII CONGRESSO NAZIONALE

AIM Associazione Italiana di Miologia



Consiglio Direttivo

Associazione Italiana di Miologia

Gabriele Siciliano (Pisa), Presidente

Maurizio Moggio (Milano), Past-President

Massimiliano Filosto (Brescia), Segretario

Carmelo Rodolico (Messina), Tesoriere

Consiglieri

Giovanni Antonini (Roma)

Antonio Di Muzio (Chieti)

Chiara Fiorillo (Genova)

Marina Mora (Milano)

Elena Pegoraro (Padova)

Stefano Previtali (Milano)

Presidente del Comitato Organizzatore

Carlo Minetti

Comitato Organizzatore:

Paolo Broda

Claudio Bruno

Cristina Diana

Chiara Fiorillo

Chiara Panicucci

Marina Pedemonte

XVIII CONGRESSO NAZIONALE

AIM Associazione Italiana di Miologia



FACULTY

Anna Ambrosini (Milano)	Graziella Messina (Milano)
Toni Andreu (Amsterdam, NL)	Margherita Milone (Rochester, USA)
Corrado Angelini (Padova)	Carlo Minetti (Genova)
Giovanni Antonini (Roma)	Maurizio Moggio (Milano)
Sigrid Baldanzi (Pisa)	Tiziana Mongini (Torino)
Guillaume Bassez (Paris, FR)	Marina Mora (Milano)
Angela Berardinelli (Pavia)	Isabella Moroni (Milano)
Enrico Bertini (Roma)	Antonio Musarò (Roma)
Simona Bertoli (Milano)	Vincenzo Nigro (Napoli)
Gisèle Bonne (Paris, FR)	Marica Pane (Roma)
Claudio Bruno (Genova)	Marina Pedemonte (Genova)
Jeffrey S. Chamberlain (Seattle, USA)	Elena Pegoraro (Padova)
Catherine Coirault (Paris, FR)	Lorenzo Peverelli (Milano)
Giacomo P. Comi (Milano)	Paolo Petralia (Genova)
Stefania Corti (Milano)	Antonella Pini (Bologna)
Adele D'Amico (Roma)	Luisa Politano (Napoli)
Jean François Desaphy (Bari)	Stefano Previtali (Milano)
Salvatore DiMauro (New York, USA)	Angelo Ravelli (Genova)
Antonio Di Muzio (Chieti)	Giulia Ricci (Pisa)
Teresinha Evangelista (Newcastle, UK)	Carmelo Rodolico (Messina)
Alessandra Ferlini (Ferrara)	Marco Sandri (Padova)
Massimiliano Filosto (Brescia)	Valeria Sansone (Milano)
Chiara Fiorillo (Genova)	Filippo Maria Santorelli (Pisa)
Francesco Francini (Padova)	Angelo Schenone (Genova)
Elisabetta Gazzero (Berlino, DE)	Monica Sciacco (Milano)
Michio Hirano (New York, USA)	Serenella Servidei (Roma)
Giovanni Iolascon (Napoli)	Gabriele Siciliano (Pisa)
Pascal Laforêt (Garches, FR)	Francesco Saverio Tedesco (London, UK)
Costanza Lamperti (Milano)	Paola Tonin (Verona)
Giovanna Lattanzi (Bologna)	Antonio Toscano (Messina)
Alberto Malerba (London, UK)	Rossella Tupler (Modena)
Michelangelo Mancuso (Pisa)	Giuseppe Vita (Messina)
Roberto Massa (Roma)	Federico Zara (Genova)
Gianni Meola (Milano)	Massimo Zeviani (Cambridge, UK)
Eugenio Mercuri (Roma)	

Program

MERCOLEDÌ 6 GIUGNO



13.00 | Registrations

14.00 | Congress Welcome *(President of AIM, President of SIN, Authorities)*

14.30 | WORKSHOP 1 "Basic Muscle Science"

Chairpersons: Claudio Bruno, Massimo Zeviani

- The Transcription Factor Nfix in muscle development and muscular dystrophies.
Graziella Messina (Milano)

- The pathogenetic mechanisms of muscular dystrophy
Antonio Musarò (Roma)

- Muscle contraction and metabolic adaptation: molecular mechanisms
Marco Sandri (Padova)

- Three-dimensional Human iPS Cell-derived Artificial Skeletal Muscles for Disease Modelling and Tissue Engineering
Francesco Saverio Tedesco (London, UK)

16.00 | LECTURE 1 a tribute to Professor Giovanni Nigro

Introduction: Corrado Angelini

- Contribution of the Naples School to the knowledge of myocardial involvement in Neuromuscular Diseases
Luisa Politano (Napoli)

16.30 | AIM NETWORKS

Introduction and on going Networks:
Gabriele Siciliano (Pisa)

FSHD *(Rossella Tupler, Modena)*

Mitochondrial Myopathies *(Michelangelo Mancuso, Pisa)*

Limb Girdle Muscular Dystrophies *(Giacomo Comi, Milano)*

Muscle Glycogenosis *(Antonio Toscano, Messina)*

Laminopathies *(Giovanna Lattanzi, Bologna)*

Proposed future Networks:
Maurizio Moggio (Milano)

Muscle Channelopathies *(Valeria Sansone, Milano)*

Congenital Muscular Dystrophies *(Adele D'amico, Roma)*

Congenital Myopathies *(Claudio Bruno, Genova)*

Lipid Myopathies *(Elena Maria Pennisi, Roma)*

Myofibrillar Miopathies *(Lorenzo Maggi, Milano)*

MERCOLEDÌ 6 GIUGNO



Connective tissue muscle disorders (*Angela Berardinelli, Pavia*)
 Myasthenic Syndromes (*Carmelo Rodolico, Messina*)
 Distal Myopathies (*Giorgio Tasca, Roma*)
 Inflammatory Myopathies (*Massimiliano Mirabella, Roma*)

17.30 | The ERN-NMD. Work in progress 2017-2018.
Teresinba Evangelista (Newcastle, UK)

18.00 | SYMPOSIUM 1: New perspectives on early diagnosis in DMD
Moderator: Angela Berardinelli

- How to accelerate early diagnosis | *Alessandra Ferlini (Ferrara)*
- Territorial network to support DMD patients | *Tiziana Mongini (Torino)*
- Therapeutical approach to nonsense mutations | *Adele D'Amico (Roma)*

19.30 | WELCOME COCKTAIL

GIOVEDÌ 7 GIUGNO

7.30 | Breakfast Seminar 1: Nutrition in NMD
Moderator: Antonio Di Muzio

- Nutrition in the healthy population | *Francesco Francini (Padova)*
- From evidence to dietary recommendations in NMD | *Antonella Pini (Bologna)*
- Body composition and energy expenditure in SMA patients | *Simona Bertoli (Milano)*

8.30 | Oral Presentations 1: Congenital Myopathies
Chairpersons: Roberto Massa, Marina Mora

Role of muscle biopsy study in the diagnosis of floppy infants
*C. Fiorillo, F. Dazzi, P. Broda, C. Romano, S. Savasta, R. Falsaperla, A. Donati,
 M. Pedemonte, E. Gazzerri, C. Bruno, C. Minetti
 (Genova; Catania; Pavia; Firenze; Berlino, DE)*

Redefining morphological spectrum of RYR1 recessive myopathies
*M. Garibaldi, J. Rendu, J. Brocard, E. Lacene, G. Brochier, M. Beuvin, Labasse,
 F. Levy-Borsato, A. Madelaine, E. Malfatti, J. Bevilacqua, F. Lubieniecki, S. Monges,
 AL. Taratuto, I. Marty, G. Antonini, NB Romero
 (Paris, FR; Roma ; Grenoble, FR ; Santiago, Chile; Buenos Aires, Argentina)*

Genova 6 - 9 Giugno 2018 | Magazzini del Cotone



**Novel phenotypes of congenital myopathies:
importance of the ultrastructural electron microscopy study**

*E. Malfatti, J. Bobm, X. Lornage, V. Chartner, G. Brochier, A. Madelaine,
C. Labasse, M. Fardeau, J. Laporte, N. B Romero
(Parigi, FR; Illkirch, FR; Garches, FR)*

**WES analysis identified MSTO1 as novel disease gene in two families
with 3 patients presenting a complex phenotype characterized by congenital
myopathy and ataxia**

*M. Neri, A. Nasca, C. Scotton, I. Zabarieva, R. Selvatici, O. Thor Magnusson, A. Gal,
G. Kiriko, D. Weaver, R. Rossi, A. Armaroli, M. Pane, A. Cecconi, C. Sewry,
R. Phadke Lucy Feng, A. Donati, E. Mercuri, M. Zeviani, F. Muntoni, D. Ghezzi, A. Ferlini
(Ferrara; Milano; London, UK; Iceland; Philadelphia, USA; Roma; Firenze; Cambridge, UK)*

**Clinical characterization of an Italian cohort of patients with early-onset
LMNA-related myopathy**

*G. Ricci, C. Fiorillo, A. D'Amico, G. Astrea, C. Rodolico, L. Vercelli, T. Mongini,
C. Semplicini, E. Pegoraro, L. Politano, E. Mercuri, S. Benedetti, A. Berardinelli,
S. Previtali, N. Carboni, G. Marrosu, E. Bertini, G. Siciliano, G. Lattanzi,
L. Maggi, Italian Network for Laminopathies
(Pisa; Genova; Messina; Torino; Padova; Napoli; Roma; Milano; Pavia; Nuoro; Cagliari;
Bologna)*

9.30 | WORKSHOP 2 "The floppy infant: diagnosis and management"

Chairpersons: Enrico Bertini, Carlo Minetti

- Differential diagnosis | *Eugenio Mercuri (Roma)*
- Invasive supportive measures: when? | *Marina Pedemonte (Genova)*
- Early onset peripheral neuropathies: the dark side of the moon | *Isabella Moroni (Milano)*
- Myasthenic syndrome and channelopathies | *Carmelo Rodolico (Messina)*

11.00 | Coffee break

11.20 | MITO - LECTURES 2:

Introduction: Salvatore DiMauro

- A New approach to the Treatment of Mitochondrial Disorders
Michio Hirano (New York, USA)
- Rapamycin rescues a mitochondrial myopathy model
Massimo Zeviani (Cambridge, UK)

GIOVEDÌ 7 GIUGNO



12.20 | SYMPOSIUM 2:

The clinical landscape for SMA in a new therapeutic era

Moderators: Claudio Bruno, Eugenio Mercuri

- SMA natural history changes in light of new clinical data

Marica Pane (Roma)

- SMA adult patients: first experiences

Giacomo P. Comi (Milano)

- Discussant:

Eugenio Mercuri (Roma)

Claudio Bruno (Genova)

13.20 | Lunch

14.20 | ROUND TABLE:

Role of rehabilitation in Pompe disease

Giovanni Iolascon (Napoli), Tiziana Mongini (Torino), Gabriele Siciliano (Pisa),

Antonio Toscano (Messina)

15.00 | Aig Kit: digital approach in doctor-patient relationship in Pompe disease

Sigrid Baldanzi (Pisa) e Giulia Ricci (Pisa)

15.20 | POSTER SESSION - 1

P-1-1 BASIC SCIENCE

Chairpersons: Luca Bello, Chiara Fiorillo

P-1-2 CHANNELOPATHIES AND MYOTONIC DISORDERS

Chairpersons: Carmelo Rodolico, Liliana Vercelli

P-1-3 DMD and BMD

Chairpersons: Luca Doglio, Federica Ricci

P-1-4 FSHD/ Inflammatory Myopathies

Chairpersons: Rita Barresi, Lucia Ruggiero

P-1-5 LGMD

Chairpersons: Francesca Magri, Gianluca Vita

Genova 6 - 9 Giugno 2018 | Magazzini del Cotone



16.20 | Oral Presentations 2: Metabolic Myopathies

Chairpersons: Maria Alice Donati, Serenella Servidei

Lectin staining of skin biopsy is a convenient and sensitive tool to diagnose GNE myopathy

*R. Barresi, Y. Parkhurst, O. Pogoryelova, G. Eglon, R. Wake, V. Straub
(Newcastle upon Tyne, UK)*

Myotonic dystrophy in Abruzzo

*A. Di Muzio, R. Telese, R. Carlino, F. Barbone, M. Vitale, E. Rastelli, F. Lozzi, R. Massa
(Chieti; Roma)*

Vacuolar lipid storage myopathies responsive to Riboflavin

*A. Lupica, O. Musumeci, C. Rodolico, T. Brizzi, A. Ciranni, R. Arrigo, S. Volta, G. Vita,
A. Toscano (Messina)*

Dietary treatment for McArdle's disease: real promise or illusion?

The rationale for a multicenter RCT.

*A. Martinuzzi, M. Vavla, C. Stefan, E. Trevisi, G. Siciliano, G. Ricci, A. Toscano,
O. Musumeci (Polo Regionale Veneto; Pisa; Messina)*

Ultrasound for assessment of diaphragm function in late-onset Pompe disease

*O. Musumeci, P. Ruggeri, L. Lo Monaco, M. Gaeta, R. Arrigo, S. G. Caramori, A. Toscano
(Messina)*

17.20 | Oral Presentations 3: Therapies 1

Chairpersons: Giacomo Comi, Rocco Liguori

A retrospective study of respiratory function in the Italian Duchenne muscular dystrophy Network

*L. Bello, M. Villa, S. Gandossini, G. D'Angelo, F. Magri, G. P. Comi, M. Pedemonte,
P. Tacchetti, V. Lanzillotta, C. Bruno, A. D'Amico, E. Bertini, G. Astrea, L. Politano,
G. Baranello, E. Albamonte, E. De Mattia, F. Rao, V. Sansone, S. Previtali, S. Messina,
G. L. Vita, A. Berardinelli, T. Mongini, M. Pane, E. Mercuri, A. Vianello, E. Pegoraro
(Padova; Bosisio Parini; Milano; Genova; Roma; Napoli; Messina; Pavia; Torino)*

Pulmonary Function in Patients With Advanced Duchenne Muscular Dystrophy: Eteplirsen-Treated Patients Compared With Multiple Natural History Cohorts

*H. Gordish-Dressman, E. Henricson, N. Khan, L. Han, A. Dugar, C. M. McDonald;
CINRG DNHS Investigators (Washington, DC, USA; Cambridge, MA, USA)*

Rituximab for immunosuppressant resistant inflammatory myopathies: a single center case series and literature review

*M. Lucchini, C. De Fino, M. Monforte, GA Primiano, E. Ricci, S. Servidei, M. Mirabella
(Roma)*

GIOVEDÌ 7 GIUGNO



The Becker Muscular Dystrophy cohort in the Givinostat trial: clinical characterization and functional measures

F. Magri, D. Velardo, A. Govoni, C. Cinnante, L. Peverelli, S. Cazzaniga, L. Bello, R. Brusa, C. Semplicini, M. G. D'Angelo, S. Gandossini, M. Filosto, V. Sansone, S. Previtali, E. Pegoraro, S. Corti, M. Moggio, N. Bresolin, P. Bettica, G. P. Comi (Milano; Padova; Bosisio Parini; Brescia)

Golodirsén Induces Exon Skipping Leading to Sarcolemmal Dystrophin Expression in Patients With Genetic Mutations Amenable to Exon 53 Skipping

E. Mercuri, D. E. Frank, L. Servais, V. Straub, J. Morgan, J. Domingos, F. Schnell, G. Dickson, L. Popplewell, A. Seferian, M. Monforte, M. Guglieri, F. Muntoni, the SKIP-NMD Study Group (Roma; Cambridge, MA, USA; Paris, FR; Newcastle, UK; London, UK)

VENERDÌ 8 GIUGNO

7.30 | Breakfast Seminar 2:

New Perspectives in Molecular genetic technologies

Moderator: Rossella Tupler

- New applied technologies in genomic field | *Vincenzo Nigro (Napoli)*
- Application of NGS techniques in neuromuscular disorders | *Filippo M. Santorelli (Pisa)*
- Opportunities and risks of genomic analysis in clinical practice | *Federico Zara (Genova)*

8.30 | Oral Presentations 4: Basic Science

Chairpersons: Annalisa Botta, Vincenzo Nigro

Proteomic analyses of FSHD muscular dystrophy by a combination of 2D-DIGE and MALDI ToF/ToF, ICPL and Label free LC-MS/MS.

D. Capitanio, E. Torretta, M. Moriggi, C. Fiorillo, L. Ruggiero, J. Baldacci, L. Santoro, FM Santorelli, C. Gelfi (Milano; Pisa; Napoli)

TNPO3 and myogenesis in murine and human myoblasts

R. Costa, M.T. Rodia, V. Papa, V. Pegoraro, L. Giaretta, R. Marozzo, C. Angelini, G. Cenacchi (Bologna; Venezia)

RNAseq in urine-derived stem cells identified the expression of more than 300 neuromuscular gene transcripts

M.S. Falzarano, H. Osman, R. Rossi, R. Selvatici, M. Neri, F. Gualandi, M. Fang, Z. Lu, A. Grilli, S. Biciato, A. Ferlini (Ferrara; Khartoum, Sudan; Shenzhen, China; Modena e Reggio Emilia; Londra, UK)

Genova 6 - 9 Giugno 2018 | Magazzini del Cotone



Autophagy marker LC3 accumulates in immune-mediated necrotizing myopathy muscle fibres

F. Girolamo, A. Lia, M. Giannini, A. Amati, D. D'Abbicco, M. Tampoia, L. Serlenga, F. Iannone, M. Trojano (Bari)

Zidovudine ameliorates pathology in the mouse model of Duchenne Muscular Dystrophy via the P2RX7 purinoceptor antagonism

C. Panicucci, R. Al-Khalidi, P. Cox, N. Chira, J. Róg, C. N. J. Young, R. E. McGeehan, K. Ambati, J. Ambati, K. Zablocki, E. Gazzero, S. Arkle, C. Bruno, D. C. Górecki (Portsmouth, UK; Genova; Warsaw, Poland; Charlottesville, VA, USA; Berlin, Germany)

9.30 | WORKSHOP 3

“Experimental therapies in Neuromuscular Disorders”

Chairpersons: Elena Pegoraro, Stefano Previtali

- SMA: from models to mechanisms to therapy
Stefania Corti (Milano)
- Precision medicine in non-dystrophic myotonia
Jean Francoise Desaphy (Bari)
- Immunity in Muscular Dystrophies: Friend or Enemy?
Elisabetta Gazzero (Berlin)
- Gene therapy for oculopharyngeal muscular dystrophy
Alberto Malerba (London)

11.00 | Coffee break

11.20 | LECTURE 3:

Introduction: Vincenzo Nigro

- Muscle-specific CRISPR/Cas9 dystrophin gene editing
Jeffrey S. Chamberlain (Seattle, USA)

12.00 | Oral Presentations 5: Therapies 2

Chairpersons: Sonia Messina, Paola Tonin

Nutritional status in SMA type 1 over a 6 month follow-up in Nusinersen Expanded Access Program (EAP)

S. Messina, M. Sframeli, C. Bruno, M. Pane, V. Sansone, M. Catteruccia, C. Stancanelli, E. Albamonte, M. Pedemonte, A. D'Amico, E. Bertini, E. Mercuri, G. Vita on behalf of the Italian EAP working group (Messina; Genova; Roma; Milano)

VENERDÌ 8 GIUGNO



Development of Golodirsen by the SKIP-NMD Consortium and Design of a Phase 1/2 Trial of Golodirsen for the Treatment of DMD Amenable to Exon 53 Skipping

M. Monforte, D. E. Frank, E. Mercuri, L. Servais, V. Straub, J. Morgan, J. Domingos, F. Schnell, G. Dickson, L. Popplewell, A. Seferian, M. Gugliri, F. Muntoni, the SKIP-NMD Study Group (Cambridge, MA, USA; Newcastle upon Tyne, UK; London, UK)

Effect of serum deprivation and WY14643 treatment on NLSDM fibroblasts.

E.M Pennisi, S. Missaglia, F. Gragnani, M. Garibaldi, C. Angelini, M. Mora, D. Tavian (Milano; Venezia; Roma)

Sport and Neuromuscular disease: psychosocial impact and physical benefits on a cohort of patients

C. Stancanelli, S. La Foresta, G.L. Vita, C. Faraone, G. Laganà, G. Vita (Messina)

RG7916 distributes and increases SMN protein levels in both the central nervous system and peripheral organs

A. Poirier, M. Weetall, H. Ratni, K. Heinig, N. Naryshkin, S. Pausbkin, L. Mueller (Basel, Switzerland; South Plainfield, NJ, USA; New York, NY, USA)

13.00 | Lunch

14.00 | POSTER SESSION 2

P2-1- Metabolic Myopathies

Chairpersons: Matteo Garibaldi, Claudio Semplicini

P2-2- Myastenic Syndromes

Chairpersons: Rosanna Cardani, Marina Grandis

P2-3- Congenital Myopathies

Chairpersons: Guya Astrea, Marina Pedemonte

P2-4- Miscellanea

Chairpersons: Michela Catteruccia, Daniele Orsucci

P2-5- Mitochondrial Myopathies

Chairpersons: Costanza Lamperti, Olimpia Musumeci

P2-6- SMA

Chairpersons: Giovanni Baranello, Federica Trucco

15.30 | JOINT SESSION

Associazione Italiana di Miologia (AIM)

Société Française de Myologie (SFM)

Chairpersons: Gisèle Bonne, Gabriele Siciliano

Genova 6 - 9 Giugno 2018 | Magazzini del Cotone



Myotonic Dystrophy:

- Translational research in myotonic dystrophy: recent advances and future challenges
Guillaume Bassez (Paris)
- Taking charge of myotonic dystrophy patients: from clinical practice to research
Valeria Sansone (Milano)

Pompe disease:

- The French Pompe registry: molecular features of non-classical Pompe disease and study of benefit of long term ERT in adults
Pascal Laforêt (Garches)
- The Italian Registry for Muscle Glycogen: facts and perspectives
Antonio Toscano (Messina)

Laminopathies:

- Mechanobiology defects in LMNA-related congenital muscular dystrophy
Catherine Coirault (Paris)
- Tendon contractures in Emery-Dreifuss Muscular Dystrophy: a major involvement of TGF beta 2
Giovanna Lattanzi (Bologna)

17.30 | Oral Presentations 6: Dystrophies

Chairpersons Lorenzo Maggi, Andrea Martinuzzi

**Profiling brain functioning in Muscular Dystrophies (MD):
upgrading knowledge from on-going research**

*S. Baldanzi, G. Ricci, C. Simoncini, P. Cecchi, M. Cosottini, C. Angelini, G. Siciliano
(Pisa; Venezia)*

**Autosomal recessive Bethlem myopathy:
a clinical, genetic and functional study**

*F. Caria, M. Cescon, F. Gualandi, R. Rossi, P. Rimessi, S. Cotti Piccinelli, M. Marchesi,
S. Gallo Cassarino, I. Gregorio, A. Ferlini, A. Padovani, P. Bonaldo, M. Filosto
(Brescia; Padova; Ferrara)*

**Use of muscle MRI to follow up patients with inflammatory
idiopathic myopathies (IIM)**

*M. Colombo, D. Velardo, A. Ambrosi, M. Scarlato, G. A. Ramirez, V. Canti, R. De Lorenzo,
M. Cava1, R. Fazio, F. De Cobelli, P. Rovere Querini, S. C. Previtali
(Milano)*

VENERDÌ 8 GIUGNO



The JAIN Clinical Outcome Study in Dysferlinopathy

Cl. Semplicini, F. Smith, J. Marni, A. G. Maybew, R. Fernandez-Torron, S. Spuler, J.W. Day, K. J. Jones, D. X. Bharucha-Goebel, E. Salort-Campana, A. Pestronk, M. C. Walter, C. Paradas, T. Stojkovic, M. Mori-Yoshimura, E. Bravver, J. Díaz-Manera, L. Bello, E. Pegoraro, J. R. Mendell, K. Bushby, V. Straub, The Jain COS Consortium (Padova; Newcastle upon Tyne, UK; Washington, DC, USA; Donostia-San Sebastian, Spain; Berlin, Germany; Stanford, CA, USA; Sydney, Australia; Washington, DC, USA; Bethesda, MD, USA; Marseille, France; St. Louis, MO, USA; Munich, Germany; Sevilla, Spain; Paris, France; Tokyo, Japan; Charlotte, NC, USA; Barcelona, Spain; Barcelona, Spain; Columbus, Ohio USA)

QUANTITATIVE MUSCLE ULTRASOUND ANALYSIS IN FSHD PATIENTS

F. Vanoli, A. Di Pasquale, G. Fragiotta, L. Fionda, L. Leonardi, M. Garibaldi, E. Bucci, S. Morino, A. Grossi, R. Tupler, G. Antonini (Roma; Modena e Reggio Emilia)

18.30 | Assemblea Generale Soci AIM

CENA SOCIALE

SABATO 9 GIUGNO

8.30 | MUSCLE CLUB

Chairpersons: Costanza Lamperti, Monica Sciacco

Clinical presentation of a congenital myopathies LGMD D2 new phenotype in an Hungarian family

C. Angelini, R. Marozzo, V. Pegoraro (Venezia)

Unusual symptoms and pathology in a woman with myofibrillar myopathy

S. Bortolani, L. Vercelli, L. Chiadò-Piat, S. Boschi, T. Mongini (Torino)

Exercise intolerance and myoglobinuria as presenting symptom of alpha-sarcoglycanopathy

M. Catteruccia, G. Primiano, F. Fattori, E. Bertini, S. Servidei, Adele D'Amico (Roma)

Core and rod myopathy due to a novel mutation in BTB domain of KBTBD13 gene presenting as LGMD

M. Garibaldi, F.F. Fattori, C. Bortolotti, G. Brochier, C. Labasse, M. Verardo, E.M. Pennisi, A. Di Pasquale, E. Torchia, E. Bucci, S. Morino, E.S Bertini, C. Paradas, N.B Romero, G. Antonini (Roma; Modena e Reggio Emilia; Parigi, FR; Siviglia, ES)

Genova 6 - 9 Giugno 2018 | Magazzini del Cotone



Late-onset axial myopathy (Bent spine syndrome): a case report

V. Montano, G. Ricci, F. Baldinotti, G. Ali, L. Chico, L. Cali Cassi, A. Barison, R. Costa, G. Cenacchi, M.A. Caligo, G. Siciliano (Pisa; Bologna)

Filamin-C myopathy associated to brain and spinal cord abnormalities: expanding the clinical phenotype

S.C. Previtali, M. Scarlato, P. Vezzulli, A. Ruggieri, D. Velardo, S. Benedetti, B. Colombo, L. Maggi, G. D'Angelo, M. Mora (Milano; Lecco)

9.30 | WORKSHOP 4 "Idiopathic Inflammatory Myopathies"

Chairpersons: Giovanni Antonini, Gianni Meola

- New classification | *Margherita Milone (Rochester, USA)*
- Infantile dermatomyositis | *Angelo Ravelli (Genova)*
- Adult Polymyositis | *Massimiliano Filosto (Brescia)*
- Necrotizing Autoimmune Myositis | *Lorenzo Peverelli (Milano)*

11.00 | Coffee break

11.20 | ROUND TABLE:

**Translational Medicine and social-sanitary aspects
in Neuromuscular Disorders**

Moderators: Anna Ambrosini (Telethon), Carlo Minetti

participants:

CAMN, Alleanza Neuromuscolare, UILDM, Famiglie SMA, Parent Project, ASAMSI, Mitocon, Associazioni Medici e Pediatri di Famiglia

Invited Talk

Introduction: Paolo Petralia

- Translational Medicine and Neuromuscular Disorders

Toni Andreu (Scientific Director European Infrastructure for Translational Medicine, EATRIS, Amsterdam, NED)

- Discussants: *Angelo Schenone, Giuseppe Vita*

13.20 | Platform presentation of the best 3 Posters

13.30 | Closing remarks

FOCACCIA FAREWELL LUNCH

Poster Section



POSTER SECTION 1- June 7th- h. 15.20-16.20

P-1-1 Basic Science

Chairpersons: Luca Bello, Chiara Fiorillo

P.1 Generation of induced pluripotent stem cells (hiPSCs) as cellular model to study the central nervous system pathogenesis of Myotonic Dystrophy type 2 (DM2)

P. Spitalieri, V. Talarico, M. Murdocca, L. Fontana, E. Campione, R. Massa, G. Meola, G. Novelli, F. Sangiuolo, A. Botta (Roma)

P.2 Cardiac troponin T fetal isoform expression as a possible biomarker of cardiac dysfunctions in DM1 skeletal muscle

B. Fossati, F. Bose', L.V. Renna, N. Ferrari, V. Labate, M. Cavalli, G. Meola, R. Cardani (Milano)

P.3 Dysregulation of myomiRNA in Becker and facioscapulohumeral muscular dystrophy

R. Marozzo, V. Pegoraro, C. Angelini (Venezia)

P.4 Down regulation of myomirnas and myostatin in DM1 after physical rehabilitation

V. Pegoraro, L. Giaretta, P. Cudia, A. Baba, C. Angelini (Venezia)

P.5 AGC-1 deficiency, a rare genetic demyelinating and neurodegenerative disease: from cell lines and a mouse model to human iPS-derived brain cells.

L. Pena, S. Petralla, M. Bentivogli, E. Poeta, L. Sbano, A. Danese, M. Corricelli, C. Giorgi, P. Pinton, F. M. Lasorsa, B. Monti (Bologna; Ferrara; Bari)

P.6 New biomarkers in amyotrophic lateral sclerosis: analysis of the biophysical properties and gene expression in skeletal muscle of a transgenic mouse model.

G.M. Camerino, A. Fonzino, E. Conte, A. Liantonio, M. De Bellis, G. Dobrowolny, A. Musarò, A. De Luca, S. Pierno (Bari; Roma)

P.7 An RNA-Seq-based picture of splicing pattern in adult human skeletal muscle

M. Savarese, P.H. Jonson, S. Huovinen, L. Paulin, P. Auvinen, B. Udd, P. Hackman (Helsinki, Finland; Tampere, Finland; Vaasa, Finland)

P-1-2- Channelopathies and Myotonic Disorders

Chairpersons: Carmelo Rodolico, Liliana Vercelli

P.8 Potassium-aggravated myotonia: a rare disease successfully managed by dietary restriction.

F. Barbone, M. Vitale, R. Telese, C. Ferrante, V. Di Stefano, A. Di Muzio (Chieti)

Poster Section



P.9 How respiratory muscle strength correlates with cough capacity in patients with Myotonic Dystrophy.

E. De Mattia, A. Pirola, A. Lizio, E. Mollar, E. Roma, E. Falcier, F. Rao, V. Sansone (Milano)

P.10 Dampening of skeletal muscle excitability by carbonic anhydrase inhibitors through enhancement of chloride conductance.

S. Pierno, A. Fonzino, C. Altamura, P. Imbrici, A. Liantonio, M.R. Carratù, D. Conte, J.F. Desaphy (Bari)

P.11 Pharmacological studies of Nav1.4 channel mutants to define precision medicine in sodium channel myotonia and paramyotonia congenita.

A. Farinato, C. Altamura, P. Imbrici, L. Maggi, P. Bernasconi, R. Mantegazza, M. Filosto, G. Siciliano, V.A. Sansone, M. Lo Monaco, C. Vial, D. Sternberg, M.R. Carratù, D. Conte Camerino, J-F. Desaphy (Bari; Milano; Brescia; Pisa; Roma; Lyon Bron, FR; Parigi, FR)

P.12 Atypical cardiac involvement in Congenital Myotonic Muscular Dystrophy: a case report.

G. Ferrantini, B. Berti, G. De Rosa, R. De Sanctis, N. Forcina, S. Carnicella, E. Mercuri, M. Pane (Roma)

P.13 Genotype-phenotype relationship in myotonia congenital caused by CLCN1 mutations: what we have done and future therapeutic challenges for precision medicine

P. Imbrici, C. Altamura, D. Sabbani, G.M. Camerino, E. Conte, S. Pierno, L. Maggi, M. Lo Monaco, G. Meola, S. Lucchiari, S. Pagliarani, G. Ulzi, P. Bernasconi, R. Brugnioni, G. Comi, R. Mantegazza, A. D'Amico, E. Pegoraro, L. Politano, T. Mongini, L. Vercelli, G. Siciliano, G. Ricci, A. Toscano, V. Sansone, J.F. Desaphy, D. Conte (Bari; Milano; Roma; Padova; Napoli; Torino; Pisa; Messina)

P.14 Evaluation of multifrequency bioimpedance analysis (BIA) as a potential out-come measure for muscle involvement in myotonic dystrophy type 1 (DM1): a small pilot study.

A. Perna, E. Rinninella, M. Cintoni, M. Ricci, T.F. Nicoletti, S. Rossi, G. Miggiano, A. Gasbarrini, M.C. Mele, G. Silvestri. (Roma)

P.15 Effects of defective insulin signaling on skeletal muscle of myotonic dystrophy patients

L.V. Renna, F. Bosè, E. Brigonzi, B. Fossati, G. Meola, R. Cardani (Milano)

P.16 Involvement of interleukin-6 and vitamin D interplay in controlling visceral adiposity in myotonic dystrophy type 1

C. Terracciano, E. Frezza, G. Greco, E. Rastelli, S. Bernardini, M. Nuccetelli, R. Massa (Roma)

Genova 6 - 9 Giugno 2018 | Magazzini del Cotone



P-1-3 DMD and BMD

Chairpersons: Luca Doglio, Federica Ricci

P.17 Genetic association study of articular range of motion in the CINRG Duchenne Natural History Study

*L. Bello, T. Duong, E. Henricson, E. P. Hoffman, C. M. McDonald, H. Gordish-Dressman, CINRG Investigators
(Padova; Palo Alto, USA; Sacramento, USA; Washington, USA; Binghamton, USA)*

P.18 One mutation, two phenotypes: role of muscle biopsy

*G. Bruno, L. Allegorico, G. Di Iorio, S. Sampaolo, A. Varone
(Napoli)*

P.19 International DMD: a PTC Therapeutics-supported project to widely identify Dystrophin mutations using NGS technology

*A. Ferlini, R. Selvatici, C. Trabanelli, S. Neri, R. Rossi, S. Fini, P. Rimessi, M.S. Falzarano, A. Venturoli, M. Neri and F. Gualandi
(Ferrara)*

P.20 SPP1 and LTBP4 genotypes modify upper limb function in Duchenne muscular dystrophy

*Fusto, L. Bello, A. D'Amico, M. Scutifero, G.L. Vita, S. Messina, M. Pane, G. D'Angelo, A. Pini, E. Mercuri, L. Politano, E. Bertini, E. Pegoraro
(Padova; Roma; Napoli; Messina, Lecco; Bologna)*

P.21 DMD child born from egg donation procedure: could it be avoided?

V. Galimberti, R. Tironi, M. Ripolone, M. Scali, L. Peverelli, A. Lerario, G.P. Comi, M. Moggio, M. Sciacco. (Milano)

P.22 Language abilities and oral muscle strength in DMD and BDM boys

*S. Lenzi, A. Cravero, E. Moretti, C. Pecini, S. Frosini, G. Astrea, G. Cioni, R. Battini
(Pisa)*

P.23 Becker muscular dystrophy presenting with epilepsy and mild cognitive impairment: double trouble or CNS involvement related to Dystrophin gene mutation?

A. Lerario, L. Peverelli, R. Tironi, L. Spazzini, M. Mastrangelo, M. Sciacco, G. P. Comi, M. Moggio. (Milano)

P.24 Euro-nmd and collaborative platform: a telemedicine tool to break down barriers in neuromuscular diseases

*F. Fortunato, A. Mauro, M. Neri, F. Gualandi, T. Evangelista, A. Ferlini
(Ferrara; Newcastle upon Tyne, UK)*

Poster Section



P.25 Efficacy of coenzyme Q10 in patients with dystrophinopathic cardiomyopathy

P. D'Ambrosio, A. Palladino, M. Scutifero, R. Petillo, C. Orsini, Luigia Passamano, L. Politano (Napoli)

P.26 Translarna therapy in Duchenne manifesting carriers due to stop codon dystrophin gene mutations. A case report.

P. D'Ambrosio, V. Nigro, L. Politano (Napoli)

P.27 Clinical variability of Becker muscular dystrophy: tools to identify phenotypic subgroups

G. Ricci, F. Florio, G. Astrea, S. Baldanzi, C. Simoncini, A. Rocchi, F. Baldinotti, A. Giannoni, G.D. Aquaro, M. Emdin, G. Siciliano (Pisa)

P.28 Dystrophinopathies in couples of brothers: take the difference, if any

M. Rossi, R. Scalise, F. Ricci, L. Bello, E. Rolle, U. Balottin, T. Mongini, E. Mercuri, E. Pegoraro, A. Berardinelli. (Pavia; Roma; Torino; Padova)

P.1-4- FSHD/ Inflammatory Myopathies

Chairpersons: Rita Barresi, Lucia Ruggiero

P.29 Proposal of a cognitive approach to focus brain functioning in facioscapulohumeral muscular dystrophy (FSHD)

S. Baldanzi, G. Ricci, F. Torri, C. Simoncini, G. Siciliano (Pisa)

P.30 Longitudinal evaluation of muscle involvement in FSHD by qualitative muscle MRI.

M. Monforte, G. Tasca, M. R. Bagnato, P. Ottaviani, F. Laschena, A. Picchiecchio, E. Ricci (Roma, Pavia)

P.31 Monozygotic twins with reduced D4Z4 fragment on chromosome 4 and different phenotype: which other factors in etiopathology?

L. Vercelli, R. Tupler, S. Bortolani, V. Ponzalino, F. Mele, M. Govi, T. Mongini (Torino; Modena e Reggio Emilia)

P.32 Progressive respiratory failure: an unusual polymyositis presentation

T. Brizzi, A. Lupica, M. Gaeta, G. Vita, A. Toscano, C. Rodolico (Messina; Palermo)

P.33 Expression of type I and type II interferons is increased in muscle biopsies of juvenile dermatomyositis (JDM) patients and related to clinical and histological features

G.M. Moneta, S. Rosina, C. Fiorillo, D. Pires Marafon, M. Verardo, L. Bracci Laudiero, C. Minetti, A. Ravelli, F. De Benedetti, R. Nicolai (Roma; Genova)

Genova 6 - 9 Giugno 2018 | Magazzini del Cotone



P.34 Benign acute viral myositis: a clinical, pathological and serological study of five cases

E. Pancheri, G. Vatterli, S. Ferrari, A. Zamò, S. Sartoris, M. Lanzafame, A. Angheben, P. Tonin (Verona)

P-1-5 LGMD

Chairpersons: Francesca Magri, Gianluca Vita

P.35 A novel Emerin mutation in a patient with early onset Emery-Dreifuss muscular dystrophy.

S. Bozzetti, G. Vatterli, P. Rimessi, F. Macchione, E. Pancheri, V. Guglielmi, A. Ferlini, P. Tonin (Verona; Ferrara)

P.36 A novel mutation in the N-terminal acting binding domain of filamin C causing a distal myofibrillar myopathy

C. Gemelli, C. Fiorillo, S. Fabbri, L. Trevisan, C. Bruno, C. Minetti, L. Maggi, S. Gibertini, P. Mandich, A. Schenone, M. Grandis (Genova; Milano)

P.37 Long term follow-up and molecular studies in a LGMD1F sporadic TNPO3-mutated patient

S. Gibertini, A. Ruggieri, S. Saredi, A. Torella, M. Moggio, V. Nigro, L. Morandi, L. Maggi, M. Mora (Milano; Napoli)

P.38 Novel TRIM32 mutation in sarcotubular myopathy

M. Traverso, C. Panicucci, S. Baratto, E. Gazzero, M. Iacomino, G. Pozzolini, P. Broda, F. Madia, F. Zara, E. Gazzero, C. Bruno, C. Minetti, C. Fiorillo (Genova; Berlino, DE)

P.39 Laminopathy caused by a novel missense mutation.

E. Torchia, M. Garibaldi, E. Bucci, S. Ficili, E.S. Bertini, F. Fattori, E.M. Pennisi (Roma)

P.40 Anti PABPN1 abs in the diagnosis of OPMD

L. Peverelli, R. Tironi, M. Scali, A. Lerario, R. Del Bo, V. Galimberti, G. Fagiolari, M. Mora, C. Rodolico, M. Sciacco, A. Toscano, G.P. Comi, M. Moggio (Milano; Messina)

P.41 Novel COL6A3 mutation in two sibs with congenital muscular dystrophy

R. Trovato, A. Rubegni, F. Melani, M. Sorbo, D. Cassandrini, J. Baldacci, S. Doccini, F.M. Santorelli (Pisa; Firenze)

P.42 Mutations in the SYNE1 gene cause autosomal recessive CMD: the first case report

G.L. Vita, M. Sframeli, G. Astrea, A. D'Amico, E. Bertini, F.M. Santorelli, G. Vita, S. Messina (Messina; Milano; Pisa)

Poster Section



POSTER SECTION 2- June 8th- h. 14.00-15.30

P2-1- Metabolic Myopathies

Chairpersons: Matteo Garibaldi, Claudio Semplicini

P.43 Glycogenosis VII with early fixed myopathy; a clinical and MRI study

S. Cotti Piccinelli, A. Picbiecchio, O. Musumeci, M. Marchesi, F. Caria, S. Gallo Cassarino, E. Baldelli, A. Galvagni, A. Toscano, A. Padovani, M. Filosto (Brescia; Pavia; Messina)

P.44 Acute rhabdomyolysis: a NGS panel for metabolic myopathies

M.A. Donati, F. Tubili, F. Pochiero, L. Ferri, M. Sacchini, E. Procopio, G. Scaturro, M. Daniotti, A. Pini, A. Morrone, E. Pasquini (Firenze; Bologna)

P.45 A GMPPB mutation causing paucisymptomatic hyperckemia in an adult patient

S. Gallo Cassarino, A. Galvagni, G. Lanzi, S. Cotti Piccinelli, M. Marchesi, F. Caria, E. Baldelli, S. Giliani, A. Padovani, M. Filosto (Brescia)

P.46 Relapsing episodes of intestinal pseudo-obstruction led to a late diagnosis of MELAS

A. Govoni, D. Gagliardi, F. Magri, D. Velardo, D. Piga, D. Ronchi, S. Brajkovic, M. Moggio, C. Cinnante, S. Corti, G.P. Comi (Milano)

P.47 Late onset multiple acyl-CoA dehydrogenase deficiency: it's never too late.

F. Macchione, A. Bordugo, M. Vincenzi, M. Camilot, F. Teofoli, L. Salviati, G. Vattemi, P. Tonin (Verona; Padova)

P.48 New Italian case of authofagic vacuolar myopathy associated with a mutation in CLN3

F. Moro, A. Rubegni, J. Baldacci, F. Pochiero, E. Procopio, M.A. Donati, F.M. Santorelli (Pisa; Firenze)

P.49 Glucose free/high protein diet ameliorates muscle performance in GSDIII mice

S. Pagliarani, S. Lucchiari, G. Ulzi, M. Ripolone, R. Violano, A. Bordoni, F. Fortunato, M. Moggio, G. P. Comi (Milano)

P.50 Non-skeletal canonic muscle involvement as prominent feature in Pompe disease: two case reports

C. Simoncini, G. Ricci, V. Montano, L. Cbico, L. Calì Cassi, G. Alì, G. Comi, F. Baldinotti, C. Cosini, F. Lembo, G. Siciliano (Pisa; Milano)

Genova 6 - 9 Giugno 2018 | Magazzini del Cotone



P2-2- Myasthenic Syndromes

Chairpersons: Rosanna Cardani, Marina Grandis

P.51 Lambert-Eaton myasthenic syndrome and IgG4-related disease: a possible novel association

E. Baldelli, E. Borlenghi, S. Cotti Piccinelli, F. Caria, M. Marchesi, S. Gallo Cassarino, A. Padovani, M. Filosto (Brescia)

P.52 Nivolumab-induced acute rhabdomyolysis and myasthenic syndrome

V. Bozzoni, S. Lelli, T. Rosso, C. Semplicini, L. Bello, G. Maccarrone, G. Vicario, F. Salmaso, R. Risato, C. Tassinari, R. Costa, G. Cenacchi, E. Pegoraro (Padova; Castelfranco Veneto; Bologna)

P.53 Methotrexate as steroid-sparing agents in patients with myasthenia gravis

T. Brizzi, A. Lupica, S. Messina, A. Toscano, C. Rodolico (Messina; Palermo)

P.54 Myasthenia Gravis: epidemiologic features, clinical course, and treatment approaches in two Ligurian centers.

C. Cabona, C. Gemelli, S. Fabbri, L. Benedetti, C. Caponnetto, GL. Mancardi, A. Mannironi, A. Beronio, A. Schenone, M. Grandis (Genova; La Spezia)

P.55 Isolated, long-standing weakness in jaw closure as presenting symptom of myasthenia gravis.

E. Schirinzì, A. De Rosa, M. Maestri, R. Ricciardi, G. Siciliano (Pisa)

P.56 Bi-allelic mutations in TTN cause congenital centronuclear myopathy: a case report

G. Astrea, D. Cassandrini, C. Fiorillo, S. Frosini, M. Traverso, A. Rubegni, M. Savarese, F.M. Santorelli, C. Minetti (Pisa; Genova; Napoli; Helsinki, FIN)

P2-3- Congenital Myopathies

Chairpersons: Guya Astrea, Marina Pedemonte

P.57 Severe nemaline myopathy manifesting as 'Amish phenotype' related to homozygous mutation in TNNT1

A. D'Amico, F. Fattori, C. Fiorillo, M. Verardo, M. Catteruccia, E. Bellacchio, C. Bruno, M. Moggio, E. Bertini (Roma; Genova; Milano)

P.58 Congenital fiber type disproportion related to novel autosomal dominant mutation in TNNT1

F. Fattori, A. D'Amico, M. Verardo, E. Bellacchio, T. Brizzi, A. Fiumara, E. Bertini, C. Rodolico (Roma; Palermo; Catania; Messina)

Poster Section



P.59 Merosin-Deficient Congenital Muscular Dystrophy type 1A: a case report with myopathologic and genetic findings.

F. Girolamo, A. Lia, A. Amati, L. Serlenga, L. De Cosmo, N. Laforgia, N. Resta, M. Trojano (Bari)

P.60 Clinical and histological variability of RYR1 gene related myopathy: report of two novel cases

A.R. Pati, I. Di Donato, A. Mignarri, S. Salvatore, G. Berti, D. Cassandrini, F.M. Santorelli, M.T. Dotti, A. Malandrini. (Siena; Pisa)

P.61 Congenital myopathy due to RYR1 mutations: early findings at muscle biopsy and muscle MRI in neonatal cases

D. Velardo, F. Magri, A. Govoni, R. Brusa, M. Sciacco, L. Peverelli, G. Fagiolari, C. Cinnante, D. Piga, R. Dilella, D. Cassandrini, S. Corti, N. Bresolin, M. Moggio, G. P. Comi (Milano; Pisa)

P.62 TRPV4-associated disorders: intrafamilial variability.

S.M. Tripodi, I. Martinelli, C. Semplicini, L. Bello, G. Sorarù, E. Pegoraro (Padova)

P2-4- Miscellanea

Chairpersons: Michela Catteruccia, Paola Lanteri

P.63 Fibrodysplasia ossificans progressive, a rare disease: a case report.

C. Bonanno, O. Musumeci, G. Vita, T. Brizzi, A. Toscano, C. Rodolico (Messina)

P.64 Multidisciplinary care in infant neuroaxonal dystrophy-related symptoms: a case report of two twins

F. Salmin, E. Carraro, M. Moscardi, V. Morettini, E. Albamonte, V. A. Sansone (Milano)

P.65 Neuromuscular complications following target therapy in cancer patients

C. Demichelis, C. Lapucci, S. Grisanti, C. Genova, F. Grossi, E. Tanda, P. Queirolo, L. Benedetti, A. Schenone, M. Grandis (Genova)

P.66 Euro-nmd and collaborative platform: a telemedicine tool to break down barriers in neuromuscular diseases

F. Fortunato, A. Mauro, M. Neri, F. Gualandi, T. Evangelista, A. Ferlini (Ferrara; Newcastle upon Tyne, UK)

P.67 Expanded Access Program (EAP): another point of view

E. Gotti, C. Grandi, A. Lizio, J. Casiraghi, E. Carraro, E. Albamonte, V.A. Sansone (Milano)

Genova 6 - 9 Giugno 2018 | Magazzini del Cotone



**P.68 Airways microbial colonization in neuromuscular patients.
The Istituto Gaslini experience.**

*M. Diana, M. Pedemonte, C. Fiorillo, C. Bruno, C. Minetti, R. Bandettini
(Genova)*

**P.69 NGS in diagnosis: identification of causative mutations in cases with
misleading clinical phenotype**

*A. Ruggieri, S. Saredi, S. Gibertini, L. Peverelli, A. Lerario, P. Bernasconi, R. Brugnoli,
M. Savarese, B. Udd, L. Maggi, M. Mora
(Milano; Helsinki, FIN)*

**P.70 Robot-aided assessment of peripheral muscular fatigue in children with
neuromuscular disorders**

*M. Mugnosso, F. Marini, L. Doglio, C. Panicucci, C. Bruno, P. Moretti, P. Morasso,
J. Zenzeri
(Genova)*

P.71 Small fibre neuropathy in mitochondrial diseases explored with sudoscan.

*G. Primiano, M. Luigetti, C. Cuccagna, D. Bernardo, D. Sauchelli, C. Vollono, S. Servidei
(Roma)*

**P.72 A transitional care experience with 3 patients affected different
neuromuscular disorders**

*G. Siciliano, G. Astrea, F. Santorelli, S. Baldanzi, G. Ricci
(Pisa)*

P2-5- Mitochondrial Myopathies

Chairpersons: Daniele Orsucci, Olimpia Musumeci

**P.73 Novel homozygous mutation in mitochondrial translation elongation factor
EFTs (TSFM) in an Italian child with mitochondrial encephalopathy
and hypertrophic cardiomyopathy.**

*G. Brigati, C. Fiorillo, C. Nesti, A. Rubegni, C. Bruno, M.S. Severino, C. Minetti,
F.M. Santorelli (Genova; Pisa)*

P.74 Novel mutation in PMPCA in a boy with Leigh-like brain imaging

*C. Dosi, C. Nesti, A. Rubegni, F. D'Amore, F. Morani, R. Pasquariello, G. Astrea,
R. Battini, F.M. Santorelli
(Pisa)*

**P.75 Mitochondrial dysfunction in a boy with Mevalonate kinase deficiency
(MKD)**

*R. Oteri, R. Gallizzi, A. Ciranni, C. Rodolico, G. Zirilli, R. Arrigo, F. De Luca,
A. Toscano, O Musumeci
(Messina)*

Poster Section



P.76 Complex multisystem phenotype associated with the mitochondrial DNA m.5522G>A mutation

C. Nesti, J. Baldacci, F. D'Amore, A. Rubegni, F.M. Santorelli (Pisa)

P.77 Diagnostic approach in primary mitochondrial myopathy in the era of genomic medicine.

G. Primiano, R. Carrozzo, C. Cuccagna, G. Colacicco, J. Marotta, C. Sancricca, A. Torraco, D. Verrigni, S. Servidei (Roma)

P.78 Complex IV deficiency due to a novel SCO2 mutation associated with progressive cavitating leukoencephalopathy

Rubegni, C. Nesti, S. Doccini, F. Morani, F. D'Amore, R. Pasquariello, R. Canapicchi, A. R. Ferrari, F.M. Santorelli. (Pisa)

P.79 The Nation-wide Italian Collaborative Network of Mitochondrial Diseases: A cross-sectional survey on mitochondrial epilepsies

C. Ticci, A. Ardisson, E. Bertini, V. Carelli, D. Diodato, L. Di Vito, M. Filosto, C. La Morgia, C. Lamperti, D. Martinelli, I. Moroni, O. Musumeci, E. Pancheri, L. Peverelli, G. Primiano, A. Rubegni, S. Servidei, G. Siciliano, C. Simoncini, P. Tonin, A. Toscano, M. Mancuso, F.M. Santorelli (Pisa; Milano; Roma; Bologna; Messina; Verona)

P.80 The Mitochondrial DNA m.10197G>A mutation in three children with Leigh Syndrome

D. Tolomeo, A. Rubegni, D. Cassandrini, F. Pochiero, C. Bruno, M. Di Rocco, S. Doccini, A. Madeo, M.A. Donati, A. Rossi, F.M. Santorelli, C. Nesti (Pisa; Florence; Genova)

P2-6- SMA

Chairpersons: Giovanni Baranello, Federica Trucco

P.81 Revised Upper Limb Module for Spinal Muscular Atrophy: 12 month changes

L. Antonaci, M. C. Pera, G. Coratti, E. S. Mazzone, J. Montes3, M. Scoto, R. De Sanctis, N. Forcina, M. Main5, A. Maybew, R. Muni Lofra, S. Dunaway Young, A. M. Glanzman, T. Duong, A. Pasternak, D. Ramsey, B. Darras, J. W. Day, R. S. Finkel, D. C. De Vivo, M. P. Sormani, F. Bovis, F. Muntoni, M. Pane, E. Mercuri (Roma; New York, USA; London, UK; Newcastle, UK; Philadelphia, USA; Stanford, USA; Boston, USA; Orlando, USA; Genova)

P.82 CT-guided lumbar puncture for intrathecal Nusinersen administration in SMA1 patients with challenging access. The Istituto Gaslini experience.

C. Gandolfo, M. Ferretti, G. Brigati, A. Incontrera, L. Bombardieri, E. Bobeica, G. Montobbio, C. Minetti, M. Pedemonte, C. Bruno (Genova)

Genova 6 - 9 Giugno 2018 | Magazzini del Cotone



P.83 The natural history of respiratory function in a cohort of patients affected by spinal muscular atrophy type 2 and 3

D'Amico, M. Pedemonte, M. Catteruccia, A. Longo, G. Brigati, P. Tacchetti, C. Bruno, E. Bertini (Roma; Genova)

P.84 Structured light plethysmography and spinal muscular atrophy type 1

M. Ferretti, F. Trucco, P. Tacchetti, C. Avanti, E. Bobeica, C. Bruno, M. Pedemonte, C. Minetti (Genova)

P.85 Homozygous deletion of AGTPBP1 in a child with motor neuron disease and cerebellar atrophy

M. Scala, P. De Marco, E. Merello, E. Tassano, P. Ronchetto, P. Lanteri, P. Picco, M.S. Severino, C. Fiorillo, V. Capra (Genova)

P.86 Does albuterol have an effect on neuromuscular junction dysfunction in spinal muscular atrophy?

M.C. Pera, M. Luigetti, S.Sivo, L. Lapenta, G. Granata, L. Antonaci, G. Coratti, N. Forcina, M. Pane, E. Mercuri (Roma)

P.87 FIREFISH Part 1: RG7916 significantly increases SMN protein in SMA Type 1 babies

G. Baranello, L. Servais, J.W. Day, N. Deconinck, E. Mercuri, A. Klein, B. Darras, R. Masson, H. Kletzl, Y. Cleary, G. Armstrong, T. Seabrook, C. Czech, M. Gerber, K. Gelblin, K. Gorni, O. Khwaja (Milano; Liège, BE; Palo Alto, USA; Ghent, BE; Roma; Berna, SWI; Boston, USA; Basilea, SWI; Welwyn Garden City, UK)

P.88 JEWELFISH: RG7916 increases SMN protein in patients with SMA that have previously received therapies targeting SMN2 splicing

C. Chiriboga, E. Mercuri, D. Fischer, D. Kraus, N. Thompson, G. Armstrong, H. Kletzl, M. Gerber, Y. Cleary, T. Bergauer, K. Gorni, O. Khwaja (New York, USA; Roma; Basilea, SWI; Welwyn Garden City, UK)

P.89 SUNFISH Part 1: RG7916 treatment results in a sustained increase in SMN protein levels

E. Mercuri, G. Baranello, J. Kirschner, L. Servais, N. Goemans, M. C. Pera, J. Buchbjerg, G. Armstrong, H. Kletzl, M. Gerber, C. Czech, Y. Cleary, K. Gorni, O. Khwaja (Roma; Milano; Freiburg, DE; Liège, BE; Anversa, BE; Basilea, SWI; Welwyn Garden City, UK)

P.90 Electrocardiographic evaluation in patients with spinal muscular atrophy: a case-control study

S. Catanzaro, R. Falsaperla, G. Vitaliti, A. D. Collotta, C. Fiorillo, A. Pulvirenti, S. Alaimo, C. Romano, M. Ruggieri (Catania; Genova)

ABSTRACTS OF INVITED LECTURES

(in alphabetical order of the first Author)

A registry-based approach for disease classification and outcome measures harmonization in myotonic dystrophyBassez G.¹, Dogan C.¹, De Antonio M.¹, Hamroun D.², French Myotonic Dystrophy Study Group¹ Institute of Myology, AP-HP, Sorbonne Université, Pitié Salpêtrière hospital, Paris, France; ² CHU de Montpellier

The broad clinical spectrum of myotonic dystrophy type 1 (DM1) creates particular challenges for both medical care and the design of clinical trials. Clinical onset spans a large continuum from birth to late adulthood, including highly variable symptoms regarding severity and nature of the affected organ systems. In the literature, this complex phenotype is divided from three grades (mild, classic, and severe) to four or five clinical categories (congenital, infantile/juvenile, adult-onset and late-onset forms), and no consensus is established so far.

the relevance of registries as a key component for developing rare diseases clinical research and improving patient care has been acknowledged and we used the DM-Scope registry to assess the robustness of a classification divided into five clinical grades in a large cohort of DM1 patients. Our main aim was to describe the disease spectrum and investigate features of each clinical form. The five subtypes were compared by distribution of CTG expansion size, and the occurrence and onset of the main symptoms of DM1. Analyses validated the relevance of a five-grade model for DM1 classification. Based on this classification we investigated the phenotype of youngest DM1 patients from neuropediatric centers (n = 315), including congenital, infantile and juvenile affected individuals. Our data support the assumption of a continuum from congenital to the late-onset form, and highlights distinctive clinical profiles to be considered for health management and clinical trial in DM.

Body composition and energy expenditure in SMA patientsBertoli S.¹, De Amicis R.¹, Foppiani A.¹, Mastella C.², Giaquinto E.³, Battezzati A.¹, Leone A.¹, Baranello G.⁴¹ International Center for the Assessment of Nutritional Status (ICANS), Department of Food Environmental and Nutritional Sciences (DeFENS), University of Milan, Milan, Italy; ² S.A.P.R.E., Early Habilitation Service, Mangiagalli e Regina Elena Hospital, Milan, Italy; ³ Dietetic and Nutrition Center, M. Bufalini Hospital, Cesena, Italy; ⁴ Developmental Neurology Unit, Carlo Besta Neurological Institute Foundation, Milan, Italy

Spinal Muscular Atrophy (SMA) is characterized by degeneration of spinal cord motor neurons, atrophy of skeletal muscles, and generalized weakness and in SMA

type 1 (SMAI) and type 2 (SMAII), the most common and severest forms, are frequently present nutritional problems. In particular, SMAI children present impairment in breathing and swallowing that require early mechanical ventilation and artificial feeding and induce undernutrition condition, whereas SMAII children, have a quite common condition of “weak” swallowing together with chewing and respiratory problems with a higher risk of overweight even if in a percentage of cases malnourishment is also reported. The preliminary data on nutritional status and body composition collected during an ongoing multicentre study on growth pattern and body composition in SMAI and II children confirmed the high prevalence of malnutrition but also underlined the high risk of misdiagnosis of undernutrition due to peculiar body composition in SMA children.

The specific features of body composition in SMA disease in the total and regional fat, lean, mineral masses and body water (total, intra- and extra-cellular) and of energy metabolism together with the methods for the assessment of body composition and resting energy expenditure in order to optimized dietary management in daily clinical practice will be analysed.

Muscle-specific CRISPR/Cas9 dystrophin gene editingBengtsson N.^{1,4}, Crudele J.^{1,4}, Hall J.^{1,4}, Chamberlain J.R.^{3,4}, Tasfout H.^{1,4}, Hauschka S.D.^{2,4}, Chamberlain J.S.^{1,2,3,4}¹ Department of Neurology; ² Department of Biochemistry; ³ Department of Medicine, Division of Medical Genetics; ⁴ Senator Paul D. Wellstone Muscular Dystrophy Cooperative Research Center; University of Washington School of Medicine, Seattle, Washington 98195 USA

Gene editing represents a potential therapy for Duchenne muscular dystrophy. Encouraging early data has been presented by several groups, but the method is not yet ready for clinical use. Remaining challenges include the ability to edit both myogenic stem cells and muscle cells, off-target editing, overall editing efficiency and the ability to target mutations throughout the 2.2 MB dystrophin gene. We have been addressing these issues via intravascular delivery of CRISPR/Cas9 components using vectors derived from adeno-associated viruses (AAV). AAV6, 8 and 9 display low-level targeting of quiescent satellite cells, although activated satellite cells are robustly targeted. As most AAV vectors target tissues body-wide we tested delivery of Cas9 under control of muscle creatine kinase (MCK) regulatory cassettes (RC) active

only in post-mitotic muscle cells. MCK-Cas9 vectors induced dystrophin gene editing only in striated muscles, at an efficiency equivalent to that using ubiquitously active RCs. We further showed that the rate of myogenic cell necrosis limits editing efficiency. Multiple strategies were tested to target different types of mutations. Deletion of exon(s) using multiple guide RNAs induced dystrophin expression via 'exon skipping', but with lower efficiencies than with one guide RNA. Complete gene correction via homologous recombination in myofibers was achieved, but at a low efficiency. While the overall efficiency using current methods remains lower than needed for significant clinical benefit, we saw similar efficiencies in both murine and canine models. These results suggest that modest improvements in editing efficiencies could lead to a robust clinical approach for DMD.

Mechanobiology defects in LMNA-related congenital muscular dystrophy

Coirault C.

Institut de Myologie, Sorbonne University, Paris France

The primary function of skeletal muscle is to produce force and movement. Mechanical forces in turn are critical to control muscle cell decisions and tissue homeostasis. Our general aim is to explore how mechanical forces affect muscle mass and function in normal and pathological conditions and to determine the mechanisms of mechanosensing defects in the pathophysiology of muscular dystrophies related to mutations in nuclear envelope proteins.

Using 3D cellular model we set up, we revealed defective mechanosensing of human lamin mutant myoblasts due to abnormal YAP signaling, and emphasized the crucial role of the biophysical attributes of the cellular microenvironment. We further investigate i) the role of defective dynamic actin-mediated cellular functions and YAP signaling, ii) the dynamic response of cell-matrix adhesion, cytoskeleton components including measurement of traction force, nuclear deformations, and mechano-transduction signaling; iii) the influence of varying matrix stiffness on the mechanosensitive responses of myoblasts and iv) the role of lamin in skeletal muscle plasticity in vivo. We aim obtaining detailed description of the molecular events taking place within the nucleus after application of a mechanical stress on a cell, in order to understand i) how a mechanical force is transformed into biochemical signal, ii) how these signals impact the interactions involved in nuclear envelope architecture that may regulate nuclear rigidity/deformability, iii) how they modify interactions between nuclear envelope and chromatin that may regulate mechanosensitive gene expression and iv) how these defects contribute to muscle disorders.

Nusinersen in SMA adult patients: first experiences

Comi G.P.

Dino Ferrari Centre, Neuroscience Section, Department of Pathophysiology and Transplantation (DEPT), University of Milan, Neurology Unit, IRCCS Foundation Ca' Granda Ospedale Maggiore Policlinico, Milan, Italy

Spinal Muscular Atrophy (SMA) is an autosomal recessive disorder affecting 1:10,000 live births, in which deficient Survival Motor Neuron protein leads to progressive muscle atrophy, weakness, and early mortality. SMA has been clinically subdivided in type I, II and III subgroups. Nusinersen is the first FDA and EMA approved treatment for any type of SMA.

Clinical trials have shown benefit in children, but the efficacy in adults has not been documented.

Recently data on functional and clinical measures prospectively collected on nusinersen-treated adult SMA patients were presented at AAN, based in 10 US clinics (Day et al, SMA PNCR network, 2018) and in a single center experience (Elsheikh et al. OSU, 2018).

A minimal data set based on validated outcomes in SMA included at least one of the following: CHOP-INTEND, RULM, HFMSE, TUG, 6MWT. Respiratory function, cMAP, strength, patient reported experiences, safety labs and adverse events were also monitored. A total of 49 adult SMA patients were treated, their data were both compared with their baseline as well as to available natural history data. For all of these patients, this was a first year clinical observation. Treatment was well tolerated. Subjective improvements are often reported and are sustained. Improvement trends are emerging in multiple measures too. For patients and clinicians the meaningful of changes are relatives and even minimal variations could have some real quality of life relevance. In Italian centres including also ours, SMA adult patients are receiving treatment and data continue to be collected.

SMA from models to mechanisms to therapy

Corti S.

Dino Ferrari Centre, Neuroscience Section, Department of Pathophysiology and Transplantation (DEPT), University of Milan, Neurology Unit, IRCCS Foundation Ca' Granda Ospedale Maggiore Policlinico, Milan, Italy

Spinal muscular atrophy (SMA) is a neuromuscular disease, characterized by the progressive loss of motor neurons in the spinal cord, which leads to muscle weakness and atrophy. SMA remains the leading inherited cause of infant mortality. The condition is caused by the depletion of survival motor neuron (SMN) protein due to mutations in the SMN1 gene. During the last decades the development of reliable cellular and animal models were instrumental for understand-

ing the disease mechanisms and developing therapeutics in SMA. Recent advances in stem cell research, especially in the development of induced pluripotent stem cell (iPSC) technology, have opened up the possibility of generating a substantial amount of disease-specific cells, including motor neurons and glial cells implementing not only 2D, but also 3D platforms. Now drug molecules, antisense oligonucleotide, and gene therapy approaches, all of which had a major impact in cells and animal models of SMA, are used in clinic with positive results. Nusinersen, an antisense oligonucleotide that modulates the splicing of the SMN2 mRNA, is the first therapy approved for all types of SMA. Moreover, the first gene therapy clinical trial using adeno-associated virus (AAV) vectors encoding SMN showed positive results in survival and motor milestones achievement. Furthermore, other additional therapeutic options are in the pipeline, including modulation of SMN2 transcripts with small molecules, neuroprotective agents, and compounds that act on other peripheral targets. We discuss the challenges from implementing innovative models to understand novel mechanisms and to develop effective treatments for patients with SMA.

Therapeutical approach to nonsense mutations

D'Amico A.

Unit of Neuromuscular and Neurodegenerative Disorders, Bambino Gesù Children's Hospital

Duchenne muscular dystrophy (DMD) is the most common form of muscular dystrophy in childhood. It is a X-linked genetic disorder caused by mutations of the DMD gene that codes for dystrophin.

The loss of dystrophin in patients with DMD disrupts the muscle membrane and fibres. This leads to progressive muscle weakness. Most affected children first present with symptoms between the ages of three and five years and the symptoms gradually worsen with time, leading to loss of ambulation, dilated cardiomyopathy, respiratory insufficiency and early death. It is caused by mutations of the dystrophin gene that disrupt the reading frame of the mRNA coding sequence, which leads to complete absence of dystrophin expression in skeletal and cardiac muscles.

Deletions and duplications have been shown to account for ~ 70% of the gene mutations. The remaining 30% of affected have smaller mutations (nucleotide substitutions or small deletions/insertions).

A nonsense mutation results in a premature stop codon within the protein coding region of the corresponding messenger ribonucleic acid (mRNA) and causes premature termination of translation and generation of a truncated, unstable, nonfunctional protein.

Ataluren has been the first treatment approved for DMD.

Here will be discussed the results of completed and ongoing clinical trials.

Precision medicine in non-dystrophic myotonias

Desaphy J.-F.

Dept. of Biomedical Sciences and Human Oncology, University of Bari Aldo Moro, Policlinico, piazza Giulio Cesare n.11, 70124 Bari, Italy

Nondystrophic myotonias are caused by gain-of-function mutations of the Nav1.4 sodium channel or loss-of-function mutations of the CIC-1 chloride channel. Whatever the culprit gene, sodium channel blockers have been empirically used in myotonia because they reduce abnormal action potential firing in myofibers. A clinical trial confirmed mexiletine effectiveness in myotonic patients. Yet about 30% of patients are intolerant or report unsatisfactory response to mexiletine.

We wondered whether myotonic Nav1.4 mutations modify channel sensitivity to mexiletine. We found that the G1306E mutation impairs mexiletine block but preserves sensitivity to flecainide. Accordingly, myotonic G1306E carriers unsatisfied with mexiletine obtained great improvement with flecainide (Desaphy et al., 2001; 2004; 2013). Mexiletine-to-flecainide shift was also successful in a girl carrying P1158L mutation that evokes functional defects similar to G1306E (Desaphy et al., 2016). We are committed to the pharmacological characterization of Nav1.4 mutations identified by the Italian Network for Skeletal Muscle Channelopathies, with the aim to identify the best drug for each mutation. In chloride channel myotonia, loss of function of CIC-1 channels stems from gating alteration or intracellular trafficking impairment. No CIC-1 channel activator is currently available. We used potent and reversible inhibitors of CIC-1 channels to define the drug binding sites and better understand drug effects on channel gating. In parallel, we performed proof-of-concept studies to verify the ability of pharmacological chaperones to restore sarcolemma expression of trafficking-deficient CIC-1 mutants. Altogether, these studies define a pharmacogenetics strategy to address precision medicine in myotonic individuals. Supported by Italian Telethon (GGP14096) and A.F.M. (19027).

EURO-NMD: the European Reference Network for Neuromuscular Diseases

Evangelista T., on behalf of EURO-NMD partners

John Walton Muscular Dystrophy Research Centre, Institute of Genetic Medicine, Newcastle University, UK

EURO-NMD is the European Reference Network for rare neuromuscular diseases (NMDs), a broad group of related disorders that represent a major cause of mortality and lifelong disability in children and adults. NMDs are difficult to recognize, and patients experience long delays in diagnosis. There are no curative treatments and their rarity and di-

versity pose specific challenges for healthcare and research, and for the development and marketing of therapies.

NMDs collectively affect an estimated 500,000 EU citizens and result in significant costs for families and the healthcare system. EURO-NMD unites 61 of Europe's leading NMD clinical and research centres in 14 Member States and includes highly active patient organizations. The network addresses harmonizing and implementing standards for clinical and diagnostic best practice, improving equity of care provision across Member States, decreasing time to diagnosis, increasing cost efficiency through better care pathways, access to specialist training and education, application of eHealth services, development and application of care guidelines, facilitating translational and clinical research, harmonising data and samples for research reuse, and sharing of high-quality data.

EURO-NMD is now an operational network with active participation from our Health Care Providers (HCPs) in all disease and diagnostic working groups. The working groups have designed a number of questionnaires that were sent to all HCPs aiming to identify where the main expertise in each area was located across Europe. A series of GAP analysis of published guidelines was done by each group. The guidelines in need of development or updating were identified. We have established connections with the learned societies, with the other ERNs and have also been instrumental in shaping the political decisions of the European Commission. As we move into year two, our priorities are to strengthen the ERN; planning a more direct participation of the HCPs and patient representatives, endorse or develop the guidelines, develop an educational training programme, act on the existing research plan, deliver the first EURO-NMD training school and begin using the Clinical Patient Management System for e-Consultation.

ERNs are an interesting health-care model based on the dissemination of the best available information, education and e-Health. Due to their structure networks will be able to reach a greater number of stakeholders and have a good geographic coverage unlike traditional models where HCPs work for more confined communities.

The changing scenario of molecular genetic diagnosis in dystrophinopathies

Ferlini A.

Dubowitz Neuromuscular Unit, GOSH, University College London, UK; Unit of Medical Genetics, University of Ferrara, Italy

Dystrophin related phenotypes, as Duchenne and Becker muscular dystrophies, intermediated phenotypes and isolated cardiomyopathies, have been privileged by intense genetic characterization via pioneering and fruitful collaboration between neurologists and geneticists; genetic diagnosis is now an integral part of the diagnostic flowchart, mandatory for eligibility to treatments.

Next-generation sequencing (NGS) is increasingly being applied to dystrophinopathy testing, leading to a remarkable amelioration of genetic diagnosis, nevertheless its clinical translation is incomplete and standard molecular genetics tests are still needed.

Thus, an accurate and exhaustive molecular genetic diagnosis of dystrophinopathies needs clear strategies and new visions, since our goal, is to identify the genetic cause in all patients. Finally, a reflection can be made about the powerfulness of the new non-invasive prenatal diagnostic testing (NIPT), from one side, and the new personalized therapies now available, from the other. Finding synergic strategies for these two interventions dystrophinopathies would be greatly beneficial for patients and families.

Adult polymyositis

Filosto M.

Center for Neuromuscular Diseases, Unit of Neurology, ASST Spedali Civili and University of Brescia, Brescia, Italy

Polymyositis is an inflammatory myopathy characterized by progressive symmetrical proximal muscle weakness and high skeletal muscle enzyme levels.

It is an immune-mediated disease related to defective cellular immunity resulting in T-cell-mediated cytotoxic processes directed against unknown antigens.

Associated extramuscular diseases, such as malignancy and interstitial lung disease, need to be excluded in the work-up process.

An autoimmune response to cytoplasmic and nuclear antigens can be detected in serum of affected patients. It can be specifically related to the myositis process (myositis-specific antibodies) or shared with other autoimmune diseases (myositis-associated antibodies).

Main electromyography findings are fibrillation potentials and increased insertional activity associated with myopathic changes of motor unit action potentials.

Recently, muscle magnetic resonance imaging and ultrasonography emerged as useful tools helping in diagnosis and follow-up of response to therapy. They can localize the extent of muscle damage by showing signal intensity abnormalities due to inflammation and edema.

Although muscle biopsy occasionally may be normal because of patchy involvement, inflammatory changes are usually observed i.e. muscle fibers in varying stages of necrosis and regeneration and focal endomysial infiltration by mononuclear cells (mostly CD8+ T lymphocytes and macrophages surrounding healthy nonnecrotic fibers and then invading and destroy them).

Prednisone remains the first-line treatment for polymyositis. Immunosuppressive agents, i.e. methotrexate, azathioprine or cyclophosphamide, and intravenous immunoglobulins are used in poorly-responding patients.

Some newer agents, such as tumor necrosis factor in-

hibitors, the anti-CD20 monoclonal antibody rituximab and the calcineurin inhibitor tacrolimus may represent promising treatments for refractory cases.

Nutrition in the healthy population

Francini-Pesenti F.

Clinical Nutrition Unit, Department of Medicine, Azienda Ospedaliera di Padova, Padua-Italy

Knowing the criteria of proper nutrition in the general population is essential to define dietary approaches to diseases. Optimal macronutrients intake for a healthy diet has long been debated. The World Health Organization recommends that total fat should not exceed 30% of total energy intake to avoid weight gain with a shift in fat consumption away from saturated fats to unsaturated fats and towards the elimination of industrial trans fats. The importance of lowering the intake of saturated fat and replacing it with unsaturated fat, especially polyunsaturated fats was recently highlighted by a Presidential Advisory from the American Heart Association (AHA). The advice to restrict saturated fatty acids is based on some observational and clinical data, despite the existence of several randomized trials and observational studies that do not support these conclusions.

Recently, the Prospective Urban-Rural Epidemiology (PURE) study show that high carbohydrate intake is linked to worse total mortality and non-cardiovascular (CV) mortality outcomes, while high fat intake is associated with lower risk. In 2017, a meta-analysis combining data from 29 prospective cohort studies demonstrated neutral associations between dairy products and cardiovascular and all-cause mortality. Higher consumption of eggs (up to one egg per day) is not associated with increased risk of coronary heart disease and may contribute to a decreased risk of total stroke.

These data induce to reconsider the diet recommendations for the general population and the impact on health of some dietary approaches to diseases, such as ketogenic and Atkins diets.

Immunity in muscular dystrophies: friend or enemy?

Gazzerro E.^{1,2}, Assereto S.³, Baldassari S.³, Baratto S.¹, Panicucci C.¹, Fiorillo C.³, Raffaghello L.¹, Bruzzone S.⁴, Minetti C.³, Bruno C.¹

¹ Center of Myology and Neurodegenerative Disorders, Istituto Giannina Gaslini, Genova, Italy; ² Muscle Research Unit, Experimental and Clinical Research Center, Charité University Medicine Berlin and the Max Delbrück Center for Molecular Medicine, Berlin, Germany; ³ Pediatric Neurology and Muscle Disease Unit, Istituto Giannina Gaslini, Genova, Italy; ⁴ Departement of Experimental Medicine, Section of Biochemistry, University of Genova, Genova, Italy

The immune system exerts a dichotomous role in mus-

cular dystrophies with the development of two types of inflammation that, respectively, promote (I) and repair (II) muscle injury. T regulatory (regs) lymphocytes play a protective role by mediating type II inflammation: they accumulate in sites of necrosis, express immunosuppressive cytokines and directly stimulate satellite cells to induce regeneration. In this complex scenario, the danger associated molecule extracellular adenosine triphosphate (eATP) released by dying muscle cells appears to exert a pleiotropic role in contributing to the muscle immune-mediated damage by respectively enhancing type I and inhibiting Treg type II inflammation.

We showed that in vivo blockade of the eATP/Purinergic (P2X) signaling, by the generalized P2X receptors-antagonist periodate-oxidized ATP, delayed the progression of the dystrophic phenotype in mdx and a-SG knockout mice (Sgca). In α -sarcoglycanopathies (LGMD2D), eATP effects could be further amplified since α -sarcoglycan extracellular domain binds eATP and displays an ecto-ATPase activity, thus controlling eATP concentration at the cell surface of cells and attenuating the magnitude and/or the duration of eATP-induced signals.

eATP blockade dampened the local muscular inflammatory response and enhanced the recruitment of Foxp3+ immunosuppressive regulatory CD4+ T cells. The improvement of the inflammatory features was associated with increased strength, reduced necrosis and limited expression of pro-fibrotic factors, thus suggesting that pharmacologic purinergic antagonism altering the adaptive immune component in the muscle infiltrates might provide a new therapeutic approach to slow disease progression in muscular dystrophies.

The French Pompe registry: molecular features of non-classical Pompe disease and study of benefit of long term ERT in adults

Laforêt P., on behalf of French Pompe Study Group
Neurology department, neuromuscular reference center, Raymond-Poincaré teaching Hospital, Garches, France

We developed since 2004 a national registry (French Pompe Registry), with the objective to collect prospectively the clinical, paraclinical and biological data of all French patients with a diagnosis of Pompe disease confirmed by enzymatic and/or molecular analysis disease, whether treated or not. This registry has been qualified by French National Committee for Rare Diseases Registries (CNR-MR) supported by INSERM and InVS. Standardized clinical assessments, including muscle strength and pulmonary function tests evaluations, are performed at baseline and every 6 months for all patients treated by enzyme replacement therapy, and yearly for patients who are not treated.

Genetic data from patients with non-classical PD were collected from the two main laboratories involved

in PD diagnosis and from the French Pompe registry. GAA gene sequencing was performed in 204 patients, and 83 different mutations were identified in the GAA gene, among which 28 were novel. The common c.-32-13T > G mutation was detected in 151/170 index cases.

The benefit of ERT has been assessed by analysing the evolution of 6 MWT, VC and Motor Function Measure scale, in 145 patients treated among 32 French centers. A biphasic curve was observed for the results of the 6MWT, with an initial improvement during the 3 years following treatment initiation, followed by a slow decline. Results of VC showed a monophasic curve with a mild decline over time. These data are supporting the results of previous studies showing that ERT helps to slow the progression of PD in adults.

Tendon contractures in Emery-Dreifuss muscular dystrophy: a major involvement of TGF beta 2

Lattanzi G.^{1,2}, Schena E.^{1,2}, Sabatelli P.^{1,2}, Politano L.³, Bernasconi P.⁴, Maggi L.⁴, the Italian Network for Laminopathies

¹ CNR Institute of Molecular Genetics, Unit of Bologna, Bologna, Italy; ² Rizzoli Orthopedic Institute IRCCS, Bologna, Italy; ³ Cardiomyology and Medical Genetics, Department of Experimental Medicine, Campania University "Luigi Vanvitelli" (former denomination: Second University of Naples), Italy; ⁴ Neurology IV - Neuroimmunology and Neuromuscular Diseases Unit, Foundation IRCCS Neurological Institute "Carlo Besta", Milan, Italy

Emery-Dreifuss muscular dystrophy is a rare muscle disease linked to mutations in LMNA or related nuclear envelope genes. Tenocytes represent possible effectors of Emery-Dreifuss Muscular Dystrophy pathogenesis, since contractures of the Achilles tendons and elbows are the first sign of disease in most affected individuals and contractures of the neck are a disabling condition in many patients. We recently demonstrated that elevated TGFbeta 2 serum levels are a molecular signature of muscular laminopathies. Here, we deepened the finding that elevated TGF beta 2 levels interfere with tenocyte differentiation and induce a fibrotic phenotype. It is well established that TGF beta 2 is an inducer of collagen I in tenocytes and the process contributes to differentiation. However, an amount of TGF beta 2 comparable to that observed in patient serum caused a striking increase of the fibrosis marker alpha-SMA in control tenocytes. Moreover, in control tenocytes cultured in the presence of EDMD2 serum, conversion to myofibroblasts was observed. Under these experimental conditions, neutralization of TGF beta 2 by a specific antibody reduced the rate of fibrogenic conversion. Further, the expected increase of the tenocyte differentiation marker

tenomodulin in TGF beta 2-treated control tenocytes was comparable to that elicited by Emery-Dreifuss Muscular Dystrophy serum, suggesting a serum-driven increase in the rate of tenocyte differentiation. The overall evaluation of these results allowed us to conclude that a TGF beta 2-dependent remodeling of tendons occurs in Emery-Dreifuss Muscular Dystrophy, caused by fibrogenic conversion as well as aberrant differentiation of tenocytes.

In vivo studies in tendons are needed to further support the involvement of TGF beta 2 in the onset of tendon contractures and to test the efficacy of neutralizing antibodies in preventing contracture onset in Emery-Dreifuss Muscular Dystrophy.

Gene therapy for Oculopharyngeal muscular dystrophy

Malerba A.¹, Strings-Ufombah V.², Roth F.³, Harbaran S.², Cappellari O.⁴, Lu-Nguyen N.¹, Roelvink P.², Trollet C.³, Suhy D.², Dickson G.¹

¹ Centre of Biomedical Sciences, School of Biological Sciences, Royal Holloway-University of London, Egham, Surrey, UK;

² Benitec Biopharma, Hayward, California, USA; ³ Sorbonne Universités, UPMC Paris, France, Institut de Myologie, Paris, France; ⁴ Comparative Biomedical Sciences, Royal Veterinary College, London, UK

Oculopharyngeal muscular dystrophy (OPMD) is a rare autosomal dominant late onset muscular dystrophy affecting approximately 1:100,000 individuals in Europe. Phenotypically, this muscle disorder is mainly characterized by progressive eyelids drooping (ptosis) and dysphagia although also muscles of the lower limbs can be affected late in life. OPMD is due to a trinucleotide repeat expansion in the polyA binding protein nuclear-1 (PABPN1) gene. Due to this mutation, patients express a protein with 11-17 alanines that is misfolded and prone to form intranuclear inclusions (INIs) which are the hallmark of the disease. Other features of muscles affected by OPMD include fibrosis and muscle atrophy. Currently no pharmacological treatments are available and OPMD patients can only be referred to surgeons for cricopharyngeal myotomy or corrective surgery to extraocular muscles to ease ptosis. We recently tested a new AAV-based gene therapy approach providing complete knock-down of endogenous exp-PABPN1 and its replacement by a wildtype PABPN1 in a mouse model of OPMD. This strategy significantly reduced the amount of insoluble aggregates, decreased muscle fibrosis and reverted the muscle strength to the level of healthy muscles. These results support the application of a gene therapy approach as a novel treatment for OPMD in humans.

Idiopathic inflammatory myopathies: new classification

Milone M.

Mayo Clinic, Rochester MN, USA

Aim of review. The goal of the review is to discuss the recent classification criteria of idiopathic inflammatory myopathies (IIM).

Recent developments. IIM are a heterogeneous group of immune-mediated muscle disorders characterized by muscle weakness, myopathic electromyographic changes, and often elevated serum creatine kinase levels. The pathological hallmark of IIM is the inflammatory exudate in muscle. However, in the past few years, we have learned that immune-mediated myopathies can occur in the absence of inflammatory infiltrates in muscle, as observed in necrotizing autoimmune myopathy (NAM, also called immune-mediated necrotizing myopathy). Therefore, the term idiopathic immune-mediated myopathies (IIMM) better than IIM represents the group of immune-mediated muscle diseases. In addition, the detection of IIMM-associated antibodies, often linked to specific clinical and pathological features, can be crucial in the characterization of a specific IIMM. In light of these new discoveries, the initial classification of inflammatory myopathies, proposed by Bohan and Peter in 1975, has been revised multiple times. Several new classification criteria have been suggested, some based on clinical and pathological features, others focused on clinical and serological findings, but none has been unanimously accepted. Most neurologists, integrating clinical, myopathological and serological profiles, recognize the following subtypes of IIMM: dermatomyositis, inclusion body myositis, NAM, overlap myositis and polymyositis, although the latter seems rare.

Conclusions. Diagnostic criteria and classification of IIMM still require consensus. Muscle biopsy continues to have a crucial role in the diagnosis of IIMM. Additional investigations on the role of IIMM-associated antibodies would further characterize these myopathies.

Early onset peripheral neuropathies: the dark side of the moon

Moroni I.

Department of Pediatric Neurology; IRCCS Foundation, Carlo Besta Neurological Institute, Milan, Italy

The approach to the investigation of the floppy weak infant has recently changed significantly, mostly because of advances in molecular genetic testing; therefore, in the differential diagnosis must be included also early onset peripheral neuropathies. These are rare disorders presenting with heterogeneous clinical phenotypes and caus-

ing variable degree of impairment and disability since infancy, when they can be associated with central nervous system involvement. The inheritance pattern can be autosomal dominant, recessive and X-linked; moreover, children present with relatively more frequent AR or sporadic forms, raising challenges for a precise familial counselling. Electrophysiological studies allow to distinguish different types of neuropathy (demyelinating, intermediate, axonal, distal motor and sensory) and can help addressing specific genetic studies. The clinical clues are characterized by marked hypotonia, predominantly distal weakness and atrophy, absence of deep tendon reflexes, arthrogryposis, foot deformities (pes cavus) and motor delay; cranial nerves involvement, respiratory and swallowing impairment are frequently reported, together with severe progression and disability. De novo dominant mutations in PMP22, MPZ and EGR2 are known to be a typical cause of very early onset hereditary neuropathies with hypomyelination. In addition mutations in several other genes, namely IGHMBP2, TRPV4, DYNC1H1 and BICD2, may lead to similar phenotypes, associated with axonal neuropathies and raising differential diagnosis with spinal muscular atrophy. A significant percentage of hereditary neuropathies at early age still lack a genetic diagnosis, preventing prenatal diagnosis.

New applied technologies in genomic field

Nigro V.

Telethon Institute of Genetics and Medicine (TIGEM) Dipartimento di Medicina di Precisione, Università della Campania "Luigi Vanvitelli"

NGS has revolutionized our approach to genetic diseases, from a single gene testing, to the genome studies. The most important aspects of this revolution derive from the experiences made by pilot programs aimed at clinical and genetic standardized analysis of patients with unsolved genetic conditions.

NGS should be used as an accurate and sustainable strategy to solve undiagnosed diseases and the discovery of new disease genes. The first issue is a network of clinical centers that can provide a detailed annotation of their patients using Phenotips. The second issue is the recruitment of families represented by trio/quartet, since singletons show a limited possibility of proper interpretation. Third, a complete whole exome analysis with a full target 60 - 70 Mb and an even coverage of > 30x in over 98% of sequences: this is important since panels provide limited information and are not comparable, while whole genome sequencing approach may be less cost-effective for most cases. Fourth, optimal bioinformatic analysis data sharing (using Phenome Central or similar) to recognize more patients with the same genetic disease. Fifth, we developed

a next approach for the still negative cases. We designed a “ultra exome” probe collection to be used in connection with the 10x Genomics. This produces a partitioning of high molecular weight DNA fragments (HMW-gDNA) into micelles, along with an adapter molecule and a barcode sequence. With this strategy, WES are fully covered and phased and even small structural variations may be detected.

The floppy infant. Invasive support: when

Pedemonte M.¹, Minetti C.²

¹ UOS Gestione insufficienza respiratoria cronica nelle disabilità complesse; ² UOC Neurologia Pediatrica e Malattie Muscolari, Istituto G. Gaslini, Genova

Improving floppy baby syndrome management has allowed earlier transition out of the paediatric ICU and increasing home discharge.

The aim of this presentation is both a descriptive analysis of paediatric patients requiring a home care program after hospitalization and how the technology evolution has impacted patients' care.

The mortality and the morbidity of neuromuscular patients is related to ventilation necessity, malnutrition and nursing needing.

The palliative care management for children who have a medical condition that is expected to significantly limiting their life expectancy has expanded over the last decade. Some more invasive interventions may be considered including feeding gastrostomy and tracheotomy.

The enteral nutrition is effective in increasing nutrition and requirements and growth. The gastrostomy feeding is well accepted in the context of increasing the child's comfort and improving feeding and nutrition. The enteral tube nutrition in children is useful to avoid further body weight loss, to correct significant nutritional deficiencies, to promote growth and to improve patients' quality of life, and to provide caregiver satisfaction.

Tracheotomy is currently performed for children with upper airway anomalies, for prolonged mechanical ventilation needing, or for significant complex comorbidities such as neurologic impairment or chronic lung disease.

The most common diagnosis requiring the use of home mechanical ventilation is the neuromuscular disease. Particularly, for infants and children requiring prolonged mechanical ventilation, tracheotomy placement is an important step towards hospital discharge.

In conclusion a multidisciplinary care program on disability is mandatory for floppy infant to establish the correct timing of invasive procedures.

Idiopathic inflammatory myopathies necrotizing autoimmune myositis

Peverelli L.

Neuromuscular and Rare Disease Unit, Department of Neuroscience, Foundation IRCCS Ca' Granda Ospedale Maggiore Policlinico, University of Milan, Milan, Italy

Immune-mediated necrotizing myopathy (IMNM) is a type of autoimmune myopathy, recently classified and characterized by severe proximal weakness, myofiber necrosis with minimal inflammatory cell infiltrate on muscle biopsy, and infrequent extra-muscular involvement. Magnetic Resonance Imaging is useful to evaluate whole body muscle involvement, showing that the muscle mainly involved are lateral obturators, glutei, tight central and posterior compartment.

IMNM is mainly linked to two specific antibodies: Anti-signal recognition particle (SRP) and anti-hydroxy-3-methylglutaryl-CoA reductase (HMGCR). The autoimmune myopathies are rare diseases, with a prevalence of just 9-14 cases per 100,000 people and ~ 10% of these have either anti-SRP or anti-HMGCR positivity.

Anti-SRP myopathy patients have more severe muscle involvement and more commonly extra-muscular features. They usually respond best to immunosuppressive regimens than anti-HMGCR. Anti-HMGCR myopathy is often associated with statin exposure. Both anti-SRP and anti-HMGCR myopathy tend to be most severe in younger patients.

Cancer risk in IMNM depends on the disease subtype. Specifically, autoantibody-negative IMNM and HMGCR positive form have been associated with a markedly increased risk of malignancy while anti SRP are rarely link to cancer.

Although clinically severe, IMNM usually respond to a combination of treatments (e.g., high-dose corticosteroids, methotrexate, and IVIG) and rituximab should be limited to non-responsive cases.

The knowledge of IMNM is going to be mandatory between specialist and general practitioners due to the possible increase of cases in the next future in view of the consistently global increase in statin prescriptions.

From evidence to dietary recommendations in NMD

Pini A.¹, Zoni L.², Poli C.², Giannotta M.¹, Santorelli F.³, Filosto M.⁴, Politano L.⁵, Siciliano G.⁶

¹ Child Neurology and Psychiatry Unit, IRCCS Istituto delle Scienze Neurologiche di Bologna; ² Dietological Unit, AUSL di Bologna; ³ Medical Genetics, IRCCS Stella Maris Institute of Pisa; ⁴ Neurological Unit, ASST “Spedali Civili” and University of Brescia; ⁵ Cardiology Institute, II University, Napoli; ⁶ Azienda Ospedaliera Universitaria Pisana, Department of Neurosciences, Pisa; Italy

Background and aims. Neuromuscular diseases (MD) are multisystem disorders which require a multi-

disciplinary approach. Nutritional management regarding swallowing dysfunction and dysphagia, weight control and gastrointestinal dysfunction are the main topics studied. The type of diet and food in the everyday life is not yet defined. Recent studies indicate that an increase of oxidative stress, tissue inflammation, autophagy, membrane instability, are common pathogenetic mechanisms of many NMD. These findings together suggest that in NMD a preservation of the biochemical environment of cells and tissues in the whole organism is important for a good health status, to prevent secondary damage and complement pharmacological, gene and cell therapy. It is believed that nutrition recommendation in NMD are adapted from those for the general health population, but it is to consider that people affected by genetic NMD needs more attention to avoid nutritional deficiencies and are more susceptible to secondary damage. The aim of the study was to delineate if the Mediterranean diet model may represent a dietary habits adapt to NMD on the basis of pathogenetic mechanisms.

Materials and methods. A literature search from year 2006 to year 2017 focused on: 1) pathogenetic mechanisms, 2) therapeutic approaches that contrast inflammation, autophagy, excessive oxidative stress and aging, 3) nutrition, food intake and diet, in the more frequent genetic NMD (Duchenne MD, SMA, FSH muscular dystrophy, Congenital muscular dystrophies and myopathies, Steinert disease) was done.

Results. Antioxidants, polyphenols (histone deacetylase inhibitors), amino acids and essential fatty acids (necessary for membrane cell stability) play a role into the maintenance of a balanced biochemical cell and tissue environment in NMD. Excessive saturated fatty acids (precursors of inflammatory molecules) are damaging. These compounds and their relative proportion may be present in the food assumed in the everyday life as in the Mediterranean diet.

Conclusions. Extreme attention should be paid to the food type to be assumed in every day life in the diet of people affected by NMD. A Mediterranean diet model is recommended in NMD.

Congenital myasthenic syndromes and channelopathies

Rodolico C.

Department of Clinical and Experimental Medicine, University of Messina, Italy

Floppiness/hypotonia is a common neurologic symptom in infancy. A variety of neuromuscular disorders cause floppy infant syndrome, including congenital myasthenic syndromes (CMS) and channelopathies.

CMS are a heterogeneous group of diseases of the neuromuscular junction caused by compromised synaptic transmission. Clinical features include early-onset

weakness of limbs and oculobulbar muscles resulting in hypotonia. In the neonatal period feeding difficulties may be commoner than ptosis. Contractures, a common feature of early onset RAPSN phenotype, may mimic a congenital muscular dystrophy or myopathy. Stridor may be an important clue to CMS, particularly in patients with DOK7 mutations. Acute respiratory events are an important diagnostic clue, not only in the phenotypes associated to episodic apnoea (RAPSN and CHAT), but in severe phenotypes such as COLQ. A CMS should be clinically suspected in newborns sharing these features and electromyographic studies, including repetitive nerve stimulation and single fiber EMG (SFEMG), are necessary to confirm a neuromuscular junction failure and essential to drive molecular analysis and medical treatment.

Skeletal muscle channelopathies are rare genetic neuromuscular disorders that include the nondystrophic myotonias and the primary periodic paralyses (PP). Neonatal hypotonia was reported in PP associated with the SCN4A T704M mutation, in families with paramyotonia congenita carrying the SCN4A I693T mutation and in severe neonatal episodic laryngospasm (SNEL) linked to a G1306E mutation in the SCN4A gene. A correct diagnosis, starting from the clinical suspicion, is crucial, being more of these forms flecainide-responsive.

Muscle contraction and metabolic adaptations: molecular mechanisms

Sandri M.

Department of Biomedical Sciences - Venetian Institute of Molecular Medicine - Myology Center, University of Padova, 35131 Padova, Italy

The cellular basis of age-related tissue deterioration remains largely obscure. The ability to activate compensatory mechanisms in response to environmental stress is an important factor for survival and maintenance of cellular functions. Autophagy is activated both under short and prolonged stress and is required to clear the cell from dysfunctional organelles and altered proteins. The removal of mitochondria via mitophagy requires an efficient mitochondrial shaping machinery. We report that autophagy and mitochondrial dynamics in muscles declines with ageing and that both are reactivated by exercise. Exercise stimulates mitochondrial fusion via the transcription factor TFEB independently of PGC1 α but does not affect autophagy. TFEB induces the expression of genes involved in mitochondrial biogenesis, fatty acid oxidation and oxidative phosphorylation. This coordinated action optimizes mitochondrial substrate utilization, thus enhancing ATP production and exercise capacity. Finally, both fusion and fission when specifically blocked in muscles shorten life span of animals but only OPA1 deletion results in multiple organs senes-

cence. Mitophagy is important to prevent mitochondrial dysfunction and oxidative stress. Mitochondrial dysfunction and oxidative stress directly affect acto-myosin interaction and force generation. Therefore, mitochondrial quality control is activated by exercise and is critical for muscle function and when impaired it systemically reverberates to whole organism affecting animal health and ageing.

Application of NGS techniques in neuromuscular disorders

Santorelli F.M.

U.O.C. di Medicina Molecolare per le Malattie Neurodegenerative e Neurogenetiche, IRCCS Fondazione Stella Maris, Calambrone (PI)

The convergence of scientific capability and technology that generates vast health data at diminishing cost has generated opportunities, challenges, and anticipation surrounding future data-centric healthcare models. Next Generation Sequencing (NGS) technologies are revolutionizing the diagnostic screening for rare disease entities, including skeletal muscle myopathies, muscular dystrophies, and primary mitochondrial disorders. NGS approaches, either as targeted genes panel or a combination of gene panels and whole exome sequencing (WES), are now able to identify the causative gene defects in small families or single individuals. Not only this approach has allowed us to reach molecular diagnosis in a significant fraction (20-30%) of these difficult cases, but it has also revealed unexpected and conceptually new findings that will be presented. Despite its tremendous impact combining NGS with myo/neuroimaging data and clinical phenotyping, however, the diagnostic yield of WES analysis is far from complete offering a solution in about half of the cases for which the test is proposed. Transcriptomics for muscle disorders is considering a promising avenue to “solve the unsolved” but tissue expression is the issue. With increasing numbers of quantitative metabolomic studies and readily available platforms, quantitative metabolomics will sooner or later complement molecular DNA and RNA analysis in diagnostic settings. We will discuss how this can be attained in neuromuscular routine work and how multi-omic approaches can serve to define in full the molecular-genetic diagnosis in the daily clinical practice.

Three-dimensional human iPS cell-derived artificial skeletal muscles for disease modelling and tissue engineering

Maffioletti S.M.¹, Sarcar S.¹, Henderson A.B.H.¹, Mannhardt I.², Pinton L.^{1,3}, Moyle L.A.¹, Steele-Stallard H.^{1,3}, Cappellari O.⁴, Wells K.E.⁴, Ferrari G.¹, Mitchell J.S.^{5,6}, Tyzack G.E.^{5,6}, Kotiadis V.N.¹, Khedr M.¹, Ragazzi M.¹, Wang W.¹, Duchen M.R.¹, Patani R.^{5,6}, Zammit P.S.³, Wells D.J.⁴, Eschenhagen T.², Tedesco F.S.¹

¹ Department of Cell and Developmental Biology, University College London, WC1E 6DE London, UK; ² Department of Experimental Pharmacology and Toxicology, University Medical Center Hamburg Eppendorf (UKE), 20246 Hamburg and DZHK (German Centre for Cardiovascular Research), partner site Hamburg/Kiel/Lübeck, Germany; ³ Randall Centre for Cell and Molecular Biophysics, King's College London, SE1 1UL London, UK; ⁴ Department of Comparative Biomedical Sciences, Royal Veterinary College, NW1 0TU London, UK; ⁵ Institute of Neurology, University College London, WC1N 3BG London, UK; ⁶ The Francis Crick Institute, NW1 1AT London, UK

Artificial human skeletal muscle models would provide an instrumental tool to study pathological mechanisms, test therapeutic strategies and develop tissue replacement protocols. Use of a similar approach in other tissues has proved transformational for drug development and regenerative medicine by means of organoid technology. Additionally, although there is an increasing need to develop clinically-relevant multilineage patient-specific models, no such isogenic human skeletal muscle model has been derived to date. Here, we report the generation of three-dimensional (3D) artificial skeletal muscle tissue from human pluripotent stem cells, including induced pluripotent stem cells (iPSCs) from patients with Duchenne, limb-girdle and congenital muscular dystrophies. Skeletal myogenic differentiation of pluripotent cells was induced within 3D hydrogels under tension to provide unidirectional myofibre alignment. Artificial muscles recapitulated characteristics of human skeletal muscle tissue and could also be implanted into immunodeficient mice. Importantly, pathological cellular hallmarks of incurable forms of severe muscular dystrophy could be modeled in vitro with high fidelity using this 3D platform. Finally, we provide evidence of generation of fully human iPSC-derived, multilineage muscle models containing crucial isogenic cellular constituents of skeletal muscle, such as vascular endothelial cells, pericytes and spinal motor neurons. These results lay the foundation for a human skeletal muscle organoid-like platform for complex disease modeling, regenerative medicine and therapy development.

The Italian Registry for muscle glycogenoses: facts and perspectives

Toscano A.

University of Messina

“Muscle Glycogen Storage Disorders (MGSD)” includes a group of rare diseases due to defects of glycogen metabolism. In the past 15 years, there has been an increasing interest in MGSD but awareness of these conditions as well as ability to diagnose them and manage affected patients has been limited. When dealing with rare diseases, a small population of patients represents the major obstacle to progress in research and management. Consequently, the development of a web-based registry for MGSD patients, has to be considered necessary to better understand frequency, different phenotypes and natural history of patients with muscle glycogenoses.

We have studied the natural history and the epidemiological data of patients coming from 21 Italian Centers with specific expertise on MGSD.

To date, we have already collected over 250 patients with both adulthood and childhood onset of MGSD. The diagnoses were based on biochemical and molecular genetic testing.

The most common forms are represented by GSD II or Pompe disease, followed by GSDV or McArdle disease. In the registry, there are also other rarer MGSD as GSDIII, GSD IV, VII, X, XIII, GSD0. We have highlighted some interesting data as: 1) diagnostic delay was 5,2 yrs in GSD II whereas 15,2 yrs in GSDV; 2) Hyperckemia was elevated in about 50% of patients at onset; 3) the most common symptoms in GSDII were represented by muscle weakness and fatigue whereas in GSDV were exercise intolerance, myalgia and fatigue; 4) myoglobinuria was reported only in 30% of GSDV patients; 5) muscle weakness at onset was reported in 15/72 GSDV patients in the hip muscles.

In conclusions, the analysis of this large cohort of patients has revealed several important informations on the natural history of these disorders. CK abnormal in about 50% of patients suggested that not always it increases in such disorders. Muscle weakness in GSDV was highly

present rather than reported in smaller cohorts. Considerable diagnostic delay was evident, mainly in GSD V, highlighting the need for better awareness and more attention to signs and symptoms characterizing these disorders.

Juvenile dermatomyositis

Rosina S., Ravelli A.

Università degli Studi di Genova and IRCCS Istituto Giannina Gaslini, Genoa, Italy

Juvenile dermatomyositis (JDM) is a multisystem inflammatory disease of unknown etiology that primarily involves the skin and skeletal muscles, but may also affect visceral organs, particularly the bowel and the lung, and is characterized by potentially serious, though largely mysterious, complications, such as dystrophic calcinosis and lipodystrophy. With an incidence of 2.5-4.1 cases per million children in the US and 1.9 cases per million children in the UK, it is a rare illness. However, it accounts for a sizeable percentage of patients seen in pediatric rheumatology clinics due to both its chronicity and potential severity. The onset of JDM is quite variable, with some patients experiencing the insidious development of progressive muscle weakness and skin rash, and others having a more acute onset with fever profound muscle weakness, widespread cutaneous manifestations, and occasionally ulcerative lesions. The disease course is heterogeneous as well, and may range from a monocyclic course, with good response to treatment and full recovery within 2 years after diagnosis without relapse, to a chronic polycyclic or continuous course, with relapsing-remitting disease, or persistently active disease for longer than 2 years after diagnosis. Over the last decades, the advances in the management of JDM, including introduction of biologics agents, have provided novel therapeutic options for use in severe cases and have dramatically decreased the disease-related morbidity and mortality. Recently, there have been several consensus efforts aimed to provide expert advice on the optimal management of JDM and to harmonize the therapeutic approaches internationally.

ABSTRACTS OF ORAL COMMUNICATIONS

(in alphabetical order of the first Author)

OP 1: Congenital Myopathies

Role of muscle biopsy study in the diagnosis of floppy infants

Fiorillo C.¹, Dazzi F.¹, Broda P.¹, Romano C.², Savasta S.³, Falsaperla R.², Donati A.⁴, Pedemonte M.¹, Gazzero E.⁵, Bruno C.⁶, Minetti C.¹

¹ Neurologia Pediatrica e Malattie Muscolari, Istituto G. Gaslini e Università di Genova, Genova; ² Pediatria generale, Ospedale Vittorio Emanuele, Università di Catania, Catania; ³ Dipartimento Materno Infantile, Fondazione IRCCS San Matteo, Pavia; ⁴ Malattie Metaboliche e Muscolari Ereditarie, Ospedale Meyer, Firenze; ⁵ Experimental and Clinical Research Centre, Charité Universitäts Medizin, Berlin; ⁶ Centro di Miologia Traslazionale e Sperimentale, Istituto G. Gaslini, Genova

Hypotonia in infants is a common diagnostic challenge for paediatricians, neurologists and neonatologists. The approach to the investigations of the floppy infant is composite due to the high number of aetiological possibilities. Recognition of specific phenotype is of paramount importance for management and prognosis.

In this work, we want to evaluate the role of skeletal muscle biopsy in the diagnostic work up of children presenting hypotonia in the first year of life.

For this purpose we retrospectively examined the histopathological findings obtained in 122 infants who performed muscle biopsy between years 2006-2016. Patients were divided in neuromuscular hypotonia and complex hypotonia, in case of CNS or other organ involvement or syndromic features. When available, results from neuroradiological and EMG studies were also collected and compared with results.

The indications for which the biopsy were required included: suspected neurogenic disorder (12), suspected congenital myopathy or muscular dystrophy (68), suspected metabolic disorder (42), mostly of mitochondrial origin (30).

Histopathological findings allowed to confirm the clinical question in 6/12 case of neurogenic damage and in a good percentage of congenital myopathies or muscular dystrophies (47/68). Conversely, in the group of possible metabolic/mitochondrial disorders, the diagnostic rate was scarce: 25 biopsies resulted non-specific or normal; in 6 a defect of OXPHOS was documented and in 3 a glycogen storage disease was diagnosed. A final genetic diagnosis was achieved in 26 patients and in all cases was consistent with biopsy findings.

In conclusion, muscle biopsy study albeit considered an invasive procedure, is important to confirm or exclude the clinical suspect and to successfully target the genetic investigations.

Redefining morphological spectrum of RYR1 recessive myopathies

Garibaldi M.^{1,2}, Rendu J.³, Brocard J.³, Lacene E.¹, Brochier G.¹, Beuvin M.⁴, Labasse C.¹, Levy-Borsato F.¹, Madelaine A.¹, Malfatti E.¹, Bevilacqua J.⁵, Lubieniecki F.⁶, Monges S.⁶, Taratuto A.L.⁷, Marty I.³, Antonini G.², Romero N.B.¹
¹ Neuromuscular Morphology Unit, Myology Institute, Groupe Hospitalier Universitaire La Pitié-Salpêtrière, Paris, France; ² Neuromuscular Disease Centre, Sant'Andrea Hospital, Department of Neurology, Mental Health and Sensory Organs (NESMOS), SAPIENZA University of Rome, Italy; ³ Centre Hospitalier Régional Universitaire de Grenoble, Hôpital Michallon, Biochimie Génétique et Moléculaire, Grenoble, France; ⁴ Sorbonne Universités UPMC Univ Paris 06 - Inserm UMR974, Center of Research in Myology, Institut de Myologie, Groupe Hospitalier Pitié-Salpêtrière, Paris, France; ⁵ Neuromuscular Unit, Department of Neurology and Neurosurgery, University of Chile Clinical Hospital (HCUCH), Santiago, Chile; ⁶ Servicio de Neurología y Servicio de Patología, Hospital de Pediatría Garrahan, Buenos Aires, Argentina; ⁷ Neuropathology, Foundation for Neurological Research (FLENI), Buenos Aires, Argentina

The RYR1 gene encodes the ryanodine receptor1, a Ca²⁺ channel expressed on sarcoplasmic reticulum membranes at the triad junction of skeletal muscle fibres. Dominant mutations lead to CCD and MHS phenotypes whereas recessives manifest with a wide range of clinical and morphological presentation. We present a monocentric revision of muscle biopsies from more than 50 genetically confirmed RYR1 recessive patients. We performed histological, immunohistochemical and ultrastructural analysis of 58 muscle biopsies from 53 patients. Moreover, levels of RyR1 expression in muscle biopsies have been assessed by Western Blot (WB) and its pertinence with genetics background, clinical severity and morphological findings has been investigated.

By optic microscopy, 10 muscle biopsies showed typical cores (single or multiple, central or eccentric) and 6 core and rods association in the same biopsy. Five biopsies showed isolated type1 uniformity/predominance with or without mild myofibrillar disorganization. Most of muscle biopsies presented a unique histological feature characterized by association of irregular myofibrillar disorganization, granular cytoplasmic material deposition, type1 fiber predominance and nuclear internalization and centralization. In rare cases these findings were observed just in few muscle fibers. One third of these cases the myofibrillar pathway presented a targetoid appearance by oxidative stains in variable number of fibers. In one case both the latter histological presentation and cores were simultaneously present.

By electron microscopy, typical cores, core and rods and the biopsies showing the peculiar features, presented areas of myofibrillar disorganization ranging from few sarcomeres to more than 50 sarcomeres of variable width sometimes occupying almost the entire muscle fiber. Areas of disorganization contained variable degree of osmophilic dense filamentous material deposition (possibly corresponding to granular material by optic microscopy) and disorganized thickened z-line fragments.

WB analysis on muscle biopsies revealed a constant reduction of RYR1. The percentage of reduction seems to be more pronounced in more severe clinical cases and in patients showing the peculiar morphological phenotype compared to isolated type1 prevalence/uniformity or typical CCD/core and rod.

Novel phenotypes of congenital myopathies: importance of the ultrastructural electron microscopy study

Malfatti E.^{1,2,3}, Bohm J.⁴, Lornage X.⁴, Chartner V., Brochier G.³, Madeline A.¹, Labasse C.¹, Fardeau M.¹, Laporte J., Romero N.B.^{1,2,3}

¹ Unité de Morphologie Neuromusculaire, Institut de Myologie, Groupe Hospitalier Universitaire La Pitié-Salpêtrière; Paris, France; ² Sorbonne Universités, UPMC Univ Paris 06, INSERM UMR5974, CNRS FRE3617, Center for Research in Myology, GH Pitié-Salpêtrière, 47 Boulevard de l'hôpital, 75013 Paris, France; ³ Centre de référence de Pathologie Neuromusculaire Paris-Est, Institut de Myologie, GHU La Pitié-Salpêtrière, Assistance Publique-Hôpitaux de Paris; Paris, France; ⁴ Dpt Translational Medicine, IGBMC, Illkirch, France; ⁵ APHP, Service d'Imagerie Médicale, Pôle Neuro-locomoteur, Hôpital Universitaire Raymond Poincaré, Garches, France

Congenital myopathies are a heterogeneous group of genetic neuromuscular disorders defined on the morphological histopathologic lesions/alterations observed in patients muscle biopsies. The most frequent lesions are protein inclusions such as nemaline bodies (rods), altered organization of the myofibrillar structure like cores lesions, or abnormally increased nuclear internalization. Histochemical and electron microscopy studies allowed a thorough pathologic description and characterization, allowing the creation of homogenous cohorts of patients for genetic studies. The first genetic causes of congenital myopathies have been identified through linkage analysis or gene-by-gene Sanger sequencing. In the last ten years, massive parallel sequencing (Next Generation Sequencing, NGS) contributed to the identification of novel forms of disease. The French ANR (Agence Nationale de la Recherche) funded research project MYOLINE, applied NGS to more than 300 patients with congenital myopathies and led to the identification of 5 new genes (unconventional myosin MYO18B, myopalladin MYPN, Ca²⁺ + channel CACNA1S/DHPR, oxidoreductase PYROXD1, and kinase ZAK) associated with different congenital myopathies. In our presentation, we will describe the most relevant clinical and morphological characteristics of these patients highlighting the role of electron microscopy in the diagnostic algorithm and functional validation of the novel identified genes.

Wes analysis identified MSTO1 as novel disease gene in two families with 3 patients presenting a complex phenotype characterized by congenital myopathy and ataxia

Neri M.¹, Nasca A.², Scotton C.¹, Zaharieva I.³, Selvatici R.¹, Magnusson O.T.⁴, Gal A.⁵, Kiriko G.⁵, Weaver D.⁵, Rossi R.¹, Armadori A.¹, Pane M.⁶, Cecconi A.⁷, Sewry C.³, Phadke R.³, Feng L.³, Donati A.⁸, Mercuri E.⁶, Zeviani M.⁹, Muntoni F.³, Ghezzi D.², Ferlini A.^{1,3}

¹ Medical Genetics Unit, Department of Medical Sciences, University of Ferrara, Ferrara, Italy; ² Molecular Neurogenetics Unit, Foundation IRCCS Neurological Institute Besta, Milan, Italy; ³ UCL Great Ormond Street Institute of Child Health, London UK; ⁴ deCODE Genetics, Reykjavik, Iceland; ⁵ MitoCare Center for Mitochondrial Imaging Research and Diagnostics, Department of Pathology, Anatomy and Cell Biology, Thomas Jefferson University, Philadelphia, PA, USA; ⁶ Neuropsychiatry Unit, Catholic University, Policlinico Gemelli, Rome, Italy; ⁷ Pediatrics Medical Genetics, Hospital S. Maria Annunziata, Florence, Italy; ⁸ Unit of Metabolic and Muscular Diseases, Meyer Children Hospital, Florence, Italy; ⁹ Mitochondrial Biology Unit - MRC, Cambridge, UK

We studied by WES a family of four with healthy parents

and two affected sisters who presented a multisystem complex phenotype mainly characterized by congenital myopathy and cerebellar ataxia. We identified in both patients two mutations in the MSTO1 gene: (c.1033C > T and c.1128C > A). A singleton case in an unrelated family showed a similar neuromuscular phenotype and WES analysis identified also in this patient two mutations in the MSTO1 gene (c.971C > T and c.996+1G > A).

Segregation analysis in the families revealed that parents were heterozygotes for the mutations. Human MSTO1 is a poorly studied protein; it has been suggested to encode a mitochondrial protein regulating morphology and distribution of mitochondria. As for other mutations affecting genes involved in mitochondrial dynamics, no biochemical defects typical of mitochondrial disorders were reported. We performed studies in patients' fibroblasts which revealed that MSTO1 protein levels were strongly reduced; moreover the mitochondrial network was fragmented and the fusion events among mitochondria were decreased, confirming the deleterious effect of the identified variants and the role of MSTO1 in modulating mitochondrial dynamics. We also found that MSTO1 is mainly a cytosolic protein. These findings indicate recessive mutations in MSTO1 as a new cause for inherited neuromuscular disorders with multisystem features.

Clinical characterization of an Italian cohort of patients with early-onset LMNA-related myopathy

Ricci G.¹, Fiorillo C.², D'Amico A.³, Astrea G.⁴, Rodolico C.⁵, Vercelli L.⁶, Mongini T.⁶, Semplicini C.⁷, Pegoraro E.⁷, Politano L.⁸, Mercuri E.⁹, Benedetti S.¹⁰, Berardinelli A.¹¹, Previtali S.¹², Carboni N.¹³, Marrosu G.¹⁴, Bertini E.³, Siciliano G.¹, Lattanzi G.¹⁵, Maggi L.¹⁴, Italian Network for Laminopathies

¹ Department of Clinical and Experimental Medicine, University of Pisa, Pisa, Italy; ² Paediatric Neurology and Muscular Diseases Unit, University of Genoa and G. Gaslini Institute, Genoa, Italy; ³ Unit of Muscular and Neurodegenerative Diseases, Bambino Gesù Children's Hospital, Rome, Italy; ⁴ IRCCS Fondazione Stella Maris, Pisa, Italy; ⁵ Department of Clinical and Experimental Medicine, University of Messina, Messina, Italy; ⁶ Neuromuscular Unit, Department of Neurosciences, Rita Levi Montalcini, University of Torino, Torino, Italy; ⁷ Neuromuscular Center, Dipartimento di Neuroscienze, Università di Padova, Padova, Italy; ⁸ Department of Experimental Medicine, Cardiology and Medical Genetics, University of Campania "Luigi Vanvitelli", Naples, Italy; ⁹ Department of Pediatric Neurology, Catholic University and Nemo Roma Center for Neuromuscular Disorders, Rome, Italy; ¹⁰ Laboratory of Molecular Biology, San Raffaele Institute, Milan, Italy; ¹¹ Child Neuropsychiatry Unit, Department of Brain and Behavioral Sciences, University of Pavia, Italy; ¹² Department of Neurology, San Raffaele Scientific Institute, Milan, Italy; ¹³ Neurology Department, Hospital San Francesco di Nuoro, Italy; ¹⁴ ASL8, Centro Sclerosi Multipla, Cagliari, Italy; ¹⁵ CNR Institute of Molecular Genetics, Unit of Bologna, Rizzoli Orthopedic Institute, Bologna, Italy; ¹⁶ Neurology IV - Neuroimmunology and Neuromuscular Diseases Unit, IRCCS "Carlo Besta" Institute, Milan, Italy

Laminopathies are rare diseases caused by heterozygous mutations in LMNA gene, associated with a wide range of phenotypes, often associated with heart involvement, including limb-girdle muscular dystrophy type 1B (LGMD1B), autosomal dominant Emery-Dreifuss muscular dystrophy (EDMD2), and a form of congenital muscular dystrophy, (LMNA-CMD). Around a half of patients with skeletal muscle involvement due

to LMNA mutations present in the first decade of life. Among them LMNA-CMD show selective axial muscle weakness and wasting or a severe generalized phenotype; talipes feet and a rigid spine with thoracic lordosis develop early. Proximal contractures appear later, most often in lower limbs and respiratory failure is frequent. Of note, muscle biopsy often reveals dystrophic features and inflammatory findings. Cases of EDMD2 with early onset may be considered a continuum with LMNA-CMD phenotype. Poor data on the congenital and childhood onset forms of LMNA-related myopathies have been reported. Here, we present an Italian cohort of 45 patients with LMNA-related muscle diseases with early onset (< 5 years), aiming to describe the natural history; the mean age at evaluation was 29.2 ± 17.3 years. Among them, we included 29 (64.4%) LMNA-CMD, then developing LGMD1B or EDMD2 phenotype only in about 60% of the cases, 11 (24.5%) LGMD1B, 7 (15.6%) EDMD2, and 2 (4.5%) cases with atypical phenotype. Heart involvement was observed in 21 out of 45 (46.7%) patients.

OP 2: Metabolic Diseases

Glycogenosis VII with early fixed myopathy: a clinical and MRI study

Cotti Piccinelli S.¹, Pichiechio A.², Musumeci O.³, Marchesi M.¹, Caria F.¹, Gallo Cassarino S.¹, Baldelli E.¹, Galvagni A.¹, Toscano A.³, Padovani A.¹, Filosto M.¹

¹ ERN EURO-NMD Center for Neuromuscular Diseases, Unit of Neurology, ASST "Spedali Civili" and University of Brescia, Brescia, Italy; ² IRCCS, 'C. Mondino' National Neurological Institute, Pavia, Italy; ³ Department of Clinical and Experimental Medicine, University of Messina, Italy

Glycogenosis VII (GSD VII) is a very rare autosomal recessive glycogen storage disorder caused by mutations in the PFKM gene encoding the PFK enzyme. Affected patients usually present with exercise intolerance and myoglobinuria. Only rarely an infantile form with hypotonia, progressive myopathy, cardiomyopathy, respiratory failure and early death, a late-onset form with fixed proximal weakness and a form with hemolytic anemia were described.

We report a 65-year-old man complaining of progressive proximal muscle weakness since childhood associated with exercise intolerance and myoglobinuria. He received a diagnosis of GSD VII at age 43 by muscle biopsy and biochemical assay. In the next years he developed gait impairment with need of walking aids and wheelchair for long distances.

Present clinical examination shows muscle weakness and atrophy mainly affecting lower limbs, both in the proximal and, to a lesser extent, distal regions. Genetic analysis showed the pathogenic c.488 G > A and c.1817 A > C mutations on PFKM gene.

Lower limb muscle MRI showed complete adipose substitution of both anterior and posterior thigh muscles, with selective sparing of the medial ones, and diffuse involvement of the leg muscles less pronounced in the soleus and tibialis anterior muscles. A homogeneous STIR hyperintensity was also associated. Shoulder girdle MRI study showed minimal adipose involvement of the deltoid muscles, while face muscles were spared.

Our study reports on clinical and muscle MRI findings in an atypical GSD VII case characterized by early fixed myopathy and suggests that fixed myopathy can be a feature of infantile-onset benign GSD VII.

A GMPPB mutation causing paucisymptomatic hyperckemia in an adult patient

Gallo Cassarino S.¹, Galvagni A.¹, Lanzi G.², Cotti Piccinelli S.¹, Marchesi M.¹, Caria F.¹, Baldelli E.¹, Giliani S.², Padovani A.¹, Filosto M.¹

¹ ERN EURO-NMD Center for Neuromuscular Diseases, Unit of Neurology, ASST "Spedali Civili" and University of Brescia, Brescia, Italy; ² Institute of Molecular Medicine A. Nocivelli, ASST "Spedali Civili" and University of Brescia, Brescia, Italy

Alpha-dystroglycanopathy (DGP) encompasses a group of congenital and limb girdle-type muscular dystrophies caused by abnormal glycosylation of alpha-dystroglycan. Currently, around 15 genes are involved in DGP.

We here report a 42-year-old woman presenting, since age 38, with moderate hyperCKemia (max value 993 IU/L). No muscular symptoms, except for sporadic exercise-related muscle pain in the thighs, were reported. Neurological examination was normal. The 16-year-old daughter is suffering from a myoclonic epilepsy since childhood.

Muscle biopsy showed minimal non-specific myopathic findings i.e. isolated atrophic fibers, some fibers with internal nuclei and isolated fiber degeneration. Immunohistochemical study for dystrophin, sarcoglycans, caveolin-3, dysferlin and merosin was normal. Immunohistochemical studies with antibodies against alpha-dystroglycan showed no immunoreactivity.

NGS study identified the exon 8 missense homozygote alteration c.[860G > A]; p. [R287Q] having low allelic frequency (0.0002155 ExAC) in the GMPPB gene encoding the beta subunit GDP-mannose pyrophosphorylase that catalyzes the conversion of mannose-1-phosphate and GTP to inorganic diphosphate and GDP-mannose. GDP-mannose is required in O-mannosylation of membranes and secretory glycoproteins such as alpha-dystroglycan.

The variant has been reported in the literature in compound heterozygosity associated with the congenital muscular dystrophy with mental retardation type B 14 and with a congenital muscular dystrophy with generalized epilepsy. The same codon mutation R287W was reported in a 48-year-old woman with features of congenital myasthenic syndrome, in compound heterozygosity with D27H.

Our study suggests that mutations in GMPPB may have a more heterogeneous phenotype than previously known and should be sought in adult patients with pauci- or asymptomatic hyperCKemia.

Vacuolar lipid storage myopathies responsive to riboflavin

Lupica A., Musumeci O., Rodolico C., Brizzi T., Ciranni A., Arrigo R., Volta S., Vita G., Toscano A.

Department of Clinical and Experimental Medicine, University of Messina, Messina, Italy

Lipid storage myopathies are a large group of metabolic disorders characterized by exercise intolerance, muscle weakness and lipids accumulation in myofibers. Among these disorders, multiple acyl-CoA dehydrogenase deficiency is the most common form. Patients with this type may benefit from riboflavin supplementation.

We report clinical, biochemical and morphological aspects of 13 patients with lipid storage myopathy and a very good response to riboflavin treatment.

13 unrelated patients (4 female and 9 male) with no family history of neuromuscular disorders, came to our department complaining of progressive fatigue, dysphonia, dysphagia and muscle weakness. All patients underwent EMG, laboratory blood tests and muscle biopsy. EMG showed variable results with normal,

myogenic or neurogenic patterns. Laboratory blood tests revealed variable increase of serum CK (400 to 20000) and LDH levels (600 to 1400). Plasma acylcarnitine profile showed increasing of short medium and long chains intermediates.

Muscle biopsies in all patients showed a vacuolar myopathy with lipid storage. Patients were treated with high doses of riboflavin and all of them showed a rapid muscle strength improvement and laboratory tests normalization.

Our cases suggest that in patients with a subacute onset of muscle weakness a lipid storage myopathy should be considered in the differential diagnosis because its prompt recognition will allow to start an adequate treatment with a good prognosis.

Dietary treatment for McArdle's disease: real promise or illusion?

The rationale for a multicenter RCT

Martinuzzi A.¹, Vavla M.¹, Stefan C.¹, Trevisi E.¹, Siciliano G.², Ricci G.², Toscano A.³, Musumeci O.³

¹ IRCCS Medea Polo Regionale Veneto; ² Dipartimento di Medicina Clinica e Sperimentale, Università di Pisa; ³ Centro di Riferimento regionale per le Malattie Neuromuscolari rare, Dipartimento di Medicina Clinica e Sperimentale, Università di Messina

McArdle disease (MCA), the most common of the muscle glycogenoses, lacks not only an effective therapy, but also evidence based indications on the best dietary regimen. For years, based on a single paper with unclear design and questionable conclusions, clinicians advised patients to stick to a high protein diet. A subsequent work by the Danish group showed that high carbohydrate diet was superior to high protein, and a third paper demonstrated that lipid overload would be of no benefit. The idea of providing the working muscle with acetyl CoA source alternative to pyruvic acid has been on stage for many years, but to no advantage in terms of effective proven indications. Ketogenic diet (KD) as the potential for fulfilling this task. Many patients on the web are sharing their experiences with KD, but there is no firm objective evaluation of the actual tolerance and effectiveness. We evaluated the exercise capacity of 3 MCA patients following KD compared to a matched group of 6 patients following ad-libitum diet. Mean peak VO₂ was 18.25 ± 2.42 in the controls and 23.7 ± 5.4 in the KD group. For 2 of them we could also show improvement in peak VO₂ comparing performance pre and post diet. These preliminary evaluations indicate the need for an appropriately designed RCT testing the tolerability and effectiveness of KD in a larger MCA group of patients. To this end a multicenter RCT has been designed and will start in Conegliano Pisa and Messina with the support of the Italian Association for Glycogenoses.

Ultrasound for assessment of diaphragm function in late-onset Pompe disease

Musumeci O.¹, Ruggeri P.², Lo Monaco L.², Gaeta M.², Arrigo R.¹, Caramori S.G.², Toscano A.¹

¹ Department of Clinical and Experimental Medicine; ² Department of Biomedical Science and Morphological and Functional Images, University of Messina, Messina Italy

Background. Respiratory dysfunction is one of the main clinical aspects in LOPD patients and is predominantly due to diaphragm weakness. Diaphragm ultrasound (DUS) is a relative recent technique already validated as reproducible and valuable tool to assess diaphragm dysfunction in severe respiratory disorders. Few studies have investigated DUS in different neuromuscular disorders with respiratory impairment.

Aim. To evaluate the correlation between diaphragm thickness and mobility assessed by ultrasound and classical pulmonary function tests (PFTs) in patients with late-onset pompe disease (LOPD).

Methods. 17 LOPD patients (M/F ratio: 9/8) were studied comparing classical PFTs with diaphragm thickness and mobility measured by ultrasound.

Results. The mean age was 46.7 ± 4.7 yrs and with a mean disease duration of 12.3 ± 8.5 yrs. Ultrasound studies of diaphragm thickness in full inspiration correlated with maximal inspiratory pressure (MIP) (r = 0,69; p = 0,004) and maximal expiratory pressure (r = 0,57; p = 0,024), forced expiratory volume in one second (FEV1) (r = 0,59; p = 0,016), forced vital capacity (FVC) both in seated (r = 0,70; p = 0,002) and supine position (r = 0,63; p = 0,026). Diaphragm thickness at functional residual capacity correlated with maximal expiratory pressure (r = 0,58; p = 0,021) and seated FVC (r = 0,57; p = 0,021). Diaphragm thickening fraction correlated with MIP (r = 0,80; p = 0,0003), seated (r = 0,68; p = 0,003) and supine FEV1 (r = 0,65; p = 0,020), seated (r = 0,66; p = 0,005) and supine FVC (r = 0,61; p = 0,034).

Conclusions. Diaphragmatic function assessed by ultrasound is a simple, non invasive tool that correlates significantly with classical PFTs in patients with LOPD. Our results suggest its possible use to assess respiratory impairment at the time of diagnosis and also during the clinical follow-up.

OP 3: Therapies 1

A retrospective study of respiratory function in the Italian Duchenne muscular dystrophy Network

Bello L.¹, Villa M.¹, Gandossini S.², D'Angelo G.², Magri F.³, Comi G.P.³, Pedemonte M.⁴, Tacchetti P.⁴, Lanzillotta V.⁴, Bruno C.⁴, D'Amico A.⁵, Bertini E.⁵, Astrea G.⁶, Politano L.⁷, Baranello G.⁸, Albamonte E.⁹, De Mattia E.⁹, Rao F.⁹, Sansone V.⁹, Previtali S.¹⁰, Messina S.¹¹, Vita G.L.¹¹, Berardinelli A.¹², Mongini T.¹³, Pane M.¹⁴, Mercuri E.¹⁴, Vianello A.¹⁵, Pegoraro E.¹

¹ Department of Neurosciences DNS, University of Padova, Padova, Italy; ² IRCCS Eugenio Medea, Bosio Parini, Italy; ³ Dino Ferrari Centre, Neuroscience Section, Department of Pathophysiology and Transplantation (DEPT), University of Milan, Neurology Unit, IRCCS Foudation, Ca' Granda Ospedale Maggiore Policlinico, Milan, Italy; ⁴ Center of Myology and Neurodegenerative Disorders and Physical and Rehabilitation Medicine Unit, Istituto Giannina Gaslini, Genova, Italy; ⁵ Unit of Neuromuscular and Neurodegenerative Disorders, Bambino Gesù Children's Hospital, Rome, Italy; ⁶ Department of Developmental Neuroscience, IRCCS Stella Maris, Calambrone, Pisa, Italy; ⁷ Cardiology and Medical Genetics, Department of Experimental Medicine, "Vanvitelli" University of Campania, Naples, Italy; ⁸ Pediatric Neurology and Myopathology Units, Neurological Institute Carlo Besta, Milan, Italy; ⁹ Centro Clinico NeMO, Milan, Italy; ¹⁰ Neuromuscular repair unit, Insepe and division of neuroscience, IRCCS San Raffaele Scientific Institute, Milan, Italy; ¹¹ Department of Neurosciences and Nemo Sud Clinical Center, University of Messina, Messina, Italy; ¹² Child Neurology and Psychiatry Unit, "C. Mondino" Foundation, Pavia, Italy; ¹³ Child Neurology and Psychiatry Unit, Catholic University of the Sacred Heart, and Nemo Center, Fondazione Policlinico Gemelli, Rome, Italy; ¹⁴ Neuromuscular Center, AOU Città della Salute e della Scienza, University of Torino, Turin, Italy; ¹⁵ Department of Cardio-Thoracic, Respiratory Pathophysiology Division, University-City Hospital of Padova, Padova, Italy

Respiratory insufficiency is a major cause of morbidity and

mortality in Duchenne muscular dystrophy (DMD). We aimed to define its rate of progression in a large retrospective cohort of Italian DMD patients. We collected retrospective functional respiratory data including forced vital capacity (FVC), forced expiratory volume in 1 second (FEV1), and peak expiratory flow (PEF) from 2526 functional respiratory evaluations (standard spirometry) performed in 358 DMD patients from the age of 3 to 47. We observed a gradual reduction in mean values of FVC, FEV1, and PEF, starting from the age of 7 years, with a co-linear progression up to the age of 24 years. Using a generalized estimating equation approach, which is appropriate for data including "clusters" of several evaluations from the same individuals, we estimated the yearly rate of decrease in this age range to be -4.8% for FVC, -5.2% for FEV1, and -3.7% for PEF. Future developments include further expansion of the database, and analyses of factors influencing respiratory function, such as glucocorticoid treatment, different DMD mutations, and modifier genotypes.

Pulmonary function in patients with advanced Duchenne muscular dystrophy: eteplirsen-treated patients compared with multiple natural history cohorts

Gordish-Dressman H.¹, Henricson E.², Khan N.³, Han L.³, Dugar A.³, McDonald C.M.², CINRG DNHS Investigators

¹ George Washington University School of Medicine and Health Sciences, Washington, DC, USA; ² University of California Davis, Davis, CA, USA; ³ Sarepta Therapeutics, Inc., Cambridge, MA, USA

Objective. Eteplirsen is approved in the US for treatment of Duchenne muscular dystrophy (DMD) patients with genetic mutations amenable to exon 51 skipping. We evaluated pulmonary function data from advanced DMD patients in a phase 2, open-label study and in multiple CINRG Duchenne Natural History Study (CINRG DNHS) cohorts.

Methods. Eteplirsen Study 204: Eligible males aged 7-21 years with advanced DMD received once-weekly intravenous eteplirsen 30 mg/kg for 96 weeks. Pulmonary function (predefined exploratory outcome) was assessed by mean change from baseline in percent predicted forced vital capacity (FVC% p). **Change from baseline analysis.** FVC% p outcomes were evaluated in eteplirsen-treated patients and a CINRG DNHS cohort aged 8-19 years receiving standard of care treatment with glucocorticoids. Longitudinal age-based analysis: Annual change in FVC% p was evaluated in eteplirsen-treated patients and 3 CINRG DNHS cohorts (All CINRG; Genotyped CINRG; CINRG Exon 51) aged 10 ≤ 18 years, where a linear phase of decline is expected.

Results. Change from baseline analysis: Eteplirsen-treated patients (n=23) had a mean change from baseline in FVC% p of -6.4 at Year 1 and a mean change in FVC% p from Year 1 to Year 2 of -0.5 . The CINRG cohort (n = 10) had a mean change in FVC% p of -8.2 over 1 year. Age-based longitudinal analysis: Annual rate of FVC% p change was significantly lower in eteplirsen-treated patients (-3.66 ; n = 20) versus all other cohorts (All CINRG: -5.56 ; n = 172; Genotyped CINRG: -5.67 ; n = 148; CINRG Exon 51: -6.00 ; n = 20).

Conclusions. Eteplirsen significantly attenuated FVC% p decline in DMD patients compared with well-matched, steroid-treated natural history cohorts.

Funding statement. This study was funded by Sarepta Therapeutics, Inc.

Disclosures. Heather Gordish-Dressman: has no conflicts to disclose. Erik Henricson: consultant for Sarepta Therapeutics, Inc. Lixin Han: employee of Sarepta Therapeutics, Inc. Ashish Dugar: employee of Sarepta Therapeutics, Inc. Craig M. McDonald: has served as a consultant for clinical trials for BioMarin, Cardero Therapeutics, Catabasis, Eli Lilly, Halo Therapeutics, Marathon, Mitokyne Pfizer, PTC Therapeutics, Santhera Pharmaceuticals, and Sarepta Therapeutics, Inc.; serves on advisory boards for Eli Lilly, Mitokyne, Marathon, PTC Therapeutics, and Sarepta Therapeutics, Inc.; and has received research grants from the US Department of Education/National Institute on Disability and Rehabilitation Research (NIDRR), the National Institute on Disability, Independent Living, and Rehabilitation Research (NIDILRR), the US National Institutes of Health/National Institute of Arthritis and Musculoskeletal and Skin Diseases, the US Department of Defense, and the US Parent Project Muscular Dystrophy.

Rituximab for immunosuppressant resistant inflammatory myopathies: a single center case series and literature review

Lucchini M., De Fino C., Monforte M., Primiano G.A., Ricci E., Servidei S., Mirabella M.

Institute of Neurology, Università Cattolica del Sacro Cuore, Fondazione Policlinico Gemelli Roma

Inflammatory myopathies are a group of myopathies characterized by acute/subacute proximal weakness, increased levels of creatine-kinase and inflammatory infiltrates on muscle biopsy. Standard therapy is represented by high-dose steroids (1 mg/kg of prednisone) associated with immunosuppressants (including azathioprine, cyclosporine, cyclophosphamide, mycophenolate and methotrexate). The choice of the specific immunosuppressant depends both on patient's comorbidities and clinician experience. If, after appropriate immunosuppressive therapy, patient experiences worsening or no improvement, another immunosuppressive drug can be attempted often with unsuccessful results. We present four cases of patients with inflammatory myopathy refractory to corticosteroids and immunosuppressants successfully treated with rituximab. All four patients were MSA-positive, respectively two with anti-SRP-positive autoimmune necrotizing myositis and two dermatomyositis, one anti-Jo1 and one anti-NXP2-positive. After high-dose steroid and immunosuppressive treatments all patients experienced new clinical worsening that required therapy change. We treated all patients with rituximab: two infusions of 1 g every 15 days. After 6 months patients showed improvement of proximal muscle weakness and reduction or normalization of CK levels; it was also possible to significantly reduce steroid dosage (more than 50%) and/or suspend immunosuppressant drugs. In three cases we repeated Rituximab infusion because of a new clinical worsening after a median of 17,3 months. rituximab was tested in a single large phase III trial in refractory myositis. Although primary endpoint was not met, 83% of patients improved. Several case series also reported optimal response to rituximab outlining the role of B-cell-depleting therapy in myositis. Our experience confirms the efficacy of rituximab in treatment-refractory forms of myositis.

The Becker muscular dystrophy cohort in the Givinostat trial: clinical characterization and functional measures

Magri F.¹, Velardo D.¹, Govoni A.¹, Cinnante C.², Peverelli L.³, Cazzaniga S.⁴, Bello L.⁵, Brusa R.¹, Semplicini C.⁵, D'Angelo M.G.⁶, Gandossini S.⁶, Filosto M.⁷, Sansone V.⁸, Previtali S.⁹, Pegoraro E.⁵, Corti S.¹, Moggio M.³, Bresolin N.¹, Bettica P.⁴, Comi G.P.¹

¹ Dino Ferrari Centre, Neuroscience Section, Department of Pathophysiology and Transplantation, Neurology Unit, IRCCS Foundation Ca' Granda Ospedale Maggiore Policlinico, University of Milan, Milan; ² U.O. Neuroradiologia, I.R.C.C.S. Foundation Ca' Granda, Ospedale Maggiore Policlinico, Milan, Italy; ³ Neuromuscular and Rare Disease Unit, Department of Neuroscience, Foundation IRCCS Ca' Granda Ospedale Maggiore e Policlinico, Dino Ferrari Centre, University of Milan, Milan; ⁴ Italfarmaco S.p.A., Italy; ⁵ Department of Neurosciences, University of Padua, Padua; ⁶ NeuroMuscular Unit-IRCCS E Medea Bosisio Parini, Bosisio Parini (Lecco); ⁷ Center for Neuromuscular Diseases and Neuropathies, Unit of Neurology ASST "Spedali Civili", University of Brescia, Brescia, Italy; ⁸ NEuroMuscular Omnicentre (NEMO), Serena Onlus Foundation, Milano; ⁹ INSPE and Division of Neuroscience, IRCCS San Raffaele Scientific Institute, Milan, Italy

In recent years several experimental therapies have been tested in Duchenne Muscular Dystrophy, while Becker Muscular Dystrophy (BMD) has not received comparable attention. In fact the high clinical heterogeneity and slower progression of BMD make selecting patients' homogeneous cohorts and defining valid outcome measures challenging.

Givinostat, a histone deacetylase inhibitor, will be tested in a phase II clinical trial in BMD patients. Subjects will need to be ambulant (values at 6-minute walking test – 6MWT – between 200 and 450 meters) with preserved cardiac function. The clinical study is still recruiting.

In this perspective we screened a population of 74 molecularly diagnosed BMD patients. 41 patients did not meet the inclusion criteria due to cardiac involvement (n = 9), ambulatory status (10 were non ambulant, 2 walked less than 200 meters at 6MWT, 13 more than 450 meters), age (n = 5), concomitant pathologies (n = 2). In the patients included in the trial we performed functional assessments, muscle biopsy and muscle magnetic resonance imaging (MRI). Patients ranged from milder to more severe cases and showed different age of disease onset (4-32 years of age). MRI study showed specific pattern and helped selecting more useful muscles for patient's follow-up.

Overall this study confirms the high clinical heterogeneity of BMD and the difficulty to obtain homogeneous cohorts for clinical trials. It will help in clarifying the parameters that should be used as outcome measures to better define the effect of new experimental therapies.

Golodirsén induces exon skipping leading to sarcolemmal dystrophin expression in patients with genetic mutations amenable to exon 53 skipping

Mercuri E.¹, Frank D.E.², Servais L.³, Straub V.⁴, Morgan J.⁵, Domingos J.⁵, Schnell F.², Dickson G.⁶, Popplewell L.⁶, Seferian A.³, Monforte M.¹, Guglieri M.⁴, Muntoni F.^{5,7}, the SKIP-NMD Study Group

¹ Catholic University of the Sacred Heart, Rome, Italy; ² Sarepta Therapeutics, Inc., Cambridge, MA; ³ Institute of Myology, Paris, France; ⁴ Newcastle University and Royal Victoria Infirmary Hospital, Newcastle upon Tyne, UK; ⁵ University College London, London, UK; ⁶ Royal Holloway, University of London, London, UK; ⁷ Great Ormond Street Hospital, London, UK

Objective. A 2-part, first-in-human, multicenter study is evaluating the phosphorodiamidate morpholino oligomer (PMO) golodirsén in patients with Duchenne muscular dystrophy (DMD) and genetic mutations amenable to exon 53 skipping. We report key biologic outcomes at baseline and week 48 of golodirsén treatment.

Methods. Part 1 (completed) was a randomized, double-blind, placebo-controlled, 12-week dose escalation. Part 2 (ongoing) is a 168-week open-label evaluation of once-weekly golodirsén 30 mg/kg. Per protocol, patients had paired muscle biopsies of the biceps brachii at baseline and following 48 weeks of once-weekly treatment with golodirsén. Exon 53 skipping was evaluated using reverse transcription polymerase chain reaction (RT-PCR). A validated Western blot method quantified dystrophin production (primary biological end point). Immunohistochemistry assessed dystrophin localization and sarcolemmal fiber intensity.

Results. Mean percent of normal dystrophin protein significantly increased from 0.095% at baseline to 1.019% at week 48 (mean change: 0.924%; $P < 0.001$). All muscle biopsy samples (n = 25) displayed a significant increase from baseline in exon 53 skipping at week 48 ($P < 0.001$). A positive correlation between exon 53 skipping and de novo dystrophin production was observed (Spearman-r = 0.500; $P = 0.011$). Mean fiber intensity analysis showed a significant increase from baseline in de novo dystrophin production ($P < 0.001$) and confirmed dystrophin sarcolemmal localization.

Conclusions. Golodirsén is the second PMO shown to increase dystrophin expression and facilitate sarcolemmal localization following initiation of exon skipping. These findings further support a role for PMO technology in DMD treatment.

Funding statement. This clinical trial was funded in part by a European Union Framework Project 7 grant (#305370) and in part by Sarepta Therapeutics, Inc.

Disclosures. Eugenio Mercuri: nothing to disclose. Diane E. Frank: employee of Sarepta Therapeutics, Inc. Laurent Servais: nothing to disclose. Volker Straub: nothing to disclose. Jennifer Morgan: nothing to disclose. Joana Domingos: nothing to disclose. Frederick Schnell: employee of Sarepta Therapeutics, Inc. George Dickson: inventor on related patent. Linda Popplewell: inventor on related patent. Andreea Seferian: nothing to disclose. Mauro Monforte: nothing to disclose. Michela Guglieri: nothing to disclose. Francesco Muntoni: consultant to Sarepta Therapeutics, Inc.

OP 4: Basic Science

Proteomic analyses of FSHD muscular dystrophy by a combination of 2D-DIGE and MALDI ToF/ToF, ICPL and Label free LC-MS/MS

Capitanio D.^{1,2}, Torretta E.¹, Moriggi M.³, Fiorillo C.⁴, Ruggiero L.⁵, Baldacci J.⁴, Santoro L.⁵, Santorelli F.M.⁴, Gelfi C.¹

¹ Dipartimento di Scienze Biomediche per la Salute, Università degli Studi di Milano, Via F.lli Cervi, 93, Segrate, Milano; ² IRCCS Istituto Ortopedico Galeazzi, Via Riccardo Galeazzi, 4, Milano;

³ IRCCS Istituto Neurologico C. Besta, Via Giovanni Celoria, 11, Milano; ⁴ Laboratorio di Medicina Molecolare, IRCCS Stella Maris, Calambrone, Pisa; ⁵ Dipartimento di Neuroscienze, Università Federico II, Napoli

Facio-scapulo-humeral dystrophy (FSHD [OMIM 158900]) is one of the most frequent forms of muscular dystrophy. The FSHD locus was mapped into the subtelomeric region of the long arm of chromosome 4 (4q35), which contains an extensive macrosatellite region with a high degree of complexity and D4Z4 repeats. Despite several studies, the molecular mechanisms associated with FSHD phenotype, remains still unknown.

To get better insight into the pathogenesis of FSHD, we conducted an extensive proteomic analysis in affected patients all carrying the shortened D4Z4 region. In particular muscle biopsies from 14 FSHD and 6 controls were analyzed by 2D-DIGE and MALDI ToF/ToF, ICPL and Label free LC-MS/MS. Muscle biopsy were also processed with standard histopathological stainings.

Collectively, results revealed alteration of 418 differentially expressed protein (201 decreased and 217 increased) in patients versus control group. These belong to the following functional classes: structural/ contractile proteins, transport proteins, glycolytic proteins, stress response, proteins of energy metabolism, lipid and glutathione metabolism. Contractile and structural proteins appear at variance, some of them are upregulated, the same behavior can be attributed to metabolic proteins. Conversely, antioxidant and stress response proteins appear down-regulated as several histone proteins. The preliminary analysis of results from the three proteomic investigations suggests an impairment of protein degradation and stress response together with a deficiency of antioxidant protective elements.

TNPO3 and myogenesis in murine and human myoblasts

Costa R.¹, Rodia M.T.¹, Papa V.¹, Pegoraro V.², Giarretta L.², Marozzo R.², Angelini C.², Cenacchi G.¹

¹ Department of Biomedical and Neuromotor Sciences, University of Bologna, Italy; ² IRCCS Ospedale San Camillo, Venezia, Italy

Limb-girdle Muscular Dystrophy 1F (LGMD1F) is a rare neuromuscular disorder with autosomal dominant inheritance identified in a large Italo-Spanish kindred. Clinical investigation revealed a variable age of onset and different degree of impairment of pelvic girdle muscles, while the common feature is a generalized atrophy of muscle mass. Genetic investigation identified a single deletion in the TNPO3 gene that results in a mutated protein with 15 additional aminoacids. This gene encodes for Transportin 3, a karyopherin- β involved in protein translocation from cytoplasm to the nucleus. The genetic cause of LGMD1F has been clarified but the mechanisms of the pathological process and the role of TNPO3 in skeletal muscle are unknown.

In order to study the morpho-functional role of TNPO3

in muscle, we have investigated the expression of TNPO3 in murine and human myoblasts which, under appropriate culture conditions, differentiate into myocytes. We evaluated TNPO3 expression at different time points during myogenic differentiation and we observed a similar behaviour for both murine and human cells: in the early phase of cell differentiation TNPO3 expression increases and shows nuclear and cytoplasmic localization, it decreases in the middle stage, with a localization mainly limited to the cytoplasm, and it goes back to increase and localize particularly in the cytoplasm in late differentiation. In addition we verified the expression of some myomiRNAs involved in myogenesis and which show an increase during differentiation, and the expression of some specific genes involved in muscle atrophy, that remains the common feature of LGMD1F patients.

RNAseq in urine-derived stem cells identified the expression of more than 300 neuromuscular gene transcripts

Falzarano M.S.¹, Osman H.^{1,2}, Rossi R.¹, Selvatici R.¹, Neri M.¹, Gualandi F.¹, Fang M.³, Lu Z.³, Grilli A.⁵, Biciato S.⁴, Ferlini A.^{1,5}

¹ UOL (Unità Operativa Logistica) of Medical Genetics, University of Ferrara, Ferrara, Italy; ² Department of Medical Microbiology, Faculty of Medical Laboratory Sciences, University of Khartoum, Sudan; ³ BGI-shenzhen, shenzhen, China; ⁴ Dipartimento di Scienze della Vita, University of Modena and Reggio Emilia; ⁵ Neuromuscular Unit, Great Ormond Street Hospital, University College London, London, United Kingdom

We have previously demonstrated that native and differentiated urine stem cells (USCs) are able to recapitulate the DMD cell phenotype. In this study we analyzed the whole transcriptome of native USCs in order to propose them as an in vitro model for studying other neuromuscular disorders. The expression of 472 genes involved in 16 groups of neuromuscular diseases (www.muscle.genetable.fr) was investigated by RNAseq analysis. Studied USCs were isolated from 3 healthy and 1 DMD (del ex45) subjects. We found that 308 and 310 out of 472 neuromuscular explored genes are well expressed in WT and DMD native USCs, respectively.

Transcripts related to vast majority of disease groups are represented with different expression rate, with the exception of ion channel and malignant hyperthermia genes. 70-90% of genes causing hereditary neuropathies, motor neuron diseases, metabolic myopathies, hereditary paraplegias, muscular and congenital muscular dystrophies, and other neuromuscular disorders are expressed both in WT and in DMD samples. 30-60% of the causative genes are detected in the remaining neuromuscular disease groups.

Gene specific RNA analysis to identify novel isoforms or splicing choices was performed, and many new transcripts were identified. Our results suggest that USCs represent a robust model to study genome and transcriptome for mutation detection in many NMDs. They can also be a surrogate cell model to explore atypical and deep intronic mutations affecting RNA processing. Drug screening and biomarkers validation might also be attracting studies to be carried out in these cells.

Autophagy marker LC3 accumulates in immune-mediated necrotizing myopathy muscle fibres

Girolamo E.¹, Lia A.¹, Giannini M.², Amati A.¹, D'Abbicco D.³, Tampoia M.⁴, Serlenga L.¹, Iannone F.², Trojano M.¹

¹ Unit of Myopathology, Department of Basic Medical Sciences, Neuroscience and Sense Organs, Unit of Neurophysiopathology, Policlinico Hospital, University of Bari, Bari, Italy; ² Unit of Rheumatology (DETO), Policlinico Hospital, University of Bari, Bari, Italy; ³ Institute of General Surgery G Marinaccio (DETO), Policlinico Hospital, University of Bari, Bari, Italy; ⁴ Laboratory of Clinical Pathology, Policlinico Hospital, University of Bari, Bari, Italy

Objectives. To investigate the expression of autophagy marker LC3, localization of macrophages and accumulation of misfolded proteins in myofibres of immune-mediated necrotizing myopathy (IMNM) muscle biopsies, and to correlate the results with clinical parameters.

Methods. The analysis was made on muscle sections of 6 IMNM, 4 Dermatomyositis (DM), 5 Polymyositis (PM), 3 sporadic Inclusion Body Myositis (sIBM) patients and 6 healthy, age-matched controls immunolabelled with anti: -autophagy markers LC3b, -ubiquitin, -SQSTM1/p62, -TDP-43 (TAR DNA binding protein), -SMI31, -C5b-9, -CD68, -NCAM (neural cell adhesion molecule), -MHC I (major histocompatibility complex-I), -MHC II.

Results. The number of myofibres containing LC3b was higher in IMNM than in DM or PM, and correlated with creatine kinase levels. In IMNM, LC3b was mainly located in regenerating myofibres, associated with MHC-II + vesicles. The highest number of ubiquitin + myofibres was revealed in IMNM. SMI31 and p62 accumulated in non-necrotic myofibres, the latter colocalizing with LC3 as small puncta in IMNM myofibres and large vacuoles in sIBM myofibres.

Conclusions. These findings suggest an involvement of cellular clearance systems in the pathophysiology of IMNM, like that of sIBM. LC3b + puncta in regenerating myofibres can be considered a peculiar biomarker in IMNM. Further studies of larger patients cohorts are needed to better define IMNM.

Zidovudine ameliorates pathology in the mouse model of Duchenne Muscular Dystrophy via the P2RX7 purinoceptor antagonism

Panicucci C.^{1,2}, Al-Khalidi R.¹, Cox P.¹, Chira N.¹, Róg J.³, Young C.N.J.¹, McGeehan R.E.¹, Ambati K.⁴, Ambati J.⁴, Zabłocki K.³, Gazzzerro E.^{2,5}, Arkle S.¹, Bruno C.², Górecki D.C.¹

¹ Molecular Medicine Laboratory, School of Pharmacy and Biomedical Sciences, University of Portsmouth, UK; ² Center of Myology and Neurodegenerative Disorders, Department of Neuroscience and Rehabilitation, Istituto Giannina Gaslini, Genova, Italy; ³ Laboratory of Cellular Metabolism, Department of Biochemistry, Nencki Institute of Experimental Biology of the Polish Academy of Sciences, Warsaw, Poland; ⁴ Center for Advanced Vision Science & Depts. of Ophthalmology, Pathology, Microbiology, Immunology & Cancer Biology, University of Virginia, Charlottesville, VA, USA; ⁵ Experimental and Clinical Research Center, Charite University, Berlin

Duchenne muscular dystrophy (DMD) is a severe X-linked muscle degenerative disease caused by mutations in the dystrophin gene. It is associated with progressive muscle weakness and untreated individuals lose ambulation around 8-10 years of

age. DMD muscle biopsies are characterized by muscle degeneration aggravated by chronic sterile inflammation which is in part due to an alteration of P2RX7 signaling. Previous studies showed that the P2RX7 inhibition resulted in an attenuation of the phenotype in mdx mouse. As P2RX7 is an attractive target in different human diseases, specific antagonists have been developed but none of these are currently available as a drug. In contrast, Nucleoside Reverse Transcriptase Inhibitors (NRTIs) can act as P2RX7 antagonists and are drugs with an established safety record, including in pediatric populations. Here we show that AZT (Zidovudine), one of the NRTIs, inhibits P2RX7 functions acting via the same allosteric site as other purinergic antagonists. Indeed, we treated 4 weeks old mdx male mice with AZT by i.p. injection twice a day for 4 weeks. At the end of the treatment we observed a phenotype improvement without any detectable side effects. In particular we noticed a positive impact on muscle strength in vivo, a reduction of serum CK levels, an increase in plasma membrane integrity and a reduction of inflammatory cell numbers and inflammation markers in skeletal and heart muscles of treated mice. Given these results, we postulate that AZT could be re-purposed for the treatment of DMD patients.

OP 5: Therapies 2

Nutritional status in SMA type 1 over a 6 month follow-up in Nusinersen Expanded Access Program (EAP)

Messina S.¹, Sframeli M.¹, Bruno C.², Pane M.³, Sansone V.⁴, Catteruccia M.⁵, Stancanelli C.¹, Albamonte E.⁴, Pedemonte M.², D'Amico A.⁵, Bertini E.⁵, Mercuri E.³, Vita G.¹ on behalf of the Italian EAP working group

¹ Department of Clinical and Experimental Medicine, University of Messina and Centro Clinico Nemo Sud, Messina; ² Neuromuscular Disease Unit, G. Gaslini Institute, Genoa; ³ Paediatric Neurology and Centro Clinico Nemo, Catholic University and Policlinico Gemelli, Rome; ⁴ Neurorehabilitation Unit, University of Milan, Centro Clinico Nemo, Niguarda Hospital, Milan; ⁵ Unit of Neuromuscular and Neurodegenerative disorders, Bambino Gesù Children's Hospital, Rome

Optimal nutritional management in SMA type 1 includes longitudinal evaluation of auxological parameters due to the high risk of undernutrition, although SMA-specific growth charts are not yet available. In patients treated with Nusinersen an improvement in bulbar muscle strength has been experienced. However, no systematic studies have been performed on nutritional status.

The aim of this study was to investigate the nutritional status at baseline and after 6 months of Nusinersen treatment in a large cohort of SMA type 1 patients.

We included 84 SMA type 1 patients (age range: 3 months - 18 years) enrolled in the Italian Nusinersen EAP. We collected data on type of nutritional and ventilatory support, body mass index (BMI) at baseline and at 6-month follow-up.

At baseline, 56% of patients were on percutaneous endoscopic gastrostomy (PEG), 6% on nasogastric tube (NGT) and the remaining 38% on oral feeding. At 6-month follow-up, 2 patients having NGT required PEG. At baseline, 57% of the patients were below the 3rd percentile of BMI whereas 8% were above the 85th percentile, being the majority of the latter un-

der 1 year of age and with PEG and tracheostomy. At 6-month follow-up, no significant change in BMI was found, also in patients on oral feeding under the age of 2 years. Interestingly, the group of patients on oral feeding remained stable and 4 patients (age range: 13 months-2 years) were able to eat solid food for the first time.

This study highlights the relevance of optimizing nutritional care in SMA type 1. A longer follow-up will help to further elucidate the effect of Nusinersen.

Development of Golodirsén by the SKIP-NMD Consortium and Design of a phase 1/2 trial of Golodirsén for the treatment of DMD amenable to exon 53 skipping

Monforte M.¹, Frank D.E.², Mercuri E.¹, Servais L.³, Straub V.⁴, Morgan J.⁵, Domingos J.⁵, Schnell F.², Dickson G.⁶, Popplewell L.⁶, Seferian A.³, Guglieri M.⁴, Muntoni F.^{5,7}, the SKIP-NMD Study Group

¹ Catholic University of the Sacred Heart, Rome, Italy; ² Sarepta Therapeutics, Inc., Cambridge, MA, USA; ³ Institute of Myology, Paris, France; ⁴ Newcastle University and Royal Victoria Infirmary Hospital, Newcastle upon Tyne, UK; ⁵ University College London, London, UK; ⁶ Royal Holloway, University of London, London, UK; ⁷ Great Ormond Street Hospital, London, UK

Objective. Duchenne muscular dystrophy (DMD), a rare, X-linked recessive disorder caused by DMD gene mutations, results in muscle degeneration and premature death. The SKIP-Neuromuscular Disease (SKIP-NMD) consortium of academic, commercial, and advocacy partners received European Union Framework Project 7 funding to develop golodirsén, a phosphorodiamidate morpholino oligomer (PMO) designed to hybridize and skip exon 53 of dystrophin pre-mRNA.

Methods. PMOs were analyzed for exon-skipping efficiency in cells by RT-PCR. Golodirsén was selected for preclinical evaluations of genotoxicity (mutagenicity and chromosomal aberration in vitro) and pharmacology/toxicology (in cynomolgus monkeys) and was manufactured per Good Manufacturing Practices for clinical trial use. A 2-part, phase 1/2, dose-titration, 12-week, double-blind study evaluated safety, tolerability, and pharmacokinetics of once-weekly intravenous golodirsén (part 1) in males aged 6-15 years with DMD mutations amenable to exon 53 skipping, screening and baseline 6-minute walk test (6MWT) distance \geq 250 m, and North Star Ambulatory Assessment (NSAA) total score $>$ 17 or rise (Gowers') time $<$ 7 seconds. Part 2 assessed efficacy and safety of open-label golodirsén treatment, including motor function and strength, dystrophin expression, disease-related biomarkers, and pulmonary function, through 168 weeks.

Results. All patients randomized to golodirsén (n = 8) or placebo (n = 4) in part 1 received golodirsén in part 2, as well as 13 newly enrolled patients. Week 48 muscle biopsies demonstrated increased dystrophin production with golodirsén; full results are expected in late 2019.

Conclusions. This unique golodirsén trial, designed with clinically relevant inclusion criteria and outcome measures, will provide valuable insights into the efficacy of exon-skipping therapies for DMD.

Funding statement. Funded in part by a European Union Framework Project 7 (EUF7) grant (#305370) and in part by Sarepta Therapeutics, Inc.

Disclosures. Mauro Monforte: nothing to disclose. Diane E. Frank: employee of Sarepta Therapeutics, Inc. Eugenio Mercuri:

nothing to disclose. Laurent Servais: nothing to disclose. Volker Straub: nothing to disclose. Jennifer Morgan: nothing to disclose. Joana Domingos: nothing to disclose. Frederick Schnell: employee of Sarepta Therapeutics, Inc. George Dickson: inventor on related patent. Linda Popplewell: inventor on related patent. Andreea Seferian: nothing to disclose. Michela Guglieri: nothing to disclose. Francesco Muntoni: consultant to Sarepta Therapeutics, Inc.

Effect of serum deprivation and WY14643 treatment on NLSMD fibroblasts

Pennisi E.M.¹, Missaglia S.^{2,3}, Gragnani F.⁴, Garibaldi M.¹, Angelini C.⁵, Mora M.⁶, Taviani D.^{2,3}

¹ UOC Neurologia, San Filippo Neri hospital, via Martinotti 20, Rome 00135, Italy; ² Laboratory of Cellular Biochemistry and Molecular Biology, CRIBENS, Catholic University of the Sacred Heart, pz Buonarroti 30, Milan 20145, Italy; ³ Psychology Department, Catholic University of the Sacred Heart, Largo Gemelli 1, Milan 20123, Italy; ⁴ UOC Neurologia, Pertini Hospital, Rome, Italy; ⁵ IRCCS Fondazione Ospedale S. Camillo, Venice, Italy; ⁶ Marina Mora: Neuromuscular Diseases and Neuroimmunology Unit, Fondazione IRCCS Istituto Neurologico "Carlo Besta", Milan, Italy

Neutral Lipid Storage Disease with Myopathy (NLSMD) is an autosomal recessive disorder characterized by accumulation of triacylglycerol into cytoplasmic lipid droplets (LDs). It is caused by mutations in the PNPLA2 gene, encoding the ATGL enzyme.

NLSMD patients present progressive myopathy, cardiomyopathy and failure of internal organs. Previously we have demonstrated that some ATGL mutated proteins, severely diminish lipase activity, but are able to bind to LDs, while some others loss totally lipase function.

Skin biopsies have been obtained from 8 NLSMD patients. Four different lines of fibroblasts have been tested, to reverse the disease phenotype promoting "in vitro" a way alternative to TAG breakdown. We used WY-14643, a potent PPAR α agonist, and two beta-adrenergic compounds, Clenbuterol and Salmeterol, both in normal and reduced serum concentrations. These cell lines, carrying different mutations, were specifically selected so that 2 of them were completely lacking ATGL activity, while the others 2 showed only a reduction of ATGL lipase function. Biochemical lipase assays and Immunofluorescence analyses of LDs number and dimension were performed before and after treatment. It was found that WY-14643 70 μ M treatment (with 3% of FBS) significantly decreased the intracellular TAG content in the fibroblasts group with some residual enzyme activity, carrying missense mutations. Conversely, the fibroblasts without any enzyme activity, did not show treatment dependent effect. When Salmeterol (100 μ M) and Clenbuterol (1 μ M) were added to medium (10% FBS), Clenbuterol resulted in a low reduction of TAG content, while Salmeterol was not effective. The PPAR α agonist WY-14643 seems to increase TAG mobilization in NLSMD fibroblasts maintained in low serum concentration (Table 1).

Table 1. Primary dermal NLSDM fibroblasts obtained from skin biopsies.

Family	Patients	cDNA	Protein	Reference
I	1	c.662G > C	R221P	Tavian et al., 2012
II	2	c.541delCA	I212X	Campagna et al., 2008
III	3	c.177T > G	L56R	Missaglia et al., 2015
		c.577A > T	I193F	
IV	1	c.41_47delGCTGCGG	G14Afs75X	Pasanisi et al., 2016
V	1	c.696 + 4A > G	No protein	Missaglia et al., 2016
		c.553_565delGTCCCCCTTCTCG		

Sport and neuromuscular diseases: psychosocial impact and physical benefits on a cohort of patients

Stancanelli C.¹, La Foresta S.¹, Vita G.L.¹, Faraone C.¹, Laganà G.¹, Vita G.^{1,2}

¹ Nemo Sud Clinical Center, Messina; ² Department of Clinical and Experimental Medicine, University of Messina, Messina

Intense physical exercise has been traditionally discouraged in the management of neuromuscular diseases (NMD). It appears as though highly repetitive and heavy-resistance exercises are even detrimental. Despite some NMD patients perform agonistic sport activity even in Paralympic Games, the relationship between sport activity and quality of life (QoL) in NMD has been rarely investigated.

A multicentre study has been planned, involving many Italian Referral Centres for neuromuscular diseases. Main aim of the study was to evaluate the role and benefits of physical activity in general muscle strength, social participation, self-esteem and QoL. The protocol included questionnaires to assess their mental and emotional health: State-Trait Anxiety Inventory, Beck Depression Inventory II, Rosenberg Self-Esteem Scale, Eysenck Personality Questionnaire revised version, 36-item Short-Form Questionnaire or 12-Item Short-Form Health Survey, ID PAIN, Behavioural Regulation Exercise Questionnaire-2 and the lifetime total physical activity questionnaire.

We present the preliminary data of the study, only from patients followed by the Coordinating Centre of Messina. 11 athletes (M8, F3; mean age 26 ± 13 yrs) with DMD (n. 5), BMD (n. 1), LGMD (n. 1), SMA2 (n. 2), SMA3 (n. 1), CMT (n. 1), have been recruited and compared to a cohort of 22 patients as control group, not practicing any sport, matching age, gender, mBI and, when possible, diagnosis. The athletes performed agonistic sport for at least 1 year (n. 8 wheelchair-hockey, n. 2 swimming, n. 1 dancing). Anxiety and depression are lower in athletes, leading them to a major self-efficacy, interpretation of existing situations, problem-solving and more autonomy-promoting. These results confirm the correlation between sport practice and treatment and/or prevention of depression.

RG7916 distributes and increases SMN protein levels in both the central nervous system and peripheral organs

Poirier A.¹, Weetall M.², Ratni H.¹, Heinig K.¹, Naryshkin N.², Paushkin S.³, Mueller L.¹

¹ Pharmaceutical Sciences, Roche Pharma Research and Early Development, Roche Innovation Center, Basel, Switzerland; ² PTC Therapeutics, South Plainfield, NJ, USA; ³ SMA Foundation, New York, USA

RG7916 (RO7034067) is an oral, small-molecule sur-

vival of motor neuron 2 (SMN2) pre-mRNA splicing modifier that distributes into central nervous system (CNS) and peripheral tissues. RG7916 is under investigation in the SUN-FISH (Type 2/3 spinal muscular atrophy [SMA]), FIREFISH (Type 1 SMA) and JEWELFISH (Type 2/3 SMA) clinical studies. We assessed tissue distribution and effect of RG7916 on SMN protein expression.

Distribution of RG7916 into brain, cerebrospinal fluid (CSF), muscle and peripheral tissues was assessed in murine SMA models, rats and cynomolgus monkeys after single and repeated daily oral (or intraperitoneal [IP] in neonatal mice) doses, up to 39 weeks. SMN protein levels in blood, brain and muscle of SMA transgenic mice were monitored.

Total drug levels were similar in plasma, muscle and brain of mice (n = 90), rats (n = 148) and monkeys (n = 24). CSF levels reflected plasma free compound concentrations. A parallel dose-dependent increase in SMN protein levels was seen in muscle (periphery) and brain (CNS) in two SMA mouse models dosed with RG7916. A similar correlation was also observed between the increase in SMN protein levels in blood (periphery) and in brain or spinal cord (both CNS) with SMN2 splicing modifiers structurally similar to RG7916.

RG7916 distributes well into the CNS and peripheral tissues, including muscle and blood, in mice, rats and monkeys, following single/repeat oral or IP dosing. Based on these preclinical findings, SMN protein changes seen in SMA patients' blood following oral dosing is expected to be accompanied by parallel increases in CNS, muscle and other peripheral tissues.

OP 6: Muscular Dystrophies

Profiling brain functioning in muscular dystrophies (MD): upgrading knowledge from on-going research

Baldanzi S.¹, Ricci G.¹, Simoncini C.¹, Cecchi P.², Cosottini M.³, Angelini C.⁴, Siciliano G.¹

¹ Department of Clinical and Experimental Medicine, University of Pisa; ² Neuroradiology Unit, Pisa Hospital, Pisa;

³ Department of Translational Research and New Technologies in Medicine and Surgery, University of Pisa; ⁴ IRCCS San Camillo, Lido, Venice

Background and aims. It has been several times ascertained that beyond primary muscle involvement MD can affect patients' brain, with detrimental impact on patients' quality of life (QoL).

Different mechanisms have been claimed for explain-

ing this phenotypic component, among which genetic background and tissue-specific protein expression, but also secondary acquired factors linked to environment and disease progression.

Methods. We systematically analyze our own data and present literature about cognitive-behavioural alterations in a sample of MDs including oculopharyngeal muscular dystrophy (OMD), myotonic dystrophy type 1 (DM1), facioscapulothoracic dystrophy and limb-girdle muscular dystrophy (LGMD).

Results. Although systematic studies are very few on that, frequencies up to 100% in POMT2-LGMD and OPMD small case series have been reported.

In our study 15 DM1 patients were assessed twice in a follow-up period of 2-4yrs; cognitive worsening was detected in mnesic (average 8.5%), visuo-constructive (average 5.5%) and executive domains (average 8.7%); caregivers evidenced relevant increase in apathetic behaviour. Retrospective evaluation of brain NMR, enabled us to find that in 5 patients, Fazekas Visual Score (FVS) and Brain Parenchymal Fraction (BPF) could be predictive of this decline (FVS = 2-3; BPF < 76.28) over disease natural history.

Conclusions. In the last decade several evidences suggest that MDs could present with a broad psychopathological spectrum ranging from cognitive dysfunction to neuropsychiatric manifestations. It is suitable to strengthen research on central nervous system (CNS) involvement in MDs for better clinical management. The use of brain MRI could support more clinical approach in terms of potential indicator of severity and progression of CNS involvement in MDs.

Autosomal recessive Bethlem myopathy: a clinical, genetic and functional study

Caria E.¹, Cescon M.², Gualandi F.³, Rossi R.³, Rimessi P.³, Cotti Piccinelli S.¹, Marchesi M.¹, Gallo Cassarino S.¹, Gregorio I.², Ferlini A.³, Padovani A.¹, Bonaldo P.², Filosto M.¹

¹ ERN EURO-NMD Center for Neuromuscular Diseases, Unit of Neurology, ASST "Spedali Civili", Brescia, Italy; ² Department of Molecular Medicine, University of Padova; ³ Unit of Medical Genetics, S'Anna University - Hospital of Ferrara

Bethlem myopathy (BM) represents the milder form of the spectrum of Collagen VI myopathies which are characterized by a clinical continuum with Ullrich congenital muscular dystrophy and BM at each end of the spectrum and less well-defined intermediate phenotypes in between.

Causing mutations occur in the COL6A genes encoding for subunits $\alpha 1$ (COL6A1), $\alpha 2$ (COL6A2) and $\alpha 3$ (COL6A3) and are inherited in an autosomal dominant fashion. Only rarely a recessive inheritance has been reported.

We here describe clinical, genetic and functional studies in a recessive BM family harbouring two novel pathogenic mutations in COL6A2 gene.

Two siblings, a 40-year-old male and a 23-year-old female, presented with muscle weakness and wasting, elbows and Achilles tendon retractions, lumbar hyperlordosis, waddling gait and positive Gowers' sign.

Muscle biopsy showed a dystrophic pattern. Molecular analysis of the COL6A2 gene revealed the novel p.Gln889* and p.Pro260(3) variations. The first one determines a pre-

mature stop codon, the second one causes insertion of two prolines.

On the segregation study conducted on asymptomatic parents, the 61-year-old mother is the carrier of the p.Pro260(3) variant and the 61-year-old father of the p.Gln889* variant.

Studies on patients' fibroblasts show a strong reduction of COL6 secretion in the culture media, in accordance with a remarkable decrease of COL6A2 subunit expression.

This study further confirms occurrence of recessive inherited BM and expands the genetic heterogeneity of this group of muscle diseases.

Use of muscle MRI to follow up patients with inflammatory idiopathic myopathies (IIM)

Colombo M.¹, Previtali S.C.^{2,3}, Velardo D.^{2,3}, Ambrosi A.⁴, Scarlato M.³, Ramirez G.A.⁵, Canti V.⁵, De Lorenzo R.⁵, Cava M.¹, Fazio R.³, De Cobelli F.¹, Rovere Querini P.⁵

¹ Clinical and Experimental Radiology Unit and Vita-Salute San Raffaele University; ² INSPE and Division of Neuroscience; ³ Department of Neurology; ⁴ CUSSB University Centre for Biomedical Sciences and Vita-Salute San Raffaele University; ⁵ Division of Immunology and Vita-Salute San Raffaele University - IRCCS Ospedale San Raffaele, Milano, Italy

Objective. To evaluate the efficacy of different magnetic resonance imaging (MRI) sequences in detecting inflammatory idiopathic myopathy (IIM) progression, relapsing and response to therapy.

Methods. 32 consecutive patients with IIM including polymyositis (PM), dermatomyositis (DM), immune-mediated necrotizing myopathies (NAM) and anti-synthetase syndrome (ASS), underwent a 1.5T MRI at tight. Fourteen patients had also a longitudinal MRI evaluation. Semiquantitative scores for Short Tau Inversion Recovery (STIR), perfusion, Diffusion Weighted Imaging (DWI), fat infiltration, muscle atrophy, and Late Enhancement (LE) were assessed and related to several clinical and laboratory parameters.

Results. STIR, perfusion and DWI correlated to clinical severity and successful therapeutic response. LE correlated to signs of muscle inflammation but not with fat infiltration and muscle atrophy. Scarce therapy response is revealed by STIR and DWI positivity.

Interpretations. Our study suggests that muscle MRI evaluation may actively contribute to a better characterization of IIM patients to predict treatment response or relapses.

The JAIN clinical outcome study in dysferlinopathy

Semplicini C.¹, Smith F.², Marni J.^{3,4}, Mayhew A.G.², Fernandez-Torron R.^{2,5}, Spuler S.⁶, Day J.W.⁷, Jones K.J.⁸, Bharucha-Goebel D.X.^{9,10}, Salort-Campana E.¹¹, Pestronk A.¹², Walter M.C.¹³, Paradas C.¹⁴, Stojkovic T.¹⁵, Mori-Yoshimura M.¹⁶, Bravver E.¹⁷, Díaz-Manera J.^{18,19}, Bello L.¹, Pegoraro E.¹, Mendell J.R.², Bushby K.², Straub V.², The Jain COS Consortium

¹ Department of Neuroscience, University of Padova, Italy; ² The John Walton Muscular Dystrophy Research Centre, MRC Centre for Neuromuscular Diseases, Institute of Genetic Medicine, Central Parkway, Newcastle upon Tyne, UK; ³ Center for Translational Science, Division of Biostatistics and Study Methodology, Children's National Health System, Washington, DC, USA; ⁴ Pediatrics, Epidemiology and Biostatistics, George Washington University, Washington, DC, USA; ⁵ Neuromuscular Area, Biodonostia Health Research Institute, Neurology Service, Donostia University Hospital, Donostia-San Sebastian, Spain; ⁶ Charite Muscle Research Unit, Experimental and Clinical Research Center, Berlin, Germany; ⁷ Department of Neurology and Neurological Sciences, Stanford University School of Medicine; Stanford, CA, USA; ⁸ Institute for Neuroscience and Muscle Research, Children's Hospital at Westmead, University of Sydney, Australia; ⁹ Department of Neurology Children's National Health System, Washington, DC, USA; ¹⁰ National Institutes of Health (NINDS), Bethesda, MD, USA; ¹¹ Service des maladies neuromusculaire et de la SLA, Hôpital de La Timone, Marseille, France; ¹² Department of Neurology Washington University School of Medicine, St. Louis, MO, USA; ¹³ Friedrich-Baur-Institute, Dept. of Neurology, Ludwig-Maximilians-University of Munich, Germany; ¹⁴ Neuromuscular Unit, Department of Neurology, Hospital U. Virgen del Rocío/Instituto de Biomedicina de Sevilla, Sevilla, Spain; ¹⁵ Institut de Myologie, AP-HP, GH Pitié-Salpêtrière, Paris, France; ¹⁶ Department of Neurology, National Center Hospital, National Center of Neurology and Psychiatry Tokyo, Japan; ¹⁷ Neuroscience Institute, Carolinas Neuromuscular/ALS-MDA Center, Carolinas HealthCare System, Charlotte, NC, USA; ¹⁸ Centro de Investigación Biomédica en Red en Enfermedades Raras (CIBERER), Barcelona, Spain; ¹⁹ Neuromuscular Disorders Unit, Neurology Department, Hospital de la Santa Creu i Sant Pau, Barcelona, Spain; ²⁰ Research Institute at Nationwide Children's Hospital, The Ohio State University, Columbus, Ohio USA

Introduction. Dysferlinopathies present with a variable spectrum of muscle weakness. The Clinical Outcome Study (COS) aims to develop understanding of the disease and improve clinical trial readiness.

Methods. 197 patients with dysferlinopathy participated in the Jain Foundation's International COS study, across 15 sites in 8 countries. The cohort is 52% female, age ranging from 12 to 88 (mean 40). At baseline 75% participants were ambulant. Physiotherapy assessments included muscle strength evaluation, functional performance (North Star Assessment for Dysferlinopathy, NSAD; Brooke score and Performance of Upper Limb), timed tests, and respiratory function testing. Semi-quantitative MRI analysis was performed at baseline, and annual quantitative muscle MRI using Dixon techniques were acquired.

Results. A characteristic pattern of muscle involvement, independent of the clinical phenotype, was detected on base-

line MRI: gastrocnemius medialis and soleus were most frequently affected at baseline. Increased muscle pathology on MRI correlated with disease duration and functional impairment. Significant change was captured from baseline to year 1 in a range of functional outcome measures, strength measurements and quantitative MRI fat fraction. Motor performance assessed by NSAD demonstrated slow but consistent and significant deterioration in scores and confirms NSAD as a dysferlin specific scale. Power calculations determined that 46 patients are required to determine clinical effectiveness for a hypothetical 1 year clinical trial based on the a-NSAA as a clinical endpoint.

Conclusions. Change in Dysferlinopathy can be measured using physiotherapy outcome measures and quantitative muscle MRI. Results support future study design and help power future clinical trials.

Quantitative muscle ultrasound analysis in FSHD patients

Vanoli F.¹, Di Pasquale A.¹, Fragiotta G.², Fionda L.¹, Leonardi L.¹, Garibaldi M.¹, Bucci E.¹, Morino S.¹, Grossi A.¹, Tupler R.³, Antonini G.¹

¹ Department of Neurological Sciences, Mental Health and Sensory Organs (NESMOS) "Sapienza" University of Rome; ² Department of Medico-Surgical Sciences and Biotechnologies "Sapienza" University of Rome Polo Pontino; ³ Department of Life Sciences, University of Modena and Reggio Emilia

Ultrasound (US) represents a valid portable, non-expensive and non-invasive diagnostic tool in myopathies. Muscle thinning and increase in echo intensity caused by fibro-adipose substitution are both pathological hallmarks of myopathy. However, operator-dependency and both patient and machine-related variability, limit its diagnostic reliability when compared with MRI. The aim of our work is to evaluate the applicability of quantitative muscular ultrasonography (QMUS) in facioscapulohumeral muscular dystrophy (FSHD). Until now, we evaluated 8 patients with genetically confirmed FSHD1 and 8 healthy controls matched for sex, age and BMI. Clinical severity was evaluated by FSHD score. QMUS was performed calculating mean muscle echo intensity by computer assisted gray-scale analysis. The same muscles were evaluated with MRI keeping QMUS examiner blind to MRI data. 160 muscles were evaluated (80 from patients and 80 from controls). FSHD muscles displayed a significant increase in echogenicity compared to controls ($p \leq 0.001$). Patients with lower FSHD score presented a significantly lower echogenicity of the muscles, compared to the patients with a higher score ($p \leq 0.001$). A good level of correspondence was encountered between the QMUS and MRI evaluation, in particular, muscles with alterations in T1 sequences are more hyperechogenic, while muscles altered in STIR sequences are more hypoechogenic compared with normal muscles. Although a confirmation on larger sample is needed, considering the correlation between QMUS data and both clinical and MRI findings, our research suggests a possible future application of quantitative muscular ultrasonography in the diagnosis of muscular disorders.

MUSCLE CLUB SESSION

(in alphabetical order of the first Author)

Clinical presentation of a congenital myopathies LGMD D2.

New phenotype in an Hungarian family

Angelini C., Marozzo R., Pegoraro V.

San Camillo Hospital IRCCS, Venice, Italy

We present a congenital myopathies-LGMD with severe phenotype. In the maternal pedigree an affected child was reported. The mother a 43 year old woman started walking at 15 months, was always weak as a child respect to peers, had proximal weakness primarily affecting lower limbs. During her second pregnancy at 30 years she underwent a C-section and presented difficulty breathing and felt "paralyzed". She had frequent falls, difficulty swallowing and could not run, keep legs elevated or raise from floor, to climb stairs used handrail. She has reduced vital capacity on spirometry (FVC 57%). On last examination she had pigeon toe-feet, kyphoscoliosis, weakness of triceps and deltoid (2/5 MRC scale), biceps, pectoralis, wrist extensors (4/5). Her 12 years old son presented weakness since first year. He started walking at one year. He walked 3 km up to 10 years, but walks only 300 metres now, feels fatigued and falls. He has a waddling gait, Gowers sign, climbs stairs using handrail. He has difficulty swallowing. On examination he could not raise from laying position, without grasping his knees. His grip is weak. DTR were absent. Muscle MRI was performed in both mother and son and showed marked generalized muscle atrophy. A heterozygous frameshift deletion c2767delC(pArg923Aspfs17) in exon 23 of TNPO3 gene was identified in mother and son, absent in another unaffected son, segregating with disease within the family. This variant appears associated to a intermediate phenotype LGMD/congenital myopathy leading to early, progressive weakness although with different disease severity in mother and son.

Unusual symptoms and pathology in a woman with myofibrillar myopathy

Bortolani S., Vercelli L., Chiadò-Piat L.,

Boschi S., Mongini T.

Department of Neuroscience University of Turin, Turin

Introduction. Myofibrillar myopathies (MFMs) are a morphologically distinct but genetically heterogeneous group of disorders that affect cardiac and skeletal muscle and usually inherited in an autosomal dominant manner. Mutations in genes which encode Z-disc associated proteins with diverse functions are known, but the exact pathogenesis is still not fully understood.

Case presentation. A 60-year-old woman presented with a 15-year history of distal weakness, respiratory insufficiency requiring invasive ventilation followed by dysphonia and severe dysphagia leading to malnutrition. No evidence of vocal cord paralysis. EMG showed a chronic neurogenic pattern. CK levels were slightly elevated (1.5x). Family history revealed a recurrence of cardiac defects or sudden death in one brother, on sister and both sons. Deltoid muscle biopsy was performed showing myopathic features (rounding of muscle fibers, pathological fiber size variation), abnor-

mal myofibrillar network, subsarcolemmal and cytoplasmic protein aggregates; non-rimmed, rare rimmed vacuoles and ragged red fibers were seen in Gomori trichrome staining. Immunohistochemical analysis showed abnormal accumulations of desmin. A pathology diagnosis of myofibrillar myopathy (MFM) was made.

Discussion and conclusions. We presented a case of myofibrillar myopathy with prominent bulbar muscle weakness and mitochondrial alterations at muscle specimen, expanding the clinical spectrum of myofibrillar myopathies and pointing out the significance of secondary mitochondrial alterations in muscles biopsies.

Exercise intolerance and myoglobinuria as presenting symptom of alpha-sarcoglycanopathy

Catteruccia M.¹, Primiano G.², Fattori F.¹, Bertini E.¹,

Servidei S.², D'Amico A.¹

¹ Unit of Neuromuscular and Neurodegenerative Disease, Bambino Gesù Children's Research Hospital Rome; ² Institute Of Neurology, Catholic University, Rome

Introduction. The sarcoglycanopathies are a heterogeneous group of autosomal recessive limb-girdle muscular dystrophies that cause varying degrees of progressive proximal muscle weakness.

Methods. We describe two patients with exercise-induced myalgias and rhabdomyolysis with myoglobinuria secondary to SGCA mutation. Both patients underwent clinical examination, blood exams, muscle MRI, muscle biopsy and comprehensive myopathy next generation sequencing (NGS) gene panels.

Results. Patient 1 is a young girl who presented with exercise intolerance, myalgia and dark urine after physical activity since the teenage. CK levels were high (above 5,000 UI/L). Muscle strength was normal. Muscle MRI showed fatty infiltration of paraspinal and glutei muscles, and minor involvement of the adductor magnus. On muscle biopsy, a markedly diminished α -sarcoglycan and mild reduction of β -, γ - and δ -sarcoglycan immunostaining was observed. Genetic analysis showed the c.92T > C (p.Leu31Pro) and c.739G > A (p.Val247Met) SGCA mutations.

Patient 2 is a woman that at the age of 33 years experienced marked exercise intolerance and diffuse myalgias during pregnancy. CK were above 10,000 UI/L. Neurologic examination and muscle MRI were normal. On muscle biopsy a severe reduction of immunostaining for α -, β -, γ - and δ -sarcoglycan was detected. Genetic testing revealed homozygosity for the SGCA mutation c.850C > T; p.(Arg284Cys).

Conclusions. This presentation with severe exercise intolerance and normal muscle strength is uncommon in sarcoglycanopathies and described so far only in few reports in the literature. However, it has to be kept in mind in the differential diagnosis in cases of hyperkemia and exercise intolerance with rhabdomyolysis, even in the absence of muscle weakness.

Core and rod myopathy due to a novel mutation in BTB domain of KBTBD13 gene presenting as LGMD

Garibaldi M.^{1,2}, Fattori F.², Bortolotti C.³, Brochier G.⁴, Labasse C.⁴, Verardo M.², Pennisi E.M.⁵, Di Pasquale A.¹, Torchia E.¹, Bucci E.¹, Morino S.¹, Bertini E.S.², Paradas C.⁶, Romero N.B.⁴, Antonini G.¹

¹ Neuromuscular Disease Centre, Sant'Andrea Hospital, Department of Neurology, Mental Health and Sensory Organs (NESMOS), SAPIENZA University of Rome, Italy; ² Unit of Neuromuscular and Neurodegenerative Diseases, Laboratory of Molecular Medicine, Department of Neurosciences, Bambino Gesù Children's Hospital, Rome, Italy; ³ Life Science Department, University of Modena e Reggio Emilia, Modena, Italy; ⁴ Neuromuscular Morphology Unit, Myology Institute, Groupe Hospitalier Universitaire La Pitié-Salpêtrière, Paris, France; ⁵ Unit of Neuromuscular Disorders, Neurology, San Filippo Neri Hospital, Rome, Italy; ⁶ Neuromuscular Unit, Hospital Universitario Virgen del Rocío/Instituto de Biomedicina de Sevilla, Sevilla, Spain

A 59 years-old man complained about progressive pelvic and scapular girdles weakness since he was 50. Clinical examination revealed a generalized muscle hypertrophy, slowly movements and proximal muscle weakness. CK level ranged from 250 to 600 UI/L. Morphological data from three muscle biopsies were available. Nemaline rods were detected in two of three biopsies. ACTA1, RYR1, and NEB genes were initially ruled out. Because of muscle MRI features and clinical phenotype, mutation on POGUT1 was suspected. Alpha-dystroglycan showed normal immunostaining on muscle biopsy but reduction on WB. Molecular analysis of POGUT1 was negative. Finally, a third biopsy was performed and revealed the presence of cores by optic microscopy whereas small rods were detected by electron microscopy. Type 2 hypotrophy was not observed in any of three muscle biopsies. Sanger sequencing revealed a novel heterozygous missense mutation in BTB domain of KBTBD13 gene leading the diagnosis of core and rod myopathy. Mutation falls at the end of the alpha4 helix and seems to affect the self-association of BTB domain but not the BTB-Cul3 interaction. NGS panel for congenital myopathies ruled out other possible genes implicated in core and rod myopathies. Our findings expand clinical and genetical spectrum of core and rod myopathies.

Late-onset axial myopathy (Bent spine syndrome): a case report

Montano V.¹, Ricci G.¹, Baldinotti F.², Ali G.³, Chico L.¹, Calì Cassi L.⁴, Barison A.⁵, Costa R.⁶, Cenacchi G.⁶, Caligo M.A.², Siciliano G.¹

¹ Department of Clinical and Experimental Medicine, Neurological Unit, University of Pisa, Pisa, Italy; ² Laboratory of Medical Genetics, Azienda Ospedaliero-Universitaria Pisana, S. Chiara Hospital, Pisa, Italy; ³ Department of Surgical, Medical, Molecular Pathology and Critical Area, University of Pisa, Pisa, Italy; ⁴ Department of Musculoskeletal and Skin Diseases, and Hand Surgery, University of Pisa, Pisa, Italy; ⁵ Cardiology Division, Fondazione Toscana Gabriele Monasterio, Pisa, Italy; ⁶ Department of Biomedical and Neuromotor Sciences, University of Bologna, Bologna

We describe the case of a 73 year old woman. Since the age of 70, she has been complaining of progressive axial muscle weakness (Bent spine syndrome). She reported a previous therapy with statins for a period of 15 years. Blood CK was 500 U/L. The muscle MRI showed a diffuse fat infiltration of lower limb. Cardiac and respiratory evaluations were normal. In her family history, also the mother suffered of a mild and late-onset camptocormia. The muscle biopsy showed several fibers with empty vacuoles in sections stained with haematoxylin and eosin and Gomori-modified trichrome. Vacuoles had an oval shape or lobulated border. Ultrastructural analysis confirmed disintegration of the sarcomeric Z disc and myofibrils. Exome analysis allowed to achieve the genetic diagnosis.

Filamin-C myopathy associated to brain and spinal cord abnormalities: expanding the clinical phenotype

Previtali S.C.¹, Scarlato M.¹, Vezzulli P.², Ruggieri A.⁵, Velardo D.^{1,4}, Benedetti S.³, Colombo B.¹, Maggi L.⁵, D'Angelo G.⁴, Mora M.⁵

¹ InSpe (Institute of Experimental Neurology), Division of Neuroscience and Dept. of Neurology; ² Neuroradiology Unit; ³ Laboratory of Clinical Molecular Biology and Cytogenetics; IRCCS Ospedale San Raffaele, Milano, Italy; ⁴ Neuromuscular Disorders Unit, Scientific Institute IRCCS E. Medea, Bosisio Parini, Lecco, Italy; ⁵ Neuromuscular Diseases and Neuroimmunology Unit, Fondazione IRCCS Istituto Neurologico Carlo Besta, Milan, Italy

We report two siblings carrying a mutation in the actin-binding domain of the Filamin-C (FLNC) gene. The clinical phenotype is characterized by a severe myofibrillar distal myopathy associated to moderate cerebellar/sensory ataxia and pyramidal signs. Both siblings have brain and spinal cord magnetic resonance images showing cerebellar and cervical spinal cord atrophy as well as cervical spinal cord lesion. This report further expands the disease spectrum caused by FLNC mutations and highlights how the complete description of complex/mixture genetic phenotypes may be helpful to drive proper diagnostic procedures and to better understand the pathogenesis of the disease.

ABSTRACTS OF POSTER COMMUNICATIONS

(in alphabetical order of the first Author)

Revised Upper Limb Module for spinal muscular atrophy: 12 month changes

Antonaci L.^{1,2}, Pera M.C.^{1,2}, Coratti G.^{1,2}, Mazzone E.S.¹, Montes J.^{3,4}, Scoto M.⁵, De Sanctis R.^{1,2}, Forcina N.^{1,2}, Main M.⁵, Mayhew A.⁶, Muni Lofra R.⁶, Dunaway Young S.^{3,4}, Glanzman A.M.⁷, Duong T.⁸, Pasternak A.^{9,10}, Ramsey D.⁵, Darras B.⁹, Day J.W.⁸, Finkel R.S.¹¹, De Vivo D.C.⁴, Sormani M.P.¹², Bovis F.¹², Muntoni F.^{5,13}, Pane M.^{1,2}, Mercuri E.^{1,2}

¹ Paediatric Neurology Unit, Catholic University; ² Centro Nemo, Fondazione Gemelli, Rome, Italy; ³ Departments of Rehabilitation and Regenerative Medicine, Columbia University Medical Center, New York, USA; ⁴ Departments of Neurology, Columbia University Medical Center, New York, USA; ⁵ Dubowitz Neuromuscular Centre, UCL Institute of Child Health & Great Ormond Street Hospital, London; ⁶ John Walton Muscular Dystrophy Research Centre, Institute of Genetic Medicine, Newcastle University, UK; ⁷ Department of Physical Therapy, The Children's Hospital of Philadelphia, Philadelphia; ⁸ Department of Neurology, Stanford University, Stanford, California, USA; ⁹ Department of Neurology, Boston Children's Hospital, Harvard Medical School, Boston, MA, USA; ¹⁰ Department of Physical Therapy and Occupational Therapy, Boston Children's Hospital, Boston, MA, USA; ¹¹ Nemours Children's Hospital, University of Central Florida College of Medicine, Orlando, USA; ¹² Biostatistics Unit, Department of Health Sciences, University of Genoa, Italy; ¹³ NIHR Great Ormond Street Hospital Biomedical Research Centre, London, UK

Background. The Revised Upper Limb (RULM) is a functional scale specifically developed to assess upper limb function in SMA patients. The aim of the study was to use the Revised Upper Limb Module functional scale to assess longitudinal 12 month changes in type 2 and 3 patients affected by spinal muscular atrophy and to identify possible trajectories of progression according to age or functional status.

Methods/results. The study included 119 patients, 65 type 2 and 54 type 3 (32 ambulant and 22 non-ambulant). Their age ranged between 2 and 49 years. The 12 month changes on the Revised Upper Limb Module ranged between -7 and 9 (mean -0.39). The mean changes were not significantly different between the three spinal muscular atrophy (SMA) types (-0.43 in type 2, -0.23 in non-ambulant type 3 and -0.34 in ambulant type 3, $p = 0.96$) and the relationship between 12 month change and age classes was not significantly different among the three types of SMA patients.

Conclusions. Our results confirm that the Revised Upper Limb Module explores a wide range of functional abilities and can be used in ambulant and non-ambulant patients of different ages. Although the overall mean 12 month changes were relatively small, the effect of age and functional status at baseline on the patterns of changes could be observed. This information can be of help at the time of designing clinical trials.

Bi-allelic mutations in TTN cause congenital centronuclear myopathy: a case report

Astrea G.¹, Cassandrini D.¹, Fiorillo C.², Frosini S.¹, Traverso M.², Rubegni A.¹, Savarese M.^{3,4,5}, Santorelli F.M.¹, Minetti C.²

¹ Department of Developmental Neuroscience and Molecular Medicine Neuromuscular Unit, IRCCS Stella Maris, Pisa; ² Center of Myology and Neurodegenerative Disorders, G. Gaslini Institute, Genoa; ³ Telethon Institute of Genetics and Medicine, Pozzuoli, Naples; ⁴ Dipartimento di Biochimica, Biofisica e Patologia Generale, Università degli Studi della Campania "Luigi Vanvitelli", Naples; ⁵ Folkhälsan Institute of Genetics, Haartman Institute, University of Helsinki, Helsinki, Finland

The 364-exon long TTN gene encodes titin, a muscular protein playing key structural, developmental, mechanical, and regulatory roles in heart and skeletal muscles.

Mutations in TTN cause heterogeneous phenotypes including isolated cardiomyopathies, pure myopathies, or infantile forms of heart and skeletal muscle involvement.

We describe a boy with severe congenital myopathy, without cardiac and respiratory involvement, in whom we identified bi-allelic truncating mutations in TTN.

The patient presented in early life with decreased fetal movements and neonatal hypotonia with poor antigravity motility. At first examination, at 11 months, the patient showed myopathic face and severe motor skill delay with proximal weakness of the upper and lower extremities, head drop and thoracic kyphosis with relatively preserved respiratory function. He also showed rigid spine and joint contractures at knee and ankles. Creatine kinase levels were normal. No heart defect were found.

Histological studies revealed important muscle fibrosis and fatty substitution. Fibers were mostly rounded and atrophic with several presenting centrally located nuclei and few perinuclear vacuoles. Western blotting showed a partial reduction of the expression of calpain.

Molecular studies identified the c.105832C > T/p.Q35278* in TTN in compound heterozygosity with the c.914 + 1G > C mutation. The first mutation occurred downstream of the TK encoding residues coding for the M-line; the novel splice-site lies in exon 6 whose functional significance to protein function is still unclear.

Although difficult to analyze, we encourage to screen for TTN in congenital myopathies even in the absence of cardiac and respiratory involvements in order to obtain a better definition of genotype-phenotype correlations.

Proposal of a cognitive approach to focus brain functioning in facioscapulohumeral muscular dystrophy (FSHD)

Baldanzi S., Ricci G., Torri F., Simoncini C., Siciliano G. Department of Clinical and Experimental Medicine, University of Pisa

Background and aims. Muscular dystrophies (MD) are genetic disorders affecting not only the muscles but also the brain. Mental disturbances heavily impact on patients' ability to display proper behaviour in everyday-life interactions.

The aim of the present research is to estimate the preva-

lence of cognitive impairment in a sample of FSHD patients, compared to a sex-and-age matched healthy-control (HC) group.

Methods. We consecutively enrolled and systematically analyzed motor disability pattern and cognitive performance in 23FSHD (mean age 50.2 + 11.5) patients. Patients underwent neurological evaluation, through the administration of Medical Research Council scale (MRC) and FSHD Comprehensive Clinical Evaluation Form (CCEF); a trained neuropsychologist assessed perception, memory, language, visuo-constructional and executive functions through a specific neuropsychological test battery and evaluated temperamental pattern.

Results. Psychological interview and clinical observation showed that 7 out of 23 patients presented with hyperthymic temperamental pattern; 3 patients presented a tendency towards depression, 8 patients presented with cyclothymic/anxious behavioural pattern.

Neuropsychological dysfunction was detected in mnesic (28.6% of patients), and visuo-constructive (14.3% of patients) domains; borderline executive functioning, involving mental flexibility and constructional skills was reported in 28.7% of patients.

Conclusions. In the last decade several evidences suggest that MDs could present with a broad psychopathological spectrum ranging from cognitive dysfunction to neuropsychiatric manifestations. It is suitable to strengthen research on central nervous system (CNS) involvement in FSHD, and in other MD forms as well, also encouraging the planning of non-pharmacological therapeutic strategies, such as cognitive training, as it has been recently stated in literature (Voet et al. 2014).

Lambert-Eaton myasthenic syndrome and igg4-related disease: a possible novel association

Baldelli E.¹, Borlenghi E.², Cotti Piccinelli S.¹, Caria F.¹, Marchesi M.¹, Gallo Cassarino S.¹, Padovani A.¹, Filosto M.¹

¹ ERN EURO-NMD Center for Neuromuscular Diseases, Unit of Neurology, ASST "Spedali Civili", Brescia, Italy; ² Unit of Hematology, ASST "Spedali Civili", Brescia, Italy

Lambert-Eaton myasthenic syndrome (LEMS) is a rare paraneoplastic (T-LEMS) or primary autoimmune neuromuscular junction disorder (NT-LEMS) characterized by proximal weakness, autonomic dysfunction and areflexia.

IgG4-Related Disease (IgG4-RD) is a chronic inflammatory condition characterized by tissue infiltration with lymphocytes and IgG4-secreting plasma cells, fibrosis and a usually prompt response to oral steroids. Seizures, cranial nerve palsies and sensorineural hearing loss have been described as possible neurological complications but an association with LEMS has ever been reported to date.

Here we report on a 44 year-old patient diagnosed with LEMS in 2010 because proximal limb muscle weakness, reduction of deep tendon reflexes, incremental cMAP response at high frequency repetitive nerve stimulation EMG and high titers of antibodies against voltage-gated calcium channels. No neoplasms were discovered at the subsequent follow-up.

In 2013, the patient started to complain of greater fatigability and fluctuating hypophony. A global reassessment displays pulmonary, retroperitoneal and para-splenic lesions associated with thrombocytopenia, microcytic anemia, purpuric pigmented dermatitis and splenomegaly. Histopathological features

confirm a diagnosis of IgG4-RD and a treatment with oral prednisone obtained a significant improvement of systemic picture and neurological symptoms.

The relation between LEMS and IgG4-RD in this patient remains speculative; however, our report emphasizes the possibility that IgG4-RD, similarly to other immune-mediated disorders, could be associated with NT-LEMS and suggests to look for this syndrome in NT-LEMS patients.

FIREFISH part 1: RG7916 significantly increases SMN protein in SMA type 1 babies

Baranello G.¹, Servais L.², Day J.W.³, Deconinck N.⁴, Mercuri E.⁵, Klein A.⁶, Darras B.⁷, Masson R.¹, Kletzl H.⁸, Cleary Y.⁸, Armstrong G.⁹, Seabrook T.⁸, Czech C.⁸, Gerber M.⁸, Gelblin K.⁸, Gorni K.⁸, Khwaja O.⁸

¹ Carlo Besta Neurological Research Institute Foundation, Developmental Neurology Unit, Milan, Italy; ² Institute of Myology, Paris, France; ³ Reference Center for Neuromuscular Disease, Centre Hospitalier Régional de La Citadelle, Liège, Belgium; ⁴ Department of Neurology, Stanford University, Palo Alto, CA, USA; ⁵ Queen Fabiola Children's University Hospital, Université Libre de Bruxelles, Brussels, Belgium - Neuromuscular Reference Center UZ Ghent, Ghent, Belgium; ⁶ Paediatric Neurology and Nemo Center, Catholic University and Policlinico Gemelli, Rome, Italy; ⁷ University Children's Hospital Basel, Basel, Switzerland - Inselspital, Bern, Switzerland; ⁸ Boston Children's Hospital, Harvard Medical School, Boston, MA, USA; ⁹ Roche Pharmaceutical Research and Early Development, Roche Innovation Center Basel, Basel, Switzerland; ⁹ Roche Products Ltd, Welwyn Garden City, UK

Spinal muscular atrophy (SMA) is caused by reduced levels of survival of motor neuron (SMN) protein from loss of function of the SMN1 gene. A second gene, SMN2, produces only low levels of functional SMN protein. RG7916 (RO7034067) is an investigational, orally administered, centrally and peripherally distributed small molecule that modulates SMN2 pre-mRNA splicing towards the production of full-length SMN2 mRNA and increase of SMN protein. We present interim data from part 1 of FIREFISH – an ongoing, multicenter, open-label, two-part, seamless study of RG7916 in babies aged 1-7 months with Type 1 SMA (two SMN2 copies) –.

Exploratory Part 1 of FIREFISH (n = 21) assessed safety, tolerability, pharmacokinetics and pharmacodynamics of RG7916 at different dose levels. A dose-dependent increase in SMN protein levels in whole blood was observed (up to 6.5-fold increase vs. baseline after 4 weeks of the highest RG7916 dose [range 2.0-6.5]). To date, no protocol-defined safety-related stopping rules have been met, and loss of ability to swallow, tracheostomy or permanent ventilation have not been reported. Confirmatory part 2 (n = 40) will assess safety and efficacy of RG7916.

The up to 6.5-fold increase in SMN protein levels observed in FIREFISH Part 1 is expected to lead to clinical efficacy based on differences in SMN protein levels between SMA severity types (e.g. type 2 vs type 1). All doses explored so far have been well tolerated. Part 2 of the FIREFISH study is ongoing.

Potassium-aggravated myotonia: a rare disease successfully managed by dietary restriction

Barbone F.¹, Vitale M.¹, Telese R.¹, Ferrante C.¹, Di Stefano V.¹, Di Muzio A.²

¹ Department of Neurosciences, Imaging and Clinical Sciences, University G.d'Annunzio of Chieti-Pescara, Chieti; ² Center for Neuromuscular Disease, CeSI, University "G. D'Annunzio", Chieti, Italy

A 48-years old male was admitted to our department because of an history of muscular cramps exacerbated by cold and fatigue, muscle pain and stiffness since he was eighteen. Neurological examination revealed diffuse muscular hypertrophy, slight lid-lag sign, no myotonic phenomenon nor muscular weakness. His father and daughter experienced the same symptoms. Electromyography showed no nerve conduction velocities abnormalities and absence of myotonic discharges. Biceps biopsy was negative. Cardiologic assessment and serum electrolytes were normal. He sustained a double-fold increase in serum creatine kinase (260 U/l). During hospitalization different challenge tests were performed: serum sodium, potassium and creatine kinase were dosed before and after a 10 minutes-exercise and no variations in their levels were noticed; his left hand was cooled by immersion in ice for 3 minutes, triggering pain and slight deficit in muscular strength; a K⁺ load was administered with appearance of lower limb pain and gastrocnemius fasciculations.

A consistent improvement with acetazolamide (250 mg b.i.d) was obtained, while he developed tachycardia with mexiletine. After abolishment of potassium-rich food, patient did not present other attacks, allowing him to discontinue acetazolamide therapy.

Thereby, potassium aggravated myotonia (PAM) was diagnosed. PAM is a rare non-dystrophic myotonia (incidence < 1:1,000,000) characterized by spontaneous, intermittent potassium-induced weakness secondary to skeletal muscle fibers inexcitability. Clinical presentation includes myotonia fluctuans, myotonia permanens and acetazolamide-responsive myotonia, with an autosomal dominant inheritance of SCN4A gene missense mutations.

Genetic association study of articular range of motion in the CINRG Duchenne Natural History Study

Bello L.¹, Duong T.², Henricson E.³, Hoffman E.P.⁴, McDonald C.M.³, Gordish-Dressman H.⁵, CINRG Investigators

¹ Department of Neurosciences DNS, University of Padova, Padova, Italy; ² Neurology Department, Stanford University, Palo Alto, CA, USA; ³ University of California Davis Medical Center, Sacramento, CA, USA; ⁴ Research Center for Genetic Medicine, Children's Research Institute, Children's National Health System, Washington, DC, USA; ⁵ Binghamton University, SUNY, Binghamton, NY, USA

Joint contractures in Duchenne muscular dystrophy (DMD) vary considerably despite comparable muscle weakness. We carried out a genetic association study of contracture severity in participants enrolled in the CINRG Duchenne Natural History Study.

We genotyped 109 participants of European American an-

cestry with the Illumina Exome chip. A minor allele frequency (MAF) cut-off of 0.05 was adopted in association analyses. Range of motion (ROM) was assessed using a standard goniometer. Contractures were measured on the dominant side: elbow extension (EE, ROM available in n = 104 individuals), wrist extension (WE, n = 104), knee extension (KE, n = 62), and ankle dorsiflexion (AD, n = 61). Articular ROM was linearly regressed on genotype, with Brooke Upper Extremity score and Vignos lower extremity score as covariates, in order to adjust for muscle weakness in upper or lower limbs. A Bonferroni correction for 27,025 SNPs with MAF > 0.05 was applied, leading to an "exome-wide" statistical significance threshold of $P = 1.85 \times 10^{-6}$. A more permissive "suggestive" threshold of $P = 10^{-4}$ was also considered.

A significant association signal ($P = 1.36 \times 10^{-7}$) was observed for the AD phenotype, corresponding to rs12506517, 70 kb upstream of BANK1 (B Cell Scaffold Protein With Ankyrin Repeats 1), encoding a B-cell-specific scaffold protein that mobilizes Ca⁺⁺ from intracellular stores and promote phosphorylation of inositol 1,4,5-trisphosphate receptors. Several "suggestive" signals were observed, including SNPs within FAM26F (another Ca⁺⁺ homeostasis regulator), DST (dystonin), DYSF (dysferlin), and LTBP4 (latent TGF-beta binding protein 4).

These findings suggest a putative role of SNPs in Ca⁺⁺ homeostasis genes and other genes in predisposing DMD patients to contractures.

Fibrodysplasia ossificans progressive, a rare disease: a case report

Bonanno C., Musumeci O., Vita G., Brizzi T., Toscano A., Rodolico C.

Department of Clinical and Experimental Medicine, Neurology and Neuromuscular disorders Unit, University of Messina

Fibrodysplasia ossificans progressive (FOP), previously known as "myositis ossificans", is a rare and disabling disease that occurs approximately 1:2000000. It is usually caused by a sporadic mutation in the Activin A receptor type I/activin-like kinase 2 (ACVR1/ALK2) gene. FOP is clinically characterized by a progressive heterotopic ossification, spontaneous or secondary to trauma, and peculiar skeletal malformations. The median lifespan is approximately 40 years. Patients are usually wheelchair-bound by the end of the second decade of life and commonly die of respiratory insufficiency. We report on a case of a 47-year-old man who received a diagnosis of suspected FOP at 15 years of age because of the presence of multiple neck bony masses. When he came to our observation he complained muscle pain and swelling at cervical region and difficulty to walk. At the neurological examination he showed muscle weakness at the limb girdle muscles. Physical examination evidenced a severe scoliosis, multiple bony masses and bilateral hallux valgus with microdactyly of the big toes. Creatine kinase was normal whereas alkaline phosphatase was elevated (370 U/l-n.v. < 270 U/l). Clinical and laboratory features suggested a FOP. Invasive tests as muscle biopsy and electromyography, were avoided. A genetic test was performed and a heterozygous mutation of ACVR1/ALK2 gene (R206H) was found, confirming the diagnosis of FOP. In conclusion, FOP is a very rare disease; it is important to know its clinical and physiopathological aspects to timely diagnose it, to avoid invasive and dangerous investigations and to properly manage the disease course.

A novel Emerin mutation in a patient with early onset Emery-Dreifuss muscular dystrophy

Bozzetti S.¹, Vattemi G.¹, Rimessi P.², Macchione F.¹, Pancheri E.¹, Guglielmi V.¹, Ferlini A.², Tonin P.¹

¹ Department of Neurosciences, Biomedicine and Movement Sciences, Section of Clinical Neurology, University of Verona, Verona, Italy; ² Department of Medical Sciences, Unit of Medical Genetics, University of Ferrara, Ferrara, Italy

Emery Dreifuss muscular dystrophy (EDMD) is an inherited myopathy clinically characterized by early contractures, slow progressive muscle weakness with a humeroperoneal distribution pattern, and cardiac involvement leading to conduction defect, dilated cardiomyopathy and sudden death. To date at least seven genes have been associated to EDMD with different inheritance patterns, the most frequent being emerin gene located at Xq28 (EMD). The diagnosis is based essentially on clinical findings and is confirmed by ancillary tests including neurophysiological studies and muscle biopsy. We report a 40-year-old man who was referred for severe gait difficulty. At the age of 5 years the patient presented with a waddling gate, heel contractures, peculiar involvement of intrinsic hand and facial muscles. Both electrophysiology and muscle biopsy were consistent with a neurogenic disorder and he received a diagnosis of SMA. Afterward SMN gene analysis did not identify any mutation. At the age of 37 the patient developed heart involvement with spontaneous rupture of chordae tendineae. A new clinical examination showed severe muscular weakness and atrophy in humeroperoneal pattern of distribution, needle electromyography confirmed neurogenic features and on a second muscle biopsy emerin was absent by immunohistochemistry and by immunoblot analysis. Sequence analysis of EMD gene revealed the presence of a novel mutation represented by an out-of-frame deletion spanning from the beginning of exon 1 to the half of intron 2, therefore involving exon 1, intron 1, the whole exon 2 and part of intron 2.

Nivolumab-induced acute rabdomyolysis and myasthenic syndrome

Bozzoni V.¹, Lelli S.², Rosso T.², Semplicini C.¹, Bello L.¹, Maccarrone G.², Vicario G.³, Salmaso F.³, Risato R.⁴, Tassinari C.⁴, Costa R.⁵, Cenacchi G.⁵, Pegoraro E.¹

¹ Neuromuscular Unit, Department of Neuroscience, University of Padova, Italy; ² Neurology Unit, Castelfranco Veneto Hospital, Italy; ³ Oncology Unit, Castelfranco Veneto Hospital, Italy; ⁴ Hematology Unit, Castelfranco Veneto Hospital, Italy; ⁵ Biomedical and Neuromotor Sciences Department, University of Bologna, Italy

To report muscle histopathology and clinical features in a patient treated with nivolumab, an immune checkpoint inhibitor, who experienced acute rabdomyolysis and myasthenic syndrome.

A 61 years old man, affected by advanced NSCLC (non-small cell lung cancer), was treated with nivolumab at standard dosage. Ten days after the first nivolumab administration, the patient complained of myalgias and developed a generalized myasthenic syndrome with severe bulbar involvement.

He subsequently developed a severe cardiac conduction block that required a pacemaker implantation. A diagnosis of rabdomyolysis, myasthenic crisis, and myocarditis was done on the basis of the clinical presentation, CK levels (> 10.000 U/L) and the presence of high myoglobin level in the urine. Neurophysiological studies were normal. A diagnostic muscle biopsy was done two months after symptoms onset. The patient was

treated with pyridostigmine, methylprednisolone, i.v. immunoglobulin therapy and 24 courses of plasma-exchange with progressive clinical improvement.

Muscle biopsy revealed the presence of multiple vacuoles in numerous muscle fibers, mainly in type 1 fiber. Acid phosphatase shows autophagic vacuoles in the vast majority of the muscle fibers, suggesting lysosomal origin. No inflammatory cells have been observed.

Immune checkpoint inhibitors induce durable anti-tumor immune responses but are associated with severe immune-related adverse events (ir-AEs). Rhabdomyolysis, myositis, myasthenic syndrome have already been reported but extensive histopathology characterization of muscle biopsy are lacking. ir-AEs may be life-threatening but potentially treatable, thus they need to be recognized as soon as possible and need to be treated as aggressive as the advanced cancer.

Novel homozygous mutation in mitochondrial translation elongation factor EFTs (TSFM) in an Italian child with mitochondrial encephalopathy and hypertrophic cardiomyopathy

Brigati G.¹, Fiorillo C.², Nesti C.³, Rubegni A.³, Bruno C.¹, Severino M.S.⁴, Minetti C.², Santorelli F.M.³

¹ Centro di Miologia Traslazionale e Sperimentale, Istituto G.Gaslini, Genova; ² Neurologia Pediatrica e Malattie Muscolari, Istituto G.Gaslini e Università di Genova, Genova; ³ Laboratorio Medicina Molecolare, IRCCS Stella Maris, Calambrone, Pisa; ⁴ Neuroradiologia, Istituto G.Gaslini, Genova

Mitochondrial translation elongation factor EFTs (TSFM) encodes for one of the mitochondrial elongation factors, which are essential for translation of mtDNA-encoded proteins. TSFM mutations result in reduced mitochondrial translation and have been described in a few patients presenting childhood or juvenile-onset nervous system phenotypes, with or without cardiomyopathy and multiple respiratory chain (OXPHOS) deficiencies.

We present a 6 years old child with global developmental delay, hypotonia and hypertrophic non-obstructive cardiomyopathy. Patient presented first metabolic crisis at 3 months of age with severe acidosis. MRI documented white matter lesions in the frontal, parietal and occipital areas. One year later further hyperintense lesions in the lenticular nuclei appeared at MRI. Last MRI showed resolution of the lesions and presence of cerebellar atrophy. Cardiac assessment revealed diffuse hypertrophy of the left ventricular walls and septum, with progression over time. Last neurological evaluation displayed severe speech and psychomotor delay, global hypotonia with pyramidal signs. Mild dysmetria of upper limbs and ataxic gait were also observed.

Muscle biopsy performed at 10 months showed several ragged red fibres, reduction of COX staining with increase SDH staining in few fibres, several subsarcolemmal COX hyperactivity and lipid vacuoles. Measurement of OXPHOS activities revealed significant reduction of COX activity, thus confirming a mitochondrial pathology.

Using a multigene panel in NGS we identified a homozygous mutation in TSFM that is highly conserved throughout evolution.

The description of an additional TSFM patient with longitudinal follow up, could contribute to a better definition of the genotype-phenotype correlations in TSFM associated disorders.

Progressive respiratory failure: an unusual polymyositis

Brizzi T.^{1,2}, Lupica A.¹, Gaeta M.³, Vita G.¹, Toscano A.¹, Rodolico C.¹

¹ Department of Clinical and Experimental Medicine, University of Messina, Italy; ² DIBIMIS, University of Palermo, Italy;

³ Department of Biomedical Science and Morphological and Functional Images, University of Messina, Italy

Introduction. Polymyositis (PM) is an inflammatory myopathy characterized by progressive and symmetric weakness, predominantly proximal, with sparing of extraocular muscles.

Main histological features are fiber size variability, scattered necrotic and regenerating fibers and perivascular and endomysial cellular infiltrates.

Methods. We present the case of a patient who suffered from the age of 44 years from breathing shortness. At the age of 47, he came to our observation because of elevated CK levels (950 UI), diurnal drowsiness and severe dyspnea. At neurological examination, he showed a mild waddling gait and upper limbs proximal weakness.

Several diagnostic examinations were performed such as electromyography, muscular magnetic resonance (MRI) of diaphragm and upper limbs, muscle biopsy, and pneumological evaluation with spirometry, nocturnal saturimetry and polysomnography.

Results. EMG displayed a myopathic pattern. Muscle MRI pointed out edema of the upper limbs and diaphragmatic muscle; specific sequences showed a severe reduction of the diaphragmatic excursion. Pulmonary evaluation showed a severe restrictive syndrome, hypercapnia with nocturnal desaturation and a high Apnea Hypopnea Index (49.5). Muscle biopsy showed fiber size variability, scattered necrotic and regenerating fibers, with a perivascular and endomysial cellular infiltrates, suggesting an inflammatory disease. He started Prednisone 75 mg/die and Azathioprine 100 mg/die. 3 months after the beginning of the therapy the patient showed a clinical improvement confirmed at the muscular MRI that pointed out a drastic reduction of the edema even in the diaphragm.

Conclusions. Hypercapnic respiratory failure due to respiratory muscle involvement as a PM presentation is a very rare event and it is described in less than 10% of patients with inflammatory myopathies (Schwarz MI Clin Chest 1998). In our patient progressive hypercapnic respiratory failure led to a diagnosis of PM and the muscular and diaphragmatic MRI revealed itself as a useful tool for the diagnosis and the follow up.

Methotrexate as steroid-sparing agents in patients with myasthenia gravis

Brizzi T.^{1,2}, Lupica A.¹, Messina S.¹, Toscano A.¹, Rodolico C.¹

¹ Department of Clinical and Experimental Medicine, University of Messina; ² DIBIMIS, University of Palermo

Introduction. Myasthenia gravis (MG) is an autoimmune disorder of neuromuscular junction. Therapy for MG is still debated and controversial: corticosteroids alone or in combination with immunosuppressive agents are the most used drugs. Azathioprine (AZA) has been shown to be effective for MG in randomized placebo-controlled studies with a significant steroid-sparing activity after 15 months administration although several side effects [1].

Recently, some studies on Methotrexate (MTX) activity in MG have evidenced controversial results on efficacy, tolerability and steroid-sparing activity.

Patients and methods. We have retrospectively evaluated in our MG cohort of (over 850 pts), a number of patients treated with MTX and its efficacy as a steroid-sparing agent. 8 patients, previously treated with AZA and prednisone with uncomfortable side effects (AZA related), were then cured with a combination of MTX (median dose: 15 mg per week) and prednisone (PDN: median dose 40 mg/die). Mean clinical follow up was about 8 years (from 5 to 10 years). Each patient was evaluated 2/4 times per year by MG-Activity of daily living (MG-ADL) and Quantitative Myasthenia Gravis scores (QMG).

Results. We found that patients treated with MTX had a significant improvement on the MG-ADL and QMG scores. Furthermore, all of them gradually reduced the PDN dosage with a mean of 15 mg per day. None of patients complained of side effects.

Conclusions. Some recent MTX trials ended with controversial results as steroid-sparing agent compared to AZA. Our data, although observed in a limited number of MG subjects, suggests that MTX is effective and well tolerated and can be considered as an alternative steroid-sparing agent.

One mutation, two phenotypes: role of muscle biopsy

Bruno G.¹, Allegorico L.¹, Di Iorio G.¹, Sampaolo S.¹, Varone A.²

¹ Second Division of Neurology, University of Campania "Luigi Vanvitelli, Naples, Italy; ² Department of Pediatric Neurosurgery, Santobono-Pausilipon Children's Hospital, Naples, Italy

Background. Duchenne muscular dystrophy (DMD) is a X-linked disorder caused by open reading frame disrupting mutations in the DMD gene, resulting in strong reduction or complete absence of dystrophin.

Methods. A 6 year old patient was admitted to pediatric clinic complaining about proximal muscle weakness, his motor milestones were delayed and he had also speech delay. His uncle, a 44 year old man, came to our department for the finding of hyperCKemia at routine blood tests, he referred mild hyposthenia after extended clinical effort since six months. They underwent to a clinical protocol for neuromuscular diseases including blood tests, electroneuromyography (ENMG) and genetic testing for dystrophinopathy.

Results. The first genetic assessment for deletion/duplication of dystrophin gene was negative. They practiced muscular biopsy revealed dystrophic changes, but the immunostaining showed a different pattern of dystrophin in the two patients. Then we request a second level genetic analysis that found a rare nonsense mutation in exon 29 c.3940C > T p. (Arg1314Ter) resulting in variable phenotypes. This mutation has never been described in male adult patient until now.

Conclusions. Nonsense mutations in the dystrophin gene usually result in a severe Duchenne muscular dystrophy phenotype. Only six case reports of exon 29 nonsense mutations in the literature and each of them describe an encouraging milder phenotype. The variant in our patients is extremely rare and is predicted to produce a truncated dystrophin leading to a severe phenotype. Some cases of muscular dystrophy may still require muscle biopsy to determine optimal management and pharmaceutical treatment options.

Myasthenia gravis: epidemiologic features, clinical course, and treatment approaches in two Ligurian centers

Cabona C.¹, Gemelli C.¹, Fabbri S.¹, Benedetti L.^{1,2}, Caponnetto C.¹, Mancardi G.L.¹, Mannironi A.², Beronio A.², Schenone A.¹, Grandis M.¹

¹ Department of Neuroscience, Rehabilitation, Ophthalmology, Genetics, Maternal and Child Health (DINOGMI), University of Genova and IRCCS, Policlinico San Martino, Genova; ² Department of Neurology, Osp. S. Andrea, La Spezia

The purpose of this study was to investigate the epidemiological, clinical characteristics and therapeutic data of patients affected by Myasthenia Gravis (MG), recruited from two neuromuscular outpatient clinics (Polyclinic San Martino Hospital in Genova and S. Andrea Hospital in La Spezia).

A total of 212 patients were included, 107 men and 105 women with a mean age of onset of 64.47 years for men and 56.78 years for women. Mean time delay between onset of symptoms and diagnosis was 10.29 months, with 58% receiving the diagnosis within the first month. The age distribution confirmed a bimodal pattern in women (40% under 50 years, 60% over), while a clear prevalence of late onset MG in men (87% over 50s). The generalized form of MG (64.6%) prevails in women (56.2%) while the ocular form (35.4%) is prevalent in men (62.7%). Anti-AchR antibody were found in 94 cases, 72% in the generalized form and 28% in the ocular form. Regarding the MGFA classification, we noted a clear prevalence of the low grades (I, II) – 79.2% – compared to high grades (III, IV, V) – 20.8% –.

Both IVIg and Plasmapheresis were effective (85%) in acute relapses, while considering chronic immunosuppressants, 84 patients were treated with Azathioprine, 9 with Mycophenolate Mofetil, 7 with Cyclophosphamide, 7 with Cyclosporine, 4 with Methotrexate, 2 with Rituximab and 1 with Belimumab. A restricted group of patients receives IVIG as maintenance therapy and 4 of them have been recently switched to subcutaneous administration with good response.

New biomarkers in amyotrophic lateral sclerosis: analysis of the biophysical properties and gene expression in skeletal muscle of a transgenic mouse model

Camerino G.M.¹, Fonzino A.¹, Conte E.¹, Liantonio A.¹, De Bellis M.¹, Dobrowolny G.², Musarò A.², De Luca A.¹, Pierno S.¹

¹ Section of Pharmacology, Dept. of Pharmacy & Drug Sciences, University of Bari, Italy; ² DAHFMO-Unit of Histology and Medical Embryology, IIM, Sapienza University of Rome, Italy

Amyotrophic lateral sclerosis (ALS) is characterized by motor-neuron injury. Transgenic animals, carrying mutations in the SOD1 gene, develop similar symptoms than those observed in ALS patients. The role of skeletal muscle in the pathogenesis of ALS is still debated. Here we studied skeletal muscle functions in SOD1G93A animal model and in MLC/SOD1G93A, a transgenic animal model in which the mutated SOD1 is expressed exclusively in skeletal muscle. We found that resting chloride conductance (gCl), sustained by the CIC-1 channel, was strongly reduced and the potassium conductance was increased in SOD1G93A mice, as compared to wild-type. Sarcolemma excitability, evaluated

as the maximum number of action potentials, was accordingly increased in SOD1G93A muscle fibers. Resting intracellular calcium level was increased in these animals and an altered response to caffeine was found. Similar modifications were observed in skeletal muscle of MLC/SOD1G93A animals. To gain insight into the mechanism of these alterations, we also measured the mRNA expression of ion channels. The CIC-1 expression was significantly decreased only in muscles of SOD1G93A mice. Although the CIC-1 expression did not change in muscles of MLC/SOD1G93A mice, the expression of the protein kinase C (PKC), known CIC-1 channel modulator, was significantly increased, suggesting its higher activity in the phosphorylation and closure of CIC-1 channels. In parallel, chelerythrine, a PKC inhibitor, restore gCl in these mice. Our results strengthen the evidence for the role of skeletal muscle in ALS pathogenesis, paving the way for the development of new drugs to hamper the clinical effects of the disease.

Electrocardiographic evaluation in patients with spinal muscular atrophy: a case-control study

Catanzaro S.¹, Falsaperla R.², Vitaliti G.², Collotta A.D.¹, Fiorillo C.³, Pulvirenti A.⁴, Alaimo S.⁴, Romano C.², Ruggieri M.¹

¹ Unit of Rare Diseases of the Nervous System in Childhood, University of Catania, Italy; ² Unit of General Pediatrics and Emergency Pediatrics, University Hospital "Policlinico-Vittorio Emanuele", Catania, Italy; ³ Unit of Paediatric Neurology and Muscle Diseases, G. Gaslini Institute, Genoa, Italy; ⁴ Department of Clinical and Experimental Medicine, Section of Bioinformatics, University of Catania, Italy

The objective of our study was to show the impairment of autonomic cardiac conduction driving to bradycardia and/or electrocardiographic alterations in children affected by SMA1 and 2.

Methods. We included 25 spinal muscular atrophy patients, admitted from November 2016 to May 2017. All patients underwent an electrocardiographic examination and we studied PR and QRS intervals, P-waves and QRS amplitudes, and heart rate in spinal muscular atrophy patients compared to a control group.

In our study we found significant differences in the EKG measures between SMA children and controls. In regards, in all SMA patients we found longer PRi and QRSi ($p < 0.05$), lower P-wave and QRS complex amplitudes ($p < 0.01$) and a decreased heart rate ($p < 0.01$) with respect to controls. Moreover, when we divided our patients in SMA1 and SMA2 subgroups, we found that statistical differences were maintained for P-wave and QRS complex amplitudes and HR, but no statistical difference was observed for PRi and QRSi with respect to controls.

Even though SMA has always been considered a disease with severe and progressive weakness, in this paper we show an evidence that the heart is also affected.

Conclusions. We suggest the hypothesis of SMN expression on cardiac tissue condition and /or autonomic cardiac conduction.

JEWELFISH: RG7916 increases SMN protein in patients with SMA that have previously received therapies targeting SMN2 splicing

Chiriboga C.¹, Mercuri E.², Fischer D.³, Kraus S.⁴, Thompson N.⁴, Armstrong G.⁵, Kletzl H.⁴, Gerber M.⁴, Cleary Y.⁴, Bergauer T.⁴, Gorni K.⁴, Khwaja O.⁴

¹ Columbia University Medical Center, New York, NY, USA;

² Paediatric Neurology and Nemo Center, Catholic University and Policlinico Gemelli, Rome, Italy; ³ Department of Neurology, University of Basel Hospital, Basel, Switzerland; ⁴ Roche Pharmaceutical Research and Early Development, Roche Innovation Center Basel, Switzerland; ⁵ Roche Products Ltd, Welwyn Garden City, United Kingdom

Spinal muscular atrophy (SMA) is a rare hereditary neuromuscular disease caused by loss of function of the survival of motor neuron 1 (SMN1) gene. While SMN1 produces full-length SMN protein, a second gene, SMN2, produces low levels of functional SMN protein due to alternative splicing of SMN2 pre-mRNA. RG7916 is an orally administered, centrally and peripherally distributed SMN2 pre-mRNA splicing modifier that increases SMN protein levels.

JEWELFISH is a multicenter, open-label, exploratory study evaluating the safety, tolerability and pharmacokinetics (PK) of daily oral RG7916 in patients with type 2 or 3 SMA, age 12-60 years, who previously participated in a study with therapies targeting SMN2 splicing. The pharmacodynamic (PD) effects on SMN protein are also assessed.

At the time of abstract submission, 11 patients have received RG7916 (≥ 3 weeks and ≤ 13 months). To date, RG7916 has been well tolerated, with no drug-related safety findings leading to withdrawal in any SMA patient exposed to RG7916. Preliminary data in whole blood from 10 patients receiving RG7916 showed an up to 4-fold SMN protein increase over 4 weeks. A JEWELFISH update including safety and available biomarker data will be presented.

JEWELFISH is currently recruiting in sites across Europe and the US. Together with the ongoing SUNFISH (type 2 and 3 SMA) and FIREFISH (type 1 SMA) studies, JEWELFISH will provide valuable insights into the safety, tolerability, PK and PD of daily oral RG7916.

Severe nemaline myopathy manifesting as 'Amish phenotype' related to homozygous mutation in TNNT1

D'Amico A.¹, Fattori F.¹, Fiorillo C.², Verardo M.¹, Catteruccia M.¹, Bellacchio E.³, Bruno C.², Moggio M.⁴, Bertini E.¹

¹ Unit of Neuromuscular and Neurodegenerative Disorders, Dep of Neurosciences, Bambino Gesù Children's Hospital, Rome;

² Center of Myology and Neurodegenerative Disease, Istituto Giannina Gaslini, Genova, ³Molecular Genetics and Functional Genomics, Genetics and Rare Diseases Research Area, Bambino Gesù Children's Hospital, Rome, ⁴Neuromuscular and Rare Disease Unit, Department of Neuroscience, IRCCS Foundation Ca' Granda Ospedale Maggiore Policlinico, University of Milan

Amish nemaline myopathy is a severe form of nemaline myopathy (NM) common among the Old Order Amish. The phenotype is characterized by early onset of severe hypotonia and mild contractures of the shoulders and hips. Progressive worsening of the proximal contractures, weakness, and a pectus carinatum deformity develop before the children die of respiratory insufficiency, usually by the second year of life. This

phenotype has been associated to the p.Glu180Ter mutation in exon 11 of TNNT1 (TnT). We report on two Italian siblings affected by a severe form of congenital myopathy with a clinical picture very similar to the Amish phenotype. Both girls actually aged 12 and 1 years, by the age of 3 months, started to manifest rapid and progressive muscle weakness that predominantly involved distal muscles, associated to severe chest deformity (pectus carinatum) rigid spine and respiratory insufficiency that required mechanical ventilation in the first year of life. A muscle biopsy, performed in the older sister at the age of 7 months was consistent with a NM. Next generation sequencing approach revealed a biallelic c.661G > T mutation in exon 12 of TNNT1 converting the Glu221 to a premature stop codon. The deletion of the C-terminal 58 aminoacids of TnT causes a loss of the binding sites for the Troponin inhibitory subunit (TnI) and the Troponin Ca²⁺ binding subunit (TnC) in the T2 region of TnT. The phenotype described in the Amish community is not a distinct myopathy associated exclusively to the founder Glu180Ter TNNT1 Mutation.

The natural history of respiratory function in a cohort of patients affected by spinal muscular atrophy type 2 and 3

D'Amico A.¹, Pedemonte M.², Catteruccia M.¹, Longo A.¹, Brigati G.³, Tacchetti P.², Bruno C.³, Bertini E.¹

¹ Unit of Neuromuscular and Neurodegenerative Disorders, Bambino Gesù Children's Hospital, Rome; ² Unit of Pediatric Neurology and Muscle Disease, and ³ Center of Translational and Experimental Myology, Istituto Giannina Gaslini, Genova

Introduction. Restrictive respiratory insufficiency is one of the main causes of morbidity in patients affected by spinal muscular atrophy (SMA). The aim of the study was to describe the natural history of the respiratory involvement in patients with SMA type 2 and 3 over time and to design the trajectories of decline of the forced vital capacity (FVC) over time, as well. **Methods:** we retrospectively reviewed the longitudinal evaluation of FVC assessments of SMA patients type 2 and 3 followed in our neuromuscular clinics between 2011 and 2017. For each patients we considered at least one measurement for year. **Results:** we collected FVC assessments of 45 SMN patients (22 type 2 and 23 type 3), aged 5-25 years (median age was 13 for SMA type 2 and 15 for SMA type3). Most of SMA type 2 patients had a FVC < 70% of predicted normal at baseline and had a high mean decline in pulmonary function over time. Conversely, patients with SMA type 3 had FVC $\geq 70\%$ of predicted normal at baseline and showed low decline over time. **Conclusion:** our results show a worsening of respiratory function in both SMA type 2 and 3 patients but underlie the earlier decline of FVC in patients classified as SMA type 2 as compared with patients classified as type 3.

Translarna therapy in Duchenne manifesting carriers due to stop codon dystrophin gene mutations. A case report

D'Ambrosio P.¹, Nigro V.², Politano L.¹

¹ Cardiomiologia e Genetica Medica, Dipartimento di Medicina Sperimentale, Università della Campania e Azienda Ospedaliera Universitaria "Luigi Vanvitelli", Napoli, Italy; ² Laboratorio di Genetica Medica, Università della Campania e Azienda Ospedaliera Universitaria "Luigi Vanvitelli", Napoli, Italy

Duchenne muscular Dystrophy (DMD) is a X-linked de-

generative disorder affecting skeletal muscles and myocardium due to mutations in the dystrophin gene, notably deletions, duplications and point-mutations. DMD female carriers are usually asymptomatic. However a few percentage may present symptoms at both skeletal muscle and cardiac level, that have been related to a skewed X-chromosome inactivation (XCI). Symptoms appear early, in the first decade of life, in girls with a XCI of the wild allele > 80%.

A drug treatment for patients with DMD caused by stop codon gene mutations, still ambulant, has become recently available, based on the clear demonstration of its efficacy in slowing the course of the disease. The drug is able to read through the stop codons with the advantage of oral administration and better patient's compliance.

We report the case of a still ambulant 24 year-old DMD manifesting carrier with a stop-codon in exon 53 (c.7792C > T; p.Gln2598Stop), who began the treatment with Translarna in October 2017, at a dosage of 2,250 mg/die. The pre-treatment evaluation showed the following results: 6MWT: 100 meters; NSAA: 3/34; PUL: 55/80. A subjective improvement of the strength was reported. Unfortunately at the beginning of December 2017, the patient had a traumatic fracture of the right femur that required surgical repair and prolonged rehabilitation. She discontinued taking the drug during this period and started taking it again on February 10th 2018. At the control of end of March, she was able to stand up and take a few steps indoor. NSAA and PUL were unchanged.

Efficacy of Coenzyme Q10 in patients with dystrophinopathic cardiomyopathy

D'Ambrosio P., Palladino A., Scutifero M., Petillo R., Orsini C., Passamano L., Politano L.
Cardiomiologia e Genetica Medica, Dipartimento di Medicina Sperimentale, Università della Campania e Azienda Ospedaliera Universitaria "Luigi Vanvitelli", Napoli, Italy

Dystrophinopathic cardiomyopathy is a common feature in patients with Duchenne (DMD) and Becker (BMD) muscular dystrophy that occurs due to myocardial replacement by fat and fibrosis.

Coenzyme Q10 (CQ10), or ubiquinone, is a fat-soluble molecule that acts as an electron mobile carrier in mitochondria and as a coenzyme for mitochondrial enzymes.

At the heart level, Coenzyme Q10 plays a central role in production of bioenergy in myocardium and as an antioxidant in reperfusion condition of myocardial damaged muscle, leading to membrane stability and prevention of cell death.

Based on its fundamental role in mitochondrial bioenergetics and well-acknowledged antioxidant properties, several clinical trials evaluating CoQ10 have been undertaken in cardiovascular disorders including chronic heart failure, hypertension, and endothelial dysfunction. Our objective was to determine if CQ10 can ameliorate myocardial hypoperfusion and improve heart function in patients with dystrophinopathic cardiomyopathy.

To this aim 24 Duchenne, 18 Becker patients and 8 DMD carriers showing repolarization anomalies at standard ECG were given Coenzyme Q10 therapy supplementation, at a dosage of 100 mg/die, in addition to standard therapy with ACE-inhibitors.

The results show a different response of patients to the drug related to the type of diagnosis (DMD, BMD or DMD carrier), the severity of cardiomyopathy and the precocity of the treatment.

How respiratory muscle strength correlates with cough capacity in patients with myotonic dystrophy

De Mattia E., Pirola A., Lizio A., Mollar E., Roma E., Falcier E., Rao F., Sansone V.
NeuroMuscular Omnicentre (NEMO), Fondazione Serena Onlus, Milan, Italy

Purpose. The purpose of this study is to investigate how respiratory muscle strength correlates to cough capacity in patients with myotonic dystrophy (MD) type 1 and 2.

Materials and methods. A cohort of patients with MD was recruited. Pulmonary function tests, including forced vital capacity (FVC), peak expiratory flow (PEF), peak cough expiratory flow (PCEF) and respiratory muscle strength (maximal expiratory pressure, MEP; maximal inspiratory pressure, MIP; sniff nasal inspiratory pressure, SNIP) were performed. The correlations between respiratory muscle strength (MIP, MEP and SNIP) and Peak Cough Flow (PCF) were analysed.

Results. 32 patients were enclosed in the study (male/female: 16/16; DM1/DM2: 27/5; mean age 46.56 ± 12.74 years). 14/32 patients were in nocturnal non invasive ventilation.

Univariate analysis showed that PCF was significantly correlated with MIP ($r = 0.39$, $p = 0.0412$) but not with SNIP and MEP. This result was confirmed by the stepwise regression analysis using MIP, SNIP and MEP as explanatory variables of PCF.

Conclusions. To generate cough flow, inspiratory muscle strength is significantly more important for MD patients, than expiratory muscle function. In detail, MIP seems to be more accurate than SNIP in explaining PCF. MIP is a global measure of inspiratory muscle strength, while SNIP discriminates a specific diaphragm weakness and preloading cough volume consists in a maximal inspiration requiring the activation of all the inspiratory muscles.

Neuromuscular complications following target therapy in cancer patients

Demichelis C.¹, Lapucci C.¹, Grisanti S.¹, Genova C.^{2,3}, Grossi F.², Tanda E.⁴, Queirolo P.⁴, Benedetti L.¹, Schenone A.¹, Grandis M.¹

¹ Department of Neuroscience, Rehabilitation, Ophthalmology, Genetics, Maternal and Child Health (DINOEMI), University of Genova and Policlinico San Martino, Genova, Italy; ² Lung Cancer Unit, Policlinico San Martino, Genova, Italy; ³ Department of Internal Medicine, School of Medicine, University of Genova, Genova, Italy; ⁴ Oncologia Medica 2, Policlinico San Martino, Genova, Italy

In the last years, many new drugs have been developed targeting different oncology pathways, overall improving both quality of life and survival in several malignancies. However, the increasingly widespread use of these therapies is associated to novel toxicities, mainly dysimmune-related adverse events (irAEs), never observed before. While different irAEs are well characterized, neuromuscular complications are largely unknown and probably underestimated.

Herein we describe three oncological patients who developed different neuromuscular diseases after target therapy administration, in the last few months.

The first patient is a 73 years-old woman with lung adenocarcinoma treated with Nivolumab and Ipilimumab, both monoclonal antibodies targeting the immune checkpoint molecules PD1 and CTLA-4 respectively. After six infusions, she devel-

oped myasthenia gravis with predominant ocular manifestations and high-titre positivity of AChR-Antibodies.

The second patient is a 73 years-old man affected by mesothelioma, also treated with Nivolumab and Ipilimumab association. Two weeks after the first infusion he developed dysphagia, dysphonia and progressive respiratory failure that required non-invasive ventilation. The neurophysiological study was suggestive of Lambert-Eaton Syndrome.

The third patient is a 51 years-old woman treated with Vemurafenib and Cobimetinib, respectively BRAF and MEK inhibitors, for a cutaneous melanoma. One year after the beginning of the combined treatment, she developed an acute axonal motor neuropathy with predominant cranial nerve involvement.

In conclusion, we strengthen the relevance of neuromuscular complications in patients treated with new target therapies, because they can become life-threatening, if not recognized and managed appropriately.

Airways microbial colonization in neuromuscular patients.

The Istituto Gaslini experience

Diana M.¹, Pedemonte M.¹, Fiorillo C.¹, Bruno C.², Minetti C.¹, Bandettini R.³

¹ Pediatric Neurology and Muscle Disease Unit; ² Center of Translational and Experimental Myology; ³ Clinical Pathology Laboratory Unit Istituto Giannina Gaslini, Genova

Background. Severe lung volume restrictions and cough insufficiencies are the consequences of neuromuscular disorders (NMD) and are the causes of an impaired clearance of airway secretions. The introduction of the use of non-invasive ventilation (NIV) and mechanically assisted cough techniques can also be the potential cause of airway colonization.

The aim of this study was to evaluate the airways microbial colonization in patients with NMD admitted to our Institute, between 2015 and 2017.

Methods. We carried out a retrospective study on 61 patients (42,6% female and 57,4% male) aged between 4 months and 36 years old, affected by different NMD (75,4% used NIV) admitted to our Center in a two-years period. More samples per patients of sputum or bronchoalveolar lavage (BAL) were collected and cultured according to international guidelines.

Results. A total of 118 samples was analyzed and 80 (67.8%) were positives. The most frequent pathogen identified was *Pseudomonas aeruginosa* (48.8%) followed by *Candida* spp. (13.8%), *Staphylococcus aureus* (8.8%) and *Enterobacteriaceae* (*Escherichia coli*, *Klebsiella* spp., *Enterobacter* spp. *Serratia* spp. etc) (18.7%). For what concern the antimicrobial susceptibility all *S. aureus* strains were oxacillin susceptible and among *Enterobacteriaceae* only one strain (*Klebsiella* spp.) was carbapenemases producer (KPC).

Discussion. The impaired clearance of airway secretions as the consequence of the lung volume restriction and cough insufficiency in NMD patients predisposes to airway microbial colonization. Bacterial monitoring associated to the evaluation of lung function are important for the outcome, particularly, in patients using NIV.

Acute rhabdomyolysis:

a NGS panel for metabolic myopathies

Donati M.A.¹, Tubili F.¹, Pochiero F.¹, Ferri L.², Sacchini M.¹, Procopio E.¹, Scaturro G.¹, Daniotti M.¹, Pini A.³, Morrone A.², Pasquini E.¹

¹ Metabolic and Muscular Unit, Meyer Children's Hospital, Italy;

² Molecular and Cell Biology Laboratory, Paediatric Neurology Unit and Laboratories, Meyer Children's Hospital, Italy; ³ Child Neurology and Psychiatry Unit, IRCCS Istituto delle Scienze Neurologiche di Bologna, Bologna, Italy

Rhabdomyolysis is a pathological condition resulting from skeletal muscle injury with myoglobinuria (> 1000 µg/mL) and hyperCKemia (> 1000 IU/L).

Rhabdomyolysis in children can result from a variety of acquired and inherited causes and viral infection is the main suspected one. However, rhabdomyolysis can be the first presentation of an underlying inborn errors of metabolism (IEM) that can be triggered by exercise, fever or viral infection.

It is mandatory to consider an IEM in cases of recurrent rhabdomyolysis or rhabdomyolysis with positive family history. The diagnosis of IEM underlying rhabdomyolysis is important, most of them are life threatening but some are treatable conditions that can benefit from an early diagnosis; genetic counselling is important too.

The diagnosis can be difficult: CK levels are often normal between attacks and metabolic samples are not often collected during the acute phase or not evocative of a specific defect.

We studied 6 paediatric patients who were referred to us for recurrent rhabdomyolysis. Since the investigations did not allow the specific diagnosis and their clinical history was suggestive of IEM, a next generation sequencing (NGS) based approach was chosen to sequence a panel of 29 genes causative of rhabdomyolysis. It led to identify 3 fatty-acid beta-oxidation defects (2 LCHAD deficiency, 1 CPT2 deficiency), 1 TANGO2 gene mutation, 1 glycogen storage disorder (McArdle syndrome) and 1 Lipin-1 deficiency.

The aim of the study is to underline the importance of molecular analysis by NGS panel that allows to identify the genetic base of recurrent rhabdomyolysis.

Novel mutation in PMPCA in a boy with Leigh-like brain imaging

Dosi C., Nesti C., Rubegni A., D'Amore F., Morani F., Pasquariello R., Astrea G., Battini R., Santorelli F.M. IRCCS Stella Maris, Pisa

PMPCA encodes α -MPP, the α -subunit of mitochondrial processing peptidase, involved in the processing of mitochondrial proteins. Autosomal recessive mutations in PMPCA have been associated with non-progressive cerebellar ataxia or multisystem involvement including global developmental delay, severe hypotonia, respiratory insufficiency, blindness, and lactic acidemia.

We present a 7-year-old boy born to consanguineous parents who was first examined at age 24 months because of a global delay in psychomotor development in the suspect of a spastic ataxia disorder.

At the age of 7 years, the boy presents pyramidal and extrapyramidal manifestations with intellectual disability and expressive language disorder. Brain MRI scan showed atrophy of the cerebellar vermis and hemispheres and symmetrical bilateral hyperintensities in the striatum resembling the features seen in Leigh-like syndrome (LS).

Muscle biopsy showed the presence of subsarcolemmal rims,

mostly in cytochrome c oxidase. Biochemical analyses revealed multiple partial respiratory chain enzyme complex activities and a compensatory mitochondrial proliferation. Using a multigene panel in next generation sequencing we identified a homozygous mutation in PMPCA. The novel variant was predictably damaging when examined in silico and segregated in healthy parents. Both immunofluorescence and Western blot analyses did not show alterations in the proteins related to mitochondrial dynamics.

The presence of LS brain features at MRI associated with a complex neurological phenotype expand the genotype-phenotype correlations in PMPCA associated disorders.

Pharmacological studies of Nav1.4 channel mutants to define precision medicine in sodium channel myotonia and paramyotonia congenita

Farinato A.¹, Altamura C.¹, Imbriani P.¹, Maggi L.², Bernasconi P.², Mantegazza R.², Filosto M.³, Siciliano G.⁴, Sansone V.A.⁵, Lo Monaco M.⁶, the Italian Network for Muscle Channelopathies, Vial C.⁷, Sternberg D.⁸, Carratù M.R.⁹, Conte Camerino D.¹, Desaphy J.-F.⁹

¹ Dept of Pharmacy & Drug Sciences, University of Bari Aldo Moro, Italy; ² IRCCS Carlo Besta Neurological Institute, Milan, Italy; ³ Center for Neuromuscular Diseases and Neuropathies, Unit of Neurology ASST "Spedali Civili" and University of Brescia, Brescia, Italy; ⁴ Department of Clinical and Experimental Medicine, Section of Neurology, University of Pisa, Pisa, Italy; ⁵ Clinical Center NEMO, Neuorehabilitation Unit, Milan, Italy; ⁶ Neurological Institute, Catholic University of Sacred Heart, Rome, Italy; ⁷ Neuromuscular Reference Center, Hospices Civils de Lyon, Bron, France; ⁸ National Reference Center for Muscle Channelopathies, Groupe Hospitalier Pitié Salpêtrière, Paris, France; ⁹ Dept. of Biomedical Sciences and Human Oncology, University of Bari Aldo Moro, Bari, Italy

Gain of function mutations of the Nav1.4 sodium channel are responsible for sodium channel myotonia and paramyotonia congenita. The therapeutic efficacy of the sodium channel blocker, mexiletine, was demonstrated in a randomized clinical trial (Statland et al., 2013). Yet about one third of the patients obtain little benefit from mexiletine, due to limited response, side effects, or contraindications. Hypothesizing that myotonic mutations may affect binding of mexiletine to Nav1.4, we have shown that the G1306E mutant causing the severe myotonia permanens was less sensitive to mexiletine compared to wild-type channels, while sensitivity to the other Nav blocker, flecainide, was preserved (Desaphy et al., 2001; 2004). These results eventually led patients carrying G1306E to shift therapy from mexiletine to flecainide with great benefits (Desaphy et al., 2013). In 2015, the Italian Network of Muscle Channelopathies collected clinical data of 89 myotonic patients from 55 kindred carrying 28 known or novel Nav1.4 mutations. We performed functional and pharmacological studies of seven myotonic mutations located nearby G1306E (Maggi et al., 2017). Six mutations impaired mexiletine inhibition but maintained flecainide sensitivity. The reduced mexiletine sensitivity was likely related to the rightward shift of the voltage dependence of mutant channel inactivation. Nowadays, patients carrying three of these mutations gained great benefits from flecainide (Portaro et al., 2016; Desaphy et al., 2016; Terracciano et al., 2018). These results pave the way for a pharmacogenetics strategy to address myotonia therapy and emphasize the need of clinical trials to confirm flecainide usefulness in myotonia. Supported by Telethon-Italy (GGP14096).

Congenital fiber type disproportion related to novel autosomal dominant mutation in TNNT1

Fattori F.¹, D'Amico A.¹, Verardo M.¹, Bellacchio E.², Brizzi T.³, Fiumara A.⁴, Bertini E.¹, Rodolico C.⁵

¹ Unit of Neuromuscular and Neurodegenerative Disorders, Dep of Neurosciences, Bambino Gesù Children's Hospital, Rome; ² Genetics and Rare Diseases Research Area, Bambino Gesù Children's Hospital, Rome; ³ DIBIMIS, University of Palermo; ⁴ Section of Pediatrics and Child Neuropsychiatry, Department of Clinical and Experimental Medicine, University of Catania, Catania; ⁵ Department of Clinical and Experimental Medicine, University of Messina, Messina

Troponin T (TnT) is the tropomyosin binding subunit of troponin complex playing a central role in striated muscle contraction. Biallelic mutations in slow skeletal muscle TnT, encoded by TNNT1, have been reported to cause a rare form of nemaline myopathy (NM). The first TNNT1-NM has been associated to a single founder mutation in patients of Amish origin (ANM). Other three NM families have been reported later with different recessive loss-of-function mutations in TNNT1. Clinical phenotype in TNNT1-NM families is characterized by hypotonia, facial weakness, tremors (only in ANM), respiratory insufficiency and proximal weakness of varying severity. Recently, a heterozygous missense mutation in exon 9 of TNNT1 has been reported in a large family with autosomal dominant inheritance of NM, considerable intrafamilial clinical heterogeneity and fiber type disproportion.

We report an Italian 4 years old patient with severe neonatal hypotonia associated to orthopedic complications and delayed motor milestones. The girl, who is the only child of non-consanguineous parents, developed recently an infectious episode that evolved towards severe respiratory failure needing respiratory support. Muscle biopsy showed congenital fiber size disproportion with a marked type I muscle atrophy and some undifferentiated type 2C fibers revealed by ATPase staining. Nemaline bodies were not observed.

Next generation sequencing in this patient revealed a novel de novo heterozygous c.194A>C; p.(Asp65Ala) mutation in exon 8 of TNNT1 affecting an high conserved residue in the Tropomyosin-Binding Site 1 of TnT.

We describe the second TNNT1-related myopathy acting via a dominant mechanism and the first case without nemaline bodies in muscle biopsy.

Atypical cardiac involvement in congenital myotonic muscular dystrophy: a case report

Ferrantini G.¹, Berti B.¹, De Rosa G.², De Sanctis R.¹, Forcina N.¹, Carnicella S.¹, Mercuri E.^{1,3}, Pane M.^{1,3}

¹ Centro Clinico Nemo, Fondazione Policlinico A. Gemelli, Rome, Italy - Paediatric Neurology Unit, Catholic University of Sacred Heart, Fondazione Policlinico A. Gemelli, Rome, Italy; ² Paediatric Unit, Catholic University of Sacred Heart, Fondazione Policlinico A. Gemelli, Rome, Italy; ³ Paediatric Neurology Unit, Catholic University of Sacred Heart, Fondazione Policlinico A. Gemelli, Rome, Italy

Abstract. Congenital myotonic dystrophy (CMD) is a slowly progressive multisystemic disorder that presents in an wide spectrum of clinical finding and a marked intrafamilial-interfamilial clinical variability caused by a (CTG)_n expansion in DMPK gene. The CMD is the most severe form of myotonic dystrophy type 1 and is characterized by marked hypotonia, respiratory failure, facial diplegia and mental retardation. Cardiac involvement is a common feature of CMD presenting as conduction abnormalities

including atrioventricular block and sudden cardiac death. Cardiac MRI study showed also structural alterations mostly Left-Ventricular systolic dysfunction and dilatation while Right-Ventricular involvement is uncommon. These defects are usually asymptomatic during childhood and may worsen with time.

We report a 7 month-old boy with congenital onset, characterized by marked hypotonia, respiratory failure, arthrogryposis, facial dysmorphisms (retrognathia, ptosis, low set ears) and severe Right-Ventricular dilatation and dysfunction associated with pulmonary hypertension. On observation, when admitted, we also noticed developmental delay, facial diplegia. On cardiac follow-up we observed severe concentric-biventricular-hypertrophic cardiomyopathy with outflow obstruction of both ventricles (right > left). Due to respiratory failure and swallowing problems he underwent tracheostomy and gastrostomy.

Genetic study of DMPK gene disclosed more than 350 copies of CTG trinucleotide repeat according to the CMD. The mother showed 350 CTG copies with a clinical picture characterized by mild mental retardation and facial diplegia; asymptomatic grandmother showed 95 CTG repeat compatible with CMD carrier status.

This report confirms the intrafamilial variability of CMD and expands the cardiac phenotype of the pediatric form including Right-Ventricular involvement at the onset of the disease.

Structured light plethysmography and spinal muscular atrophy type 1

Ferretti M., Trucco F., Tacchetti P., Avanti C., Bobeica E., Bruno C., Pedemonte M., Minetti C.

U.O.C. Neurologia Pediatrica e Malattie Neuromuscolari e U.O.S.D. Centro Traslazionale di Miologia e Patologie Neurodegenerative, Ist. G. Gaslini, Genova

The respiratory pattern in spinal muscular atrophy type 1 (SMA1) is characterized by reduction in thorax volume and abdomen expansion during inhalation (paradoxical breathing), due to severe atrophy of thorax muscles associated to the partial spare of diaphragm.

Structured Light Plethysmography (SLP) is an innovative method that captures and records real-time functional images of chest and abdominal movement, using a digital vision system of 2 cameras. Recordings are analysed and displayed in terms of regional movement parameters and 3D-reconstruction.

With the aim of evaluating the kinematics of the thoracoabdominal wall and assessing the contribution in ventilation of the single muscle groups, 15 SMA1 patients (5 girls and 10 boys, median age 2,3 years, 1,4-7,9) underwent to SLP for 1 minute during spontaneous breathing.

SLP recordings analysis revealed increased Respiratory Rate in 80% of patients, high Rapid-Shallow Breathing Index in all children, prevalent diaphragmatic component compared to thorax contribution (median Relative Expired Abdomen 77% vs median Relative Expired Chest 23% and negative Principal Angle, median - 37°) and thoracoabdominal asynchrony (positive Phase Angle between 0° e 180°, median 48,70°).

These data indicate that a rapid shallow breathing with asynchronous diaphragmatic component is the strategy adopted by SMA1 patients to compensate for thorax muscle atrophy.

SLP allowed us to define a specific respiratory pattern in this subset of patients, it is non-invasive, gives direct information and not requires patients collaboration. Therefore it can be considered a promising and well tolerated tool for better understanding of the respiratory function in SMA1.

EURO-NMD and collaborative platform: a telemedicine tool to break down barriers in neuromuscular diseases

Fortunato F.¹, Mauro A.¹, Neri M.¹, Gualandi F.¹, Evangelista T.², Ferlini A.¹

¹ Unit of Medical Genetics, S.Anna University Hospital, Ferrara, Italy; ² Newcastle University, John Walton Muscular Dystrophy Research Centre, Newcastle upon Tyne, UK

European Reference Networks (ERN) are virtual networks involving healthcare providers across Europe aiming to create a clear governance structure for knowledge sharing and care coordination. In early 2017, the European Commission approved the first 24 ERNs. These were organized around 24 disease groups as proposed by the "EUCERD recommendations on rare diseases ERNs". The ERN on rare neuromuscular disorders (ERN EURO-NMD) was amongst these first 24 ERNs. EURO-NMD includes a broad group of rare neuromuscular disorders (NMDs), collects expertise across Europe to develop new guidelines and to provide patients with specialist care through in-person and virtual consultations.

At the heart of ERNs collaboration there are some online communication tools; one of this, the ERN Collaborative Platform (ECP) – developed not for sharing patients' data – supports networks activities facilitating communications between members, document management and event organization.

The ECP is a restricted space online to share, publish (Library), discuss (Forum), schedule (Agenda), vote (Poll), endorse (Like). The platform is ready to use and each of 24 ERNs has a dedicated area in which to organize their work.

We present our experience with this IT tool and some interesting cases we have collaboratively studied. This IT platform provides the backbone for the networks' collaborative work maximizing data sharing and integration. HCPs across the different ERNs should familiarize themselves with this and other IT tools available to the ERNs.

Cardiac troponin T fetal isoform expression as a possible biomarker of dysfunctions in DM1 skeletal muscle

Fossati B.¹, Bosè F.², Renna L.V.², Ferrari N.², Labate V.³, Cavalli M.⁴, Meola G.^{1,2,4}, Cardani R.²

¹ Department of Neurology, IRCCS Policlinico San Donato, Milan, Italy; ² Laboratory of Muscle Histopathology and Molecular Biology, IRCCS Policlinico San Donato, Milan, Italy; ³ Department of Cardiology Heart Failure Unit, IRCCS Policlinico San Donato, Milan, Italy; ⁴ Department of Biomedical Sciences for Health, University of Milan, Milan, Italy

Myotonic dystrophy type 1 (DM1) is an autosomal dominant neuromuscular disorder caused by expanded CTG repeats in the DMPK gene. Nuclear accumulation of the mutant RNA leads to aberrant alternative splicing of different genes. Alteration of cardiac troponin T (cTnT) alternative splicing leads to the co-expression of both adult (excluding-exon 5) and fetal (including-exon 5) isoform in cardiac tissue that is considered one cause of cardiac dysfunctions in DM1. cTnT aberrant splicing has been observed also in skeletal muscle of DM1 patients. The aim of this work is to study cTnT alternative splicing in biceps brachii (BB) and tibialis anterior (TA) muscle biopsies from DM1 patients to investigate if it is related to cardiac dys-

functions. RT-PCR analysis was performed on RNA from BB (n = 12) and TA samples (n = 11) of DM1 patients and healthy subjects (CTR: BB n = 6 BB, TA n = 4) using primers flanking exon 5. Cardiac function assessment by ECG, Holter-ECG, and echocardiogram was performed on DM1 patients. Both in BB and TA samples, a significantly higher cTnT fetal isoform expression was observed in DM1 patients presenting cardiac involvement than in CTR. In TA samples, cTnT fetal expression correlates with 2 out of 4 parameters of cardiac involvement taken into account in the study (QTc and %FE). No correlation was found between cTnT fetal expression and parameters of skeletal muscle impairment (both in BB and TA samples). In conclusion, fetal isoform expression in TA skeletal muscle of DM1 patients could represent a possible biomarker of heart dysfunction in these patients.

SPP1 and LTBP4 genotypes modify upper limb function in Duchenne muscular dystrophy

Fusto A.¹, Bello L.¹, D'Amico A.², Scutifero M.³, Vita G.L.⁴, Messina S.⁴, Pane M.⁵, D'Angelo G.⁶, Pini A.⁷, Mercuri E.⁵, Politano L.³, Bertini E.², Pegoraro E.¹

¹ Department of Neurosciences DNS, University of Padova, Padova, Italy; ² Unit of Neuromuscular and Neurodegenerative Disorders, Bambino Gesù Children's Hospital, Rome, Italy; ³ Cardiomyology and Medical Genetics, Department of Experimental Medicine, Second University of Naples, Naples, Italy; ⁴ Department of Neurosciences and Nemo Sud Clinical Center, University of Messina, Messina, Italy; ⁵ Child Neurology and Psychiatry Unit, Catholic University of the Sacred Heart, and Nemo Center, Fondazione Policlinico Gemelli, Rome, Italy; ⁶ IRCCS Eugenio Medea, Bosisio Parini, Italy; ⁷ Child Neurology and Psychiatry Unit, IRCCS Institute of Neurological Sciences, Bellaria Hospital, Bologna, Italy

Background. Several genetic modifiers, i.e. variants in genes different from the disease gene that modulate the phenotype, have been described in Duchenne muscular dystrophy (DMD). The effect of genetic modifiers has been demonstrated almost exclusively in ambulation-related phenotypes, while less is known about their effect on upper limb strength and function.

Methods. We genotyped a cohort of 73 patients from the Italian DMD network, evaluated with the disease-specific Performance Upper Limb (PUL) scale, at four known modifier loci: SPP1 encoding osteopontin (rs28357094), LTBP4 encoding Latent Transforming growth factor beta Binding Protein 4 (rs10880 and VTTT/IAAM haplotype), CD40 (rs1883832), and ACTN3 encoding actinin-3 (rs1815739), using TaqMan assays. We evaluated genotype effects with the published inheritance models, first cross-sectionally using baseline PUL data (analysis of covariance, ANCOVA), and then longitudinally after 2 years (repeated measures ANCOVA). Age and glucocorticoid treatment were included as covariates. Statistical significance was set at $p < 0.05$.

Results. We identified statistically significant effects of SPP1 rs28357094 genotype (dominant model TT vs TG/GG) on baseline PUL score (median 68 vs 66, $p = 0.019$) and longitudinal PUL change (median -2.0 vs -2.5, $p = 0.016$), and of LTBP4 rs10880 genotype (recessive model CC/CT vs TT) on baseline PUL score (median 66 vs 72, $p = 0.003$) and longitudinal PUL change (median -2.0 vs -2.0, $p = 0.016$).

Conclusions. SPP1 and LTBP4 variants confirm their modifier effect with upper limb phenotypes. This finding increases their clinical relevance in DMD, and warrants their use for cohort stratification in clinical trials including non-ambulatory participants.

DMD child born from egg donation procedure: could it be avoided?

Galimberti V.¹, Tironi R.¹, Ripolone M.¹, Scali M.¹,

Peverelli L.¹, Lerario A.¹, Comi G.P.², Moggio M.¹, Sciacco M.¹

¹ Neuromuscular and Rare Diseases Unit, Department of Neuroscience Fondazione IRCCS Ca' Granda Ospedale Maggiore Policlinico, Milan, Italy; ² Dino Ferrari Center, Neuroscience Section, Department of Pathophysiology and Transplantation, University of Milan, Neurology Unit, IRCCS Foundation Ca' Granda Ospedale Maggiore Policlinico, Milan, Italy

In the era of Assisted Reproductive Technology (ART) we report here a case of a 2 years old child born from egg donation and affected by Duchenne Muscular Dystrophy (DMD). In 2013 the European Society of Human Reproduction and Embryology showed that 39,000 egg donation treatments were performed in Europe from a total of almost 500,000 in vitro fertilization cycles. Despite the increasing use of ART, there is no common European Union legislation in assisted reproduction, and the accuracy of donor genetic carrier screening only depends on the policy of the institution in which the procedure is performed.

The boy presents proximal muscle weakness, calf hypertrophy, positive Gower's sign and unsteady gait associated with psychological retardation manifested with language delay and lack of social interaction (normal audiometry). PCR amplification and sequence analysis identified a splice-site mutation (c.8390 + 1G > A) in exon 56 of the dystrophin gene. Though mental retardation is known to be sometimes part of the DMD clinical picture, the case is peculiar because the mother refers a regular psychological development of the child, with early acquisition of language and social interaction, followed by a gradual regression.

We immediately contacted the European Center where the egg donation was performed to require a thorough genetic investigation of the donor and to ask for a temporary interruption of her donations. The procedure is currently still underway.

This report encourages the achievement of a clear and precise European regulation to minimize the risk of transmitting genetic diseases.

CT-guided lumbar puncture for intrathecal Nusinersen administration in SMA1 patients with challenging access.

The Istituto Gaslini experience

Gandolfo C.¹, Ferretti M.², Brigati G.², Incontrera A.², Bombardieri L.², Bobeica E.², Montobbio G.³, Minetti C.³, Pedemonte M.⁴, Bruno C.²

¹ Team Interventistico Endovascolare; ² Centro di Miologia Traslazionale e Sperimentale; ³ Centro di Anestesiologia e Terapia del Dolore Acuto e Procedurale; ⁴ Neurologia Pediatrica, Istituto Giannina Gaslini, Genova

Nusinersen, the first approved drug to treat SMA, requires serial intrathecal administration throughout a lumbar puncture (LP).

During the National Expanded Access Program (EAP) 23 SMA1 patients were treated at Istituto Gaslini in Genova. However, in few cases, due to kyphoscoliosis with severe vertebral rotation and/or spinal instrumentation, the standard approach for intrathecal access was difficult or impossible to perform.

We report our experience in term of success rate, radiation dose and complications of the intrathecal delivery of Nusinersen using CT-guided LP in 3 SMA1 patients (2 female and 1 male, age 9, 10, 12 years respectively), for a total of 17 injections.

All the CT-procedures were performed by an interventional

radiologist after the failure of the standard puncture. A local anesthesia was used. Vital parameters were monitored by an anesthesiologist and cardiopulmonary complications never occurred.

A 22G spinal needle was inserted according to classical manoeuvre (between L3-L4 and L5-S1 vertebrae). All injections were technically successful. The procedure time average ranged from 10 to 50 minutes with a mean number of attempts ranging between 1 and 6.

The DLP (a measure of the total amount of radiation used for CT scan) were between 27 and 170 mGycm (< 230 mGycm Italian diagnostic reference for CT abdomen). No procedure-related complications were reported.

In conclusion, this approach, despite operator dependent and not free from radiation, allowed to start therapy with Nusinersen in three cases that otherwise would not have benefited.

A novel mutation in the N-terminal acting binding domain of Filamin C causing a distal myofibrillar myopathy

Gemelli C.¹, Fiorillo C.², Fabbri S.¹, Trevisan L.¹, Bruno C.², Minetti C.², Maggi L.³, Gibertini S.³, Mandich P.¹, Schenone A.¹, Grandis M.¹

¹ Department of Neurosciences, Rehabilitation, Ophthalmology, Genetic and Maternal and Infantile Sciences (DINOEMI), Ospedale Policlinico San Martino, University of Genova, Italy; ² Department of Neuroscience, Center of Myology and Neurodegenerative Disorders, Istituto Giannina Gaslini, Genova, Italy; ³ Neuromuscular Diseases and Neuroimmunology Unit, Fondazione IRCCS Istituto Neurologico "Carlo Besta", Milano, Italy

Variants in Filamin C (FLNC) gene may cause either cardiomyopathies or different myopathies, including predominantly proximal forms with myofibrillar pathological features or distal myopathies.

We describe a large family with several cases affected by a distal myopathy segregating with autosomal dominant pattern.

In all patients the average onset was in the third decade, with gait impairment due to distal leg weakness initially causing a stepping gait, with later involvement of proximal lower limbs and hand muscles. The course of the disease was progressive with loss of walking ability occurring two decades after the onset. Muscle biopsy performed in one subject identified relevant myofibrillar abnormalities, including perturbation of myofibrillar alignment such as accumulation of granulofilamentous material and non-rimmed vacuoles. Lobulated or ring fibres were also found.

We performed a target gene panel testing for myofibrillar myopathies by NGS approach which identified a novel mutation in exon 3 of FLNC gene (c.A664G:p.M222V), within the N-terminal acting binding (ABD) domain. This variant was identified in all affected members of the family thus supporting its pathogenic role.

Most previously identified variants in this domain cause distal myopathies without myofibrillar features and with thenar and intrinsic hand muscle wasting as the first clinical symptom. Differently, our family showed a predominant leg involvement and myofibrillar aggregates, thus further expanding the spectrum of Filamin C related myopathies.

Long term follow-up and molecular studies in a LGMD1F sporadic TNPO3-mutated patient

Gibertini S.¹, Ruggieri A.¹, Saredi S.¹, Torella A.², Moggio M.³, Nigro V.², Morandi L.¹, Maggi L.¹, Mora M.¹

¹ Neuromuscular Diseases and Neuroimmunology Unit, Fondazione IRCCS Istituto Neurologico C. Besta, Milano, Italy; ² Università degli Studi della Campania "Luigi Vanvitelli" and Telethon Institute of Genetics and Medicine, Napoli, Italy; ³ Neuromuscular and Rare Diseases Unit, Department of Neuroscience, Fondazione IRCCS Ca' Granda, Ospedale Maggiore Policlinico, Milano, Italy

The causative mutation of LGMD1F was recently identified by whole genome sequencing in the gene coding for transportin 3. In addition to a large Italo-Spanish family affected by LGMD1F, only another single sporadic patient has been identified with a c.G2453A TNPO3 point mutation (p.R818Q). We report histopathological, immunochemical and molecular findings, and long term clinical follow-up in this patient.

Neurological evaluation after 18 years from disease onset showed progressive predominant scapular and pelvic muscle weakness, with moderate axial and mild distal muscle involvement. Cranial muscles were only slightly involved. Lower limb muscle MRI revealed severe and symmetrical fatty substitution of thigh muscles, with relative sparing of gracilis and rectus femoris, and lesser involvement of leg muscles. Cardiac function was normal.

By immunohistochemistry on patient muscle biopsy no autophagy activation was observed; by electron microscopy mostly mitochondrial alterations were detected; transfection of the mutant transportin 3 protein in COS7 cells showed normal nuclear localization. By Western blot the transportin 3 band was of normal size, but reduced amount, and TNPO3 transcript levels were more than 50%, decreased, probably because of messenger instability and consequent reduction of the protein. The affected residue R818 is in a helix region towards the C-terminus of the protein, the role of which is not precisely defined. In our patient the overall efficiency of transportin 3 is likely insufficient to mediate nuclear translocation of its ligands.

Merosin-deficient congenital muscular dystrophy type 1A: a case report with myopathologic and genetic findings

Francesco G.¹, Anna L.¹, Angela A.¹, Serlenga L.¹, De Cosmo L.², Laforgia N.², Resta N.³, Trojano M.¹

¹ Unit of Myopathology, Department of Basic Medical Sciences, Neurosciences and Sense Organs, University of Bari, Bari, Italy; ² Neonatology and Neonatal Intensive Care Unit, Department of Biomedical Science and Human Oncology, University of Bari, Bari, Italy; ³ Division of Medical Genetics, Department of Biomedical Sciences and Human Oncology, University of Bari, Bari, Italy

Merosin-deficient congenital muscular dystrophy 1A (MD-C1A) is an autosomal recessive disease resulting from mutations in the laminin α -2 (LAMA2) gene, localized to chromosome 6q22-23. The aim of this clinical case study was to characterize the clinical, pathologic and genetic features of an affected newborn male. Clinical presentation, as well as the results of neuroimaging, electrophysiology, myopathology and molecular genetic tests were used to evaluate the patient. At birth, the patient exhibited severe hypotonia and marked proximal weakness. The serum creatine kinase levels of the patient were exceptionally elevated at 43765 IU/L. Magnetic resonance imaging showed normal signal intensities on T1- and T2 weighted images on cerebral cortex and brain white matter. Brain ultrasound scans also appeared normal.

Needle electromyography suggested a myopathic process and muscle biopsy examination showed dystrophic muscle features, predominance of type 2A fibers and absence of merosin. Next generation sequencing of the LAMA2 exons revealed two different heterozygous nonsense mutations: c.C > A exchange in nucleotide 2901 (p.Cys967Ter) and another not yet published mutation consisting of c.G > T exchange in nucleotide 5050 (p.Glu1684Ter) that resulted both in a stop codon insertion during protein synthesis. Absence of merosin around muscle fibers due to compound heterozygosity for truncating mutations can justify clinical and myopathological severity of this case of MDC1A.

Expanded Access Program (EAP): another point of view

Gotti E.¹, Grandi C.¹, Lizio A.¹, Casiraghi J.¹, Carraro E.¹, Albamonte E.¹, Sansone V.A.^{1,2}

¹ NEuroMuscularOmniceNtre (NEMO), Fondazione Serena Onlus, Milan, Italy; ² Neurorehabilitation Unit, Dept. Biomedical Sciences for Health, University of Milan, Italy

Background. The NEMO Center (NeuroMuscular Omnicentre) is a multidisciplinary specialized tertiary clinic, for the care of kids and adults with neuromuscular diseases. Two Nurse Coaches have facilitated continuity of care between hub and spoke for adult patients with neuromuscular disorders. During the EAP with Nusinersen for SMA1 we dedicated a child therapist with Nurse Coaching experience to implement the same approach for the pediatric population to manage and support patient and family.

Objective. To describe the pathway of this new Nurse Coaching approach and the preliminary customer satisfaction results related to this.

Methods. Data from 26 Home Data Sheet on the socio-demographic characteristics of caregivers, quality of health services and nurse coaching activities were filled in and retrospectively analysed.

Results. The general satisfaction about the service was good and parents assessed positively the possibility to have a dedicated referee. They also appreciated the cooperation with their home care services.

Discussion. The approach described has ensured families to have a clear referral at the hub site at all times, even during drug-free intervals. Furthermore, it was possible to create a continuity relationship between the hospital and the home-care services aimed at guaranteeing the best practice of care in a complex disease like SMA.

Conclusions. We were able to implement a holistic, inclusive and relational approach in the usual care of these patients. Access to the specialist Center was no longer just the response to a therapeutic need but a moment of confrontation and growth.

Relapsing episodes of intestinal pseudo-obstruction led to a late diagnosis of MELAS

Govoni A., Gagliardi D.¹, Magri F.¹, Velardo D.¹, Piga D.¹, Ronchi D.¹, Brajkovic S.², Moggio M.², Cinnante C.³, Corti S.¹, Comi G.P.¹

¹ Dino Ferrari Centre, Neuroscience Section, Department of Pathophysiology and Transplantation, Neurology Unit, IRCCS Foundation Ca' Granda Ospedale Maggiore Policlinico, Milan, Italy; ² Neuromuscular and Rare Disease Unit, Department of Neuroscience, Foundation IRCCS Ca' Granda Ospedale Maggiore e Policlinico, Dino Ferrari Centre, Milan, Italy; ³ U.O. Neuroradiologia, I.R.C.C.S. Foundation Ca' Granda, Ospedale Maggiore Policlinico, Milan, Italy

Mitochondrial encephalomyopathy, lactic acidosis, and

stroke-like episodes syndrome (MELAS) is a maternally inherited multisystem disorder caused by mitochondrial (mt) DNA mutation. The age of onset is typically in childhood or youth before age 40. MELAS is mainly manifested by involvement of the central nervous system with stroke-like episodes and muscles with weakness and myopathy. There may be other associated symptoms that vary in severity according to the degree of mutation heteroplasmy. We present a case of a 50 year-old man who was investigated for a mitochondrial disorder, following relapsing severe intestinal pseudo-obstructions. At the age of 50 years, he went to the emergency room for visual disorders, headache, photophobia and asthenia. The brain CT scan revealed a right superior temporal lesion that was interpreted as recent ischaemic stroke. Nothing relevant was reported in medical history. In the following months, he developed two episodes of paralytic ileus for which he was admitted at our hospital. Mechanical causes of intestinal occlusion and amyloidosis were excluded. The neurological evaluation was requested and the brain MRI showed severe cortical atrophy and a lesion involving the parietal, occipital and temporal right lobes, suspected for metabolic injury. Muscle biopsy showed presence of ragged-red and cytochrome oxidase negative fibers. MtDNA analysis showed the A3243G point mutation; the degree of heteroplasmy was 55.3% in muscle, 23.4% in urinary epithelial and 13.1% in white blood cells. This case shows how a late presentation including relapsing intestinal pseudo-obstruction may lay within the spectrum of MELAS caused by the A3243G mutation.

Genotype-phenotype relationship in myotonia congenita caused by CLCN1 mutations: what we have done and future therapeutic challenges for precision medicine

Imbriani P.¹, Altamura C.¹, Sahbani D.¹, Camerino G.M.¹,

Conte E.¹, Pierno S.¹, Maggi L.², Lo Monaco M.³,

Meola G.⁴, Lucchiari S.⁵, Pagliarini S.⁵, Ulzi G.⁵,

Bernasconi P.², Brugnani R.², Comi G.⁵, Mantegazza R.²,

D'Amico A.⁶, Pegoraro E.⁷, Politano L.⁸, Mongini T.⁹,

Vercelli L.⁹, Siciliano G.¹⁰, Ricci G.¹⁰, Toscano A.¹¹,

Sansone V.¹², Desaphy J.F.¹³, Conte D.¹, on behalf of the Italian

Network for non Dystrophic Muscle Channelopathies

¹ Department of Pharmacy-Drug Sciences, University of Bari "Aldo Moro"; ² Neuromuscular Diseases and Neuroimmunology Unit,

Neurological C. Besta Institute, Milano; ³ Neurological Institute,

Catholic University of Sacred Heart, Polyclinic Gemelli, Rome;

⁴ Department of Biomedical Sciences for Health, University of

Milano, IRCCS Policlinico San Donato, Milano; ⁵ Dino Ferrari

Centre, Neuroscience Section, Department of Pathophysiology and

Transplantation (DEPT), University of Milano, Neurology Unit, IRCCS

Foundation Ca' Granda Ospedale Maggiore Policlinico, Milano; ⁶ Unit

of Neuromuscular and Neurodegenerative Disorders, IRCCS Bambin

Gesù Children's Hospital, Roma; ⁷ Department of Neurosciences,

University of Padova; ⁸ Cardiology and Medical Genetics,

Department of Experimental Medicine, University of Campania,

Napoli; ⁹ Neuromuscular Unit, Department of Neurosciences, Hospital

Città della Salute e della Scienza di Torino, University of Torino, Italy;

¹⁰ Department of Clinical and Experimental Medicine, Neurology Unit,

University of Pisa; ¹¹ Department of Neurosciences, University of

Messina; ¹² The NEMO Center, Neurorehabilitation Unit, University of

Milano; ¹³ Department of Biomedical Sciences and Human Oncology,

University of Bari "Aldo Moro"

Myotonia congenita is the most common skeletal muscle channelopathy, caused by loss-of-function mutations in the CLC-1 chloride channel. Therapy mainly relies on the sodium channel

blocker, mexiletine, because no selective CIC-1 activator is available. In collaboration with the neurologists of the Italian Network for Muscle Channelopathies, we characterized 23 novel CIC-1 missense mutations identified in families with mild-to-severe myotonia congenita. Patient information was collected including disease severity, genetic background, inheritance, response to therapy and age of onset to help define a genotype-phenotype correlation. Using patch-clamp technique, myotonic mutations were functionally classified as “gating-defective” or “expression-defective” (Portaro et al., 2015; Imbrici et al., 2015, 2016; Desaphy et al., 2013). The severity of the clinical phenotype well correlated with the degree of chloride current reduction induced by mutations. To develop a personalized mechanism-based therapy for myotonia congenita, we intend to identify gating-correctors and trafficking-correctors to specifically target the biophysical channel defect. Using an in silico approach, we already mapped four binding pockets in CIC-1 channels (Altamura et al., 2018). Such information would help to design selective drugs for CIC-1 channels. We also obtained proof of concept that small CIC-1 ligands, such as niflumic acid, can function as pharmacological chaperone. In conclusion, through the cooperative efforts of the Network we validated a working paradigm that allowed us to successfully address myotonia congenita from a clinical, genetic, functional and therapeutic level.

Language abilities and oral muscle strenght in DMD and BMD boys

Lenzi S.¹, Cravero A.¹, Moretti E.¹, Pecini C.¹, Frosini S.¹, Astrea G.¹, Cioni G.^{1,2}, Battini R.^{1,2}

¹ Department of Developmental Neuroscience, IRCCS Stella Maris, Calambrone (Pisa); ² Department of Clinical and Experimental Medicine, University of Pisa, Pisa, Italy

Background. Dystrophinopathies (Duchenne and Becker Muscular Dystrophy – DMD and BMD –) are not only disorders leading to muscle wasting, but also multi-systemic diseases, that need a multidisciplinary management. A possible and variable involvement of language abilities has been reported too, in particular for DMD.

Aim. The aim of the study was to examine language abilities and oral muscle strength in DMD and BMD boys in order to identify a preventive management of these aspects.

Materials and methods. 22 boys (11 DMD and 11 BMD) referring to the Neuromuscular Unit of IRCCS Stella Maris were selected. They were assessed by tests for general language abilities, narrative competence, pragmatic skills and by a clinical evaluation for main oral muscles strength.

Results. The overall scores for the DMD boys were lower than the BMD children.

We found a general deficit in language. Narrative competence and pragmatic skills were affected, probably due to the working memory impairment and to some environmental factors.

The masseter was the most efficient muscle, while the orbicular and the buccinator were the most impaired ones. The comparison between against gravity and against resistance movements has provided data about the mouth functioning and the facies quality of these boys.

Conclusions. We can speculate that these boys can have a speech delay that is often not treated but can produce results. The speech therapist intervention can predict and prevent these impairments, improving the quality of life of the children, both for the academic learning and, more generally, for the psychosocial adjustment.

Becker muscular dystrophy presenting with epilepsy and mild cognitive impairment: double trouble or CNS involvement related to dystrophin gene mutation?

Lerario A.¹, Peverelli L.¹, Tironi R.¹, Spazzini L.³, Mastrangelo M.³, Sciacco M.¹, Comi G.P.², Moggio M.¹

¹ Neuromuscular and Rare Disease Unit, Department of Neuroscience, Foundation IRCCS Ca' Granda Ospedale Maggiore Policlinico, University of Milan, Milan, Italy; ² Dino Ferrari Centre, Department of Pathophysiology and Transplantation Neuroscience Section (DEPT), Neurology Unit, Foundation IRCCS Ca' Granda Ospedale Maggiore Policlinico, University of Milan, Milan, Italy; ³ Neurologia Pediatrica Ospedale Buzzi

Becker muscular dystrophy (BMD) typically presents with gradually progressive muscle weakness. Although epilepsy is an infrequent manifestation, three main studies observed an increased prevalence of epilepsy in DMD/BMD children carrying a mutation between exon 44 and 63. However, no causal relation was found between a specific mutation and the occurrence of epilepsy.

We describe an 11 years old girl affected with a mild cognitive impairment and with a diagnosis of epilepsy dating back to the age of 20 months. Brain MRI showed bilateral hyperintensity in the subcortical frontal white matter, creatine kinase level was markedly elevated (2259 U/L) whereas electromyogram was mildly myopathic. In the hypothesis of a mitochondrial disorder she underwent skeletal muscle biopsy which only showed unspecific myopathic changes though, at immunohistochemistry, a reduced sarcolemmal binding was observed in some fibers with antibodies against dystrophin and against a and g sarcoglycans. Multiplex ligation-dependent probe amplification detected an in-frame deletion in exons 48–51 of the Dystrophin gene. The same mutation was found in the patient's father, who is asymptomatic though with calf hypertrophy and moderately elevated CK levels.

The present case report allows to better define the clinical and genetic features of BMD. Compelling evidence indicates that dystrophin plays a significant role within the CNS, because several clinical observations show neurocognitive symptoms and learning disabilities in patients with dystrophin gene mutations and DMD phenotype. We suggest that dystrophin deficiency may increase neuronal excitability by affecting the function of both neurotransmitter receptors and water-ion channels on cellular membrane.

Late onset multiple acyl-CoA dehydrogenase deficiency: it's never too late

Macchione F.¹, Bordugo A.², Vincenzi M.³, Camilot M.³, Teofoli F.³, Salviati L.⁴, Vattemi G.¹, Tonin P.¹

¹ Department of Neurosciences, Biomedicine and Movement Sciences, Section of Clinical Neurology, University of Verona; ² Inherited Metabolic Disease Unit; ³ UOC Pediatrics Verona; ⁴ Clinical Genetics Unit, Department of Women and Children's Health, University of Padova

Multiple acyl-CoA dehydrogenase deficiency (MADD) is an autosomal recessive disorder of fatty acid oxidation due to defects of an electron transfer flavoprotein (ETF) encoded by ETFA and ETFB or an electron transfer flavoprotein dehydrogenase (ETFDH) encoded by ETFDH. The metabolic defect causes impaired adenosine triphosphate (ATP) biosynthesis, excessive lipid accumulation and reduced gluconeogenesis. The

clinical presentation has been classified as a neonatal onset form with (type 1) and without (type 2) congenital abnormalities and a mild late-onset form (type 3). The infantile onset disease may be fatal and is characterized by hypotonia, metabolic acidosis, non-ketotic hypoglycemia and cardiomyopathy. The clinical spectrum of type 3 form, instead, is heterogeneous as for age at onset and presentation with patients as old as 56 years reported. We present two patients in their seventies who were referred for suspected inflammatory myopathy. The first, a 72-year-old woman, complained from three years of episodic muscle weakness and had received steroid therapy without benefit. The second patient, a 71-year-old man, manifested from two years progressive leg weakness, difficulty raising his arms above the shoulders and dropped head. CK was normal, EMG was myopathic. For both patients muscle biopsy showed lipid storage and blood acylcarnitine analysis was consistent with multiple acyl-CoA dehydrogenase deficiency. DNA analysis identified a heterozygous variation in ETFDH gene in the second patient. Further DNA analysis is ongoing. Both patients gradually improved after treatment with riboflavin and L-carnitine. Late-onset MADD is probably underdiagnosed but should be considered also in elderly patients to avoid unnecessary therapies.

Dysregulation of myomiRNA in Becker and facioscapulohumeral muscular dystrophy

Marozzo R., Pegoraro V., Angelini C.
San Camillo Hospital IRCCS, Venice, Italy

Becker muscular dystrophy (BMD) is an X-linked recessive inherited disorder, due to a mutation in dystrophin gene. Individuals with this disorder typically present progressive weakness and wasting of the skeletal and cardiac muscles. However, some BMD cases have no overt muscle weakness but only cramps and myalgia. Facioscapulohumeral muscular dystrophy (FSHD) is one of the most common forms of muscular dystrophy with a distinctive pattern of skeletal muscle weakness and a wide spectrum of disease severity.

MicroRNAs (miRNAs) are small non-coding RNA molecules approximately 22 nucleotides in length. A group of miRNAs are highly expressed in skeletal and cardiac muscle and they are called myomiRs. The myomiR family includes miR-1, miR-133a, miR-133b, miR-206 which are used as non-invasive biomarkers in neuromuscular diseases.

We analysed miRNA expression level by Real Time PCR in the serum of 6 BMD patients and 6 FSHD and 8 control subjects. FSHD is classified according to the CCEF evaluation form. The most highly dysregulated serum miRNA in BMD was miR-206, a skeletal muscle-specific miRNA. One patient affected by BMD, who presented a major clinical and MRI alterations with calf hypertrophy, showed a marked increase of miR-206 and miR-133b and a slight up-regulation of the other miRNA, compared to the control group. Two FSHD patients with elevated score at CCEF appeared to have increase 8/12 fold up-regulation of miR-206. These data highlight the potential use of miRNA as biomarkers of BMD and FSHD that seem to correlate with both clinical and MRI imaging changes.

SUNFISH part 1: RG7916 treatment results in a sustained increase in SMN protein levels

Mercuri E.¹, Baranello G.², Kirschner J.³, Servais L.⁴, Goemans N.⁵, Pera M.C.¹, Buchbjerg J.⁶, Armstrong G.⁷, Kletzl H.⁶, Gerber M.⁶, Czech C.⁶, Cleary Y.⁶, Gorni K.⁶, Khwaja O.⁶

¹ Paediatric Neurology and Nemo Center, Catholic University and Policlinico Gemelli, Rome, Italy; ² Carlo Besta Neurological Research Institute Foundation, Developmental Neurology Unit, Milan, Italy; ³ Department of Neuropediatrics and Muscle Disorders, Medical Center-University of Freiburg, Freiburg, Germany; ⁴ Institute of Myology, Paris, France; Reference Center for Neuromuscular Disease, Centre Hospitalier Régional de La Citadelle, Liège, Belgium; ⁵ Neuromuscular Reference Centre, Department of Paediatrics and Child Neurology, University Hospitals Leuven, Belgium; DVC St Jozef Antwerp, Antwerp, Belgium; ⁶ Roche Pharmaceutical Research and Early Development, Roche Innovation Center Basel, Switzerland; ⁷ Roche Products Ltd, Welwyn Garden City, United Kingdom

Spinal muscular atrophy (SMA) is characterized by motor neuron loss and muscle atrophy due to reduced levels of survival of motor neuron (SMN) protein. RG7916 is an orally administered, centrally and peripherally distributed small molecule that modulates SMN2 pre-mRNA splicing towards the production of full-length SMN2 mRNA and increases SMN protein levels.

SUNFISH is a multicenter, double-blind, placebo-controlled trial (randomized 2:1, RG7916: placebo) in patients with type 2 or 3 SMA aged 2-25 years. SUNFISH comprises two parts: Part 1 evaluated the safety, tolerability, and pharmacokinetics and pharmacodynamics (PK/PD) of several RG7916 dose levels (n = 51); the pivotal Part 2 (ongoing) will assess the safety and efficacy of the RG7916 dose level selected from part 1 (n = 168).

Recent analysis of data from patients with SMA in Part 1 showed that SMN protein levels in whole blood increased in a dose-dependent manner up to a median between 2-fold and 3-fold after 4 weeks of treatment. The safety, tolerability and PK/PD data from part 1 informed the selection of a RG7916 dose level for SUNFISH part 2 predicted to lead to clinically efficacious increases in SMN protein. To date, no drug-related adverse events leading to withdrawal have been observed.

We will provide a detailed SUNFISH update with novel biomarker, PK and full unblinded safety results from part 1.

In SUNFISH part 1, RG7916 treatment increased SMN protein dose dependently. The clinical benefit of the selected dose level is being assessed in SUNFISH part 2, which is currently recruiting globally.

Expression of type I and type II interferons is increased in muscle biopsies of juvenile dermatomyositis (JDM) patients and related to clinical and histological features

Moneta G.M.¹, Rosina S.², Fiorillo C.², Pires Marafo D.¹, Verardo M.³, Bracci Laudiero L.^{1,4}, Minetti C.^{2,5}, Ravelli A.^{2,6}, De Benedetti F.¹, Nicolai R.¹

¹ Division of Rheumatology, Ospedale Pediatrico Bambino Gesù IRCCS, Roma, Italy; ² University of Genova, Genova, Italy; ³ Unit of Neuromuscular and Neurodegenerative Disorders, Ospedale Pediatrico Bambino Gesù IRCCS, Roma, Italy; ⁴ Institute of Translational Pharmacology, CNR, Roma, Italy; ⁵ Pediatric Neurology and Muscular Disorders, Giannina Gaslini Institute, Genova, Italy; ⁶ Rheumatology, Giannina Gaslini Institute, Genova, Italy

Objectives. Our aim was to investigate expression of type I and type II IFN inducible genes in muscle biopsies of JDM patients.

Methods. In 35 JDM patients, expression of IFI27, IFI44L, IFIT1, ISG15, RSAD2, SIGLEC1 (genes part of the type I IFN score), IFN γ , CXCL9, CXCL10, CXCL11 and CIITA was analyzed by real-time PCR on muscle biopsies and compared with biopsies from 24 Duchenne muscular dystrophy (DMD) patients and 4 healthy controls. Expression of CXCL9, CIITA and IFN γ was used to generate a type II IFN score. We also analyzed mRNA expression of IL-1 β , TNF α and IL-6. Patient charts were reviewed to record clinical features at diagnosis and long term outcomes. We furthermore evaluated typical histological aspects of JDM on tissue sections.

Results. JDM patients treated (n = 12) with glucocorticoids before biopsy were excluded. The type I IFN and type II IFN score were significantly higher in untreated JDM patients (n = 23) compared with controls. Expression of TNF α was significantly higher in untreated JDM muscle biopsies compared with controls. Type I IFN and type II IFN score correlated with distinct histological features. Type I and type II IFN score and TNF α expression significantly correlated with physician's global assessment at diagnosis. Patients with elevated type II IFN score reached clinically inactive disease significantly later than patients with a low score.

Conclusions. Type I and type II IFN scores in muscle biopsies of JDM patients correlate with clinical and histological features, suggesting a pathogenic role of IFNs in muscle damage and inflammation in JDM.

Longitudinal evaluation of muscle involvement in FSHD by qualitative muscle MRI

Monforte M.¹, Tasca G.¹, Bagnato M.R.¹, Ottaviani P.², Laschena F.², Pichiecchio A.², Ricci E.¹

¹ Istituto di Neurologia, Università Cattolica del Sacro Cuore, Fondazione Policlinico Universitario "A. Gemelli", Rome, Italy;

² Dipartimento di Radiologia, IDI IRCCS Rome, Italy; ³ Department of Neuroradiology, National Neurological Institute C. Mondino, Pavia, Italy

Background. Cross sectional studies reported the most frequent muscle imaging patterns in Facioscapulohumeral muscular dystrophy (FSHD), whilst only limited longitudinal data are available. With many clinical trials at the horizon, the knowledge of the natural history of FSHD is of importance to understand the impact of new therapies. Given the peculiar involvement in FSHD, muscle MRI represents an invaluable tool to explore the modalities and rate of disease progression.

Aim. To assess yearly disease progression in FSHD patients using qualitative muscle MRI.

Methods. 100 genetically confirmed FSHD patients underwent a baseline and a 1-year follow-up lower limb muscle MRI. T1 weighted (T1w) and short-tau inversion recovery (STIR) sequences were used to assess the presence of fatty replacement (using a semiquantitative visual score) and of oedema (presence or absence). The scans were also evaluated by unblinded direct comparison to detect the changes not identified by the previous scoring system, classifying differences into 16 categories.

Results. We report 1) the percentage of muscles that changed their score of fat infiltration; 2) the percentage of muscles that, although not showing a change in their score, demonstrated clear signs of progression in the direct unblinded comparison; 3) the rate of appearance/disappearance of STIR+ lesions; 4) the relation existing between STIR + lesions and progression of fat changes in each muscle.

Conclusions. Data derived from this longitudinal MRI study contribute to delineate the natural history of FSHD, and provide useful evidence for future clinical trials in this disease.

New Italian case of authofagic vacuolar myopathy associated with a mutation in CLN3

Moro E.¹, Rubegni A.¹, Baldacci J.¹, Pochiero F.², Procopio E.², Donati M.A.², Santorelli F.M.¹

¹ Molecular Medicine, IRCCS Fondazione Stella Maris, Pisa;

² Metabolic and Muscular Unit, Neuroscience Department, Meyer Children's Hospital, Florence

Autophagic vacuolar myopathies (AVMs) are a heterogeneous group of disorders characterized by intracytoplasmic autophagic vacuoles with sarcolemmal features and acetylcholinesterase activities in the muscle biopsy. Recently a few patients with complex multiorgan involvement and widespread alteration on muscle biopsy suggestive of AVM have been described in association with mutations in the CLN3 gene.

We report a 29-year-old man with infancy progressive visual loss with retinitis pigmentosa and cataract followed by tonic-clonic seizures and progressive neuromotor deterioration. Last neurological examination showed festinated gait with bradykinesia, muscular rigidity, rest tremor and pyramidal signs. Brain MRI demonstrated diffuse cortical-subcortical atrophy. Echocardiogram revealed left ventricular hypertrophy. A mitochondrial encephalomyopathy was suspected and a muscle biopsy proposed.

Histological studies in skeletal muscle showed variation in fiber size and both atrophic and hypotrophic fibers with increased central nuclei. A number of fibers with degenerative aspects and various fibers with autophagic vacuoles were observed. Autophagic vacuoles showed a strong reaction for lysosomal acid phosphatase activity. Immunofluorescence analysis revealed a positive binding at vacuolar membrane level, using dystrophin antibodies. Molecular analyses showed the common 1.02 kb homozygous deletion in the CLN3 gene.

CLN3 disease (Batten disease), the classic juvenile form of neuronal ceroid lipofuscinosis, is an autosomal recessive condition characterized by visual impairment, psychomotor deterioration, and seizures. Skeletal muscle involvement has been rarely described in Batten disease.

Our report confirm the importance of considering a CLN3 disease in the diagnostic workup of individuals with AVM, particularly if there is visual impairment and cardiac muscle is involved.

Robot-aided assessment of peripheral muscular fatigue in children with neuromuscular disorders

Mugnosso M.¹, Marini F.¹, Doglio L.², Panicucci C.³, Bruno C.³, Moretti P.², Morasso P.¹, Zenzeri J.¹

¹ Department of Robotics, Brain and Cognitive Sciences, Istituto Italiano di Tecnologia, Genova, Italy; ² Physical Medicine and Rehabilitation, Institute G. Gaslini, Genova, Italy; ³ Neuromuscular Diseases Service, Institute G. Gaslini, Genova, Italy

Muscle fatigue is a highly debilitating symptom commonly present in neuromuscular disorders. Its assessment could provide crucial information to monitor the progression of the disease and, equally important given the increasing number of potentially effective therapies, the efficacy of the potential therapy. However, in clinical practice muscle fatigue is assessed by means of rating scales or questionnaires which provide qualitative information with consequently low resolution. On the other side, researchers have

used surface electromyography (sEMG) to quantitatively assess muscle fatigue. When muscle fatigue arises, muscle fibers conduction velocity and frequency of sEMG signals decrease. Accordingly, muscle fatigue can be detected by spectral parameters. However, the majority of the existing protocols are not sustainable by patients especially in case of low residual muscular function as the neuromuscular ones. Therefore, we proposed a test easy and fast to be performed coupling sEMG and a robotic protocol and we defined an indicator of the Onset of Fatigue (OF) which provides direct information about muscular fatigue. The aim of this work was to test the feasibility of the method. The test consisted in reaching flexion-extension movements of the wrist performed with a robotic device. sEMG signals of flexor and extensor carpi radialis muscles were recorded throughout the test. The test were administered to 15 children with DMD. All subjects successfully performed the test and their OF was calculated showing early fatigability as expected. This work proved the feasibility of the method on neuromuscular subjects and in particular on the pediatric ones.

2,127 genetic diagnoses of dystrophinopathies within the DMD Italian Network: report and reflections impacting on care and therapies

Neri M.¹, Mauro A.¹, Gualandi F.¹, Selvatici R.¹, Falzarano M.S.¹, Rossi R.¹, Trabaneli C.¹, Rimessi P.¹, Fabris M.¹, Fortunato F.¹, Fiorillo C.², Bruno C.², Santorelli F.M.³, Astrea G.³, Tessa A.³, Tedeschi S.⁴, Magri F.⁵, Del Bo R.⁵, Moggio M.⁵, D'Amico A.⁶, Travaglini L.⁶, Castori M.⁷, Piemontese M.R.⁷, Merla G.⁷, Cau M.⁸, Piras R.⁸, Melis M.A.⁹, Boccone L.¹⁰, Marica M.¹⁰, Pastorino M.¹¹, Festa S.¹¹, Scuderi C.¹², Borgione E.¹², Lo Giudice M.¹², Mela J.¹³, Giardina E.¹³, Vita G.L.¹⁴, Messina S.¹⁴, Pegoraro E.¹⁵, Bello L.¹⁵, Sansone V.A.¹⁶, Albamonte E.¹⁷, Politano L.¹⁸, Bertini E.⁶, Comi G.P.⁵, Nigro V.¹⁹, Mercuri E.²⁰, Ferlini A.¹

¹ Unit of Medical Genetics, S. Anna University Hospital, Ferrara; ² Paediatric Neurology and Muscular Diseases Unit, University of Genoa and G. Gaslini Institute, Genoa; ³ IRCCS Fondazione Stella Maris, Department of Molecular Medicine, Pisa; ⁴ Medical Genetic Unit, IRCCS Foundation Ca' Granda Ospedale Maggiore Policlinico; ⁵ Neuroscience Section, Department of Pathophysiology and Transplantation, Dino Ferrari Center, University of Milan, Milan, IRCCS Foundation Ca' Granda Ospedale Maggiore Policlinico; ⁶ Bambino Gesù Children's Hospital, Rome; ⁷ Division of Medical Genetics, IRCCS Casa Sollievo della Sofferenza, S. Giovanni Rotondo; ⁸ Dipartimento di Scienze Mediche e Sanità Pubblica, Università degli Studi di Cagliari; ⁹ Università degli Studi di Cagliari; ¹⁰ Ospedale Pediatrico Microcitico "A. Cao" AO Brotzu, Cagliari; ¹¹ U.O.C. di Neuropsichiatria Infantile AOU Sassari; ¹² Oasi Research Institute-IRCCS, Troina; ¹³ UILDM Sez. Lazio/ Fondazione Santa Lucia, Roma; ¹⁴ Department of clinical and experimental medicine, University of Messina and Nemo Sud Clinical Center, Messina; ¹⁵ Neuromuscular Center, Dipartimento di Neuroscienze, Università di Padova, Padova; ¹⁶ Neurorehabilitation Unit, Dept. Biomedical Sciences for Health, University of Milan, Centro Clinico NEMO Milano; ¹⁷ Neurorehabilitation Unit, Centro Clinico NEMO Milano; ¹⁸ Dipartimento di Medicina Sperimentale, Cardiomiologia e Genetica Medica, Università degli Studi della Campania "Luigi Vanvitelli," Napoli; ¹⁹ Dipartimento di Medicina e Precisione, Università degli Studi della Campania "Luigi Vanvitelli," Napoli; ²⁰ Centro Clinico Nemo, Policlinico A. Gemelli, and at the Paediatric Neurology Unit, Catholic University of Sacred Heart, Roma

Dystrophinopathies are allelic diseases caused by mutations in the dystrophin gene. Genetic diagnosis of dystrophin-

nopathies is complex but genotype profiling is currently mandatory both for appropriate care, including prevention, and for eligibility to clinical trials. The DMD Italian network is composed by 11 centers offering dystrophin genetic analysis. 2127 patients were referred and genotyped. Among these, DMD were 59% and BMD 41% revealing a very high number of BMD phenotypes referred for diagnosis.

Among DMDs, 58% carried deletions, 11% duplications and 30% small mutations. BMDs show 78% of deletions, 9% of duplications and 13% of small mutations. Notably, the percentage of small mutations in DMD is higher than those reported; similarly BMDs do show a very high number of deletions, and small mutations are more frequent than duplications. Among small mutations 45% (DMD) and 33% (BMD) are nonsense; 62,8% of out-of-frame deletions are eligible for single exon skipping (17,8% for exon 53 skipping, 17% for exon 51 skipping, 16,6% for exon 45 skipping, and 11,4% for exon 44 skipping).

Among all diagnosed DMDs/BMDs, 10,5% remained orphan of a causative mutation. In these case revising the clinical diagnosis (especially the muscle biopsy results) is necessary, although this might also imply that atypical mutations may occur in a remarkable number of DMD and third level of genetic diagnosis (CGH or RNA profile) are needed. Our large patient cohort fully analyzed for DMD mutations allows a many reflections about DMD/BMD genotypes, mutation detection and mutation types percentage with repercussion on care and new therapies designing.

Complex multisystem phenotype associated with the mitochondrial DNA m.5522G > A mutation

Nesti C., Baldacci J., D'Amore F., Rubegni A., Santorelli F.M. *Molecular Medicine, IRCCS Stella Maris, Pisa*

Mitochondrial tRNAs are responsible for more than half of pathogenic point mutations in the mitochondrial genome (mtDNA). Different mutations give rise to widely differing phenotypes, ranging from isolated organ-specific diseases to multi-system conditions.

We report on a 40-year-old woman presenting with a complex multisystem phenotype. Family history was consistent with a brother who died at 2 months of age because of a heart muscle problem. Since adolescence, the patient complained of sensorineural hearing loss and retinopathy. She also presented severe dilated cardiomyopathy, diabetes mellitus and renal failure. Neurological examination was within normal limits. Muscle biopsy showed mild variation in fiber size with increased central nuclei and fiber type grouping. We also observed about 10% of COX negative-SDH positive fibers, but no clear ragged red.

Since clinic-anamnestic and muscle biopsy findings pointed to a mitochondrial disorder, we performed whole mtDNA sequencing and identified the m.5522G > A mutation in the tRNATrp gene. A specific PCR-based test showed that the variant was heteroplasmic in muscle (about 50% mutation load) and urine (5%) whereas it was almost undetectable in blood, skin fibroblasts, and buccal swab as well as in blood and urine from the healthy mother.

The m.5522G > A mutation has been reported once in a patient with mild muscle symptoms, elevated creatine kinase levels and histopathological findings of mitochondrial myopathy. Our patient, presenting a more severe, multisystem involvement, contributes to the genetic heterogeneity of mitochondrial diseases caused by mutations in mitochondrial tRNAs.

Mitochondrial dysfunction in a boy with Mevalonate kinase deficiency (MKD)

Oteri R.¹, Gallizzi R.², Ciranni A.¹, Rodolico C.¹, Zirilli G.², Arrigo R.¹, De Luca F.², Toscano A.¹, Musumeci O.¹

¹ Department of Clinical and Experimental Medicine; ² Department of Pediatrics, University of Messina, Messina Italy

Mevalonate kinase deficiency (MKD) is a very rare autosomal recessive autoinflammatory disease with multiple organ involvement. Two different forms have been described, a less severe phenotype called hyperimmunoglobulinemia D syndrome (HIDS) and a more severe and rarer phenotype, mevalonic aciduria (MVA). Clinical features include recurrent inflammatory attacks, with abrupt onset of high fever, growth retardation, dysmorphic, psychomotor retardation, progressive cerebellar ataxia and hypotonia.

MK is a key enzyme in the mevalonate pathway and is involved in the biosynthesis of cholesterol but also of coenzyme Q10. Cerebellar ataxia is a common feature of MKD and primary coenzyme Q10 deficiency suggesting a possible role of CoQ10 in MKD. Low levels of plasma CoQ10 has been rarely reported in MVA patients.

We report a 13 yrs old boy affected by MVA diagnosed in the first year of life who came to our observation because mild increased level of CK (max 400) and gait disturbances.

Muscle biopsy of vastus lateralis revealed some fibers with small vacuoles with lipid accumulation. Biochemical studies on muscle homogenate showed a reduction of complex I+III and II+III activities respectively 27% and 36%. Muscle Coenzyme Q10 was significantly reduced 14 ug/g (n.v. 25 ± 4). Patient started CoQ10 supplementation with no clinical relevant changes.

In our case the risk for CoQ10 depletion by direct inhibition of the proximal pathway of CoQ10 synthesis (MVA) but also a mitochondrial dysfunction have been confirmed by biochemical studies suggesting a role of oxphos impairment in the pathogenesis of MVA.

Glucose free/high protein diet ameliorates muscle performance in GSDIII mice

Pagliarani S.¹, Lucchiarini S.¹, Ulzi G.¹, Ripolone M.², Violano R.², Bordoni A.¹, Fortunato F.¹, Moggio M.², Comi G.P.¹

¹ Dino Ferrari Centre, Biochemistry and Genetics lab, Department of Pathophysiology and Transplantation (DEPT), University of Milan, Neurology Unit, IRCCS Foundation Ca' Granda Ospedale Maggiore Policlinico, Milan, Italy; ² Neuromuscular and Rare Diseases Unit, Department of Neuroscience IRCCS Foundation Ca' Granda Ospedale Maggiore Policlinico, Milan, Italy

Glycogen disease type III (GSDIII) is a monogenic disorder due to debranching enzyme deficiency. In infancy, main symptoms are hepatomegaly, hypoglycaemia, hyperlipidemia, high transaminase levels, and growth delay. Hepatic symptoms decline in adolescence, though fibrosis and adenomas may occur. Myopathy develops in adulthood and may progressively worsen to disability.

Recently, we developed a KO mouse model that reproduces the main symptoms of GSDIII.

We administered to AgI-KO mice 2 dietary regimens differing in protein and carbohydrate contents: high protein (HP; 48kJ% protein) and glucose free (GF; 64kJ% protein) diets.

Both diets ameliorated muscle performance, but mice fed with GF diet were able to run on a treadmill until 10 months of age vs 5 months of age for untreated mice and mice fed with HP

diet. Histological analysis showed decreased vacuolization of muscle fibres in mice fed with GF diet. In these mice, glycogen content was reduced in both skeletal muscle and heart and hepatomegaly was still reduced at 9 months of age. Serum analysis in fasted untreated-KO mice revealed a substantial increase of transaminases and CK, while in fasted GF mice parameters were stable.

These data are suggestive of a better metabolic compensation in mice treated with a glucose free/high protein diet. Liver expression profiling in GF mice showed an increased expression of genes that regulate gluconeogenesis and Krebs cycle indicating the use of dietary proteins both for the production of glucose to sustain glycaemia, and of energy to sustain the metabolic requirements of the liver itself.

Benign acute viral myositis: a clinical, pathological and serological study of five cases

Pancheri E.¹, Vattei G.¹, Ferrari S.¹, Zamò A.², Sartoris S.³, Lanzafame M.⁴, Angheben A.⁵, Tonin P.¹

¹ Department of Neurosciences, Biomedicine and Movement Sciences, Section of Clinical Neurology, University of Verona, Verona, Italy; ² Department of Pathology and Diagnostics, University of Verona, Verona, Italy; ³ Immunology Section, Department of Pathology and Diagnostics, University of Verona, Verona, Italy; ⁴ Department of Infectious and Tropical Diseases, University of Verona, Verona, Italy; ⁵ Centre for Tropical Diseases, Sacro Cuore-Don Calabria Hospital, Negrar, Verona, Italy

Viral myositis is an acquired form of inflammatory myopathy whose pathogenesis is not fully elucidated. A variety of viruses including orthomyxoviruses, enteroviruses, paramyxoviruses and herpes viruses have been supposed to cause acquired inflammatory muscle disorder. To date, however, only few studies assessed the pathological changes of muscle tissue in a setting of viral infection and myositis serological profile was never investigated. We report on five African migrants who presented clinical manifestations and laboratory signs of acute viral myositis with myoglobinuria. Muscle biopsies performed in four out of five patients clearly documented an inflammatory myopathy with the histological features of polymyositis including CD8+ T cells which invaded healthy muscle fibers, several CD68+ macrophages and MHC class I antigen up-regulation on the surface of most fibres. Sera from patients were tested for the presence of myositis-specific antibodies (MSAs) and myositis-associated antibodies (MAAs) and two of them were positive for anti-SRP, anti-PL12 and anti-PL7 antibodies. The authors discuss the possible pathogenic mechanisms, the specific serological profile and the treatment for viral myositis.

Lectin staining of skin biopsy is a convenient and sensitive tool to diagnose GNE myopathy

Parkhurst Y.¹, Pogoryelova O.², Eglon G.², Wake R.², Straub V.², Barresi R.^{1,2}

¹ Rare Diseases Advisory Group Service for Neuromuscular Diseases, Muscle Immunoanalysis Unit, Newcastle upon Tyne Hospitals NHS Foundation Trust, Newcastle upon Tyne, NE2 4AZ, UK; ² John Walton Muscular Dystrophy Research Centre, MRC Centre for Neuromuscular Diseases, Institute of Genetic Medicine, Newcastle University, Central Parkway, Newcastle upon Tyne, NE1 3BZ, UK

GNE myopathy is an autosomal recessive disorder characterized by distal muscle weakness and the relative sparing

of the femoral quadriceps muscle. The affected gene, GNE, encodes for an enzyme that catalyzes the first steps in the biosynthetic pathway of 5-N-acetylneuraminic acid (Neu5Ac, sialic acid). A diagnosis of GNE myopathy is based on a combination of clinical and pathological evidence and is confirmed by genetic testing. There is currently no robust immunohistochemical assay to diagnose the disease, although lectin staining of affected muscles has demonstrated hyposialylation of sarcolemmal proteins. We sought to implement lectin staining of muscle biopsies as a diagnostic biomarker for defects in the GNE gene. We tested a panel of lectins on specimens from controls and patients affected by GNE myopathy as well as other types of muscular dystrophy. Our findings indicated that the variable intensity of staining due to mild fibrosis across the tissue section might challenge the interpretation of the test. We then applied the same protocols to skin biopsy samples from controls and GNE patients. Positive lectin staining was observed in the arrector pili muscle of GNE samples, whereas no staining was seen in normal skin control tissues. We propose lectin staining in skin biopsies as a convenient and sensitive test for diagnosing GNE myopathy. This technique may be applied to suspected GNE patients, especially those having only one mutation detected, and as a tool to assess the efficacy of clinical trials.

Clinical and histological variability of RYR1 gene related myopathy: report of two novel cases

Pati A.R.¹, Di Donato I.¹, Mignarri A.¹, Salvatore S.¹, Berti G.¹, Cassandrini D.², Santorelli F.M.², Dotti M.T.¹, Malandrini A.¹

¹ Department of Medicine, Surgery and Neurosciences, Clinical Neurology and Neurometabolic Diseases, University of Siena, Siena, Italy; ² Molecular Medicine, IRCCS Stella Maris, Pisa, Italy

Ryanodine receptor (Ryr) is a calcium ion channel within sarcoplasmic reticulum membrane. Both dominant and recessive mutations of the Ryanodine receptor 1 (RYR1) gene have been described, which only sometimes can be related to central core disease (CCD).

We present two cases of myopathy linked to RYR1 mutations which differ for clinical and histological features. The first patient, a 50 year-old man of Moroccan origin, presented mild weakness, weight loss, and episodic myoglobinuria after exercises, since he was 37 year-old. His neurological examination showed distal mild weakness, distal hypotrophy, hypotonia, and areflexia. CK levels were increased. Mild myopathic pattern at neurophysiological exam was present. Muscle biopsy only showed moderate variation in fiber size. Ultrastructural examination revealed several agglomerates of lipofuscin. Genetic panel for muscular disease discovered c.C1163T/p.S388L heterozygous mutation of RYR1 gene. The second patient, a 50 year-old women, had weakness with difficulty in running and climbing stairs since childhood. CK levels and EMG were normal. Her mother had the same clinical pattern. Neurological exam showed mild anserine walking and positive Gowers' maneuver. Muscle biopsy showed: mild variation in fiber size, 7% internal nucleation, and type I uniformity with central core formations in almost all fibers. Genetic analysis revealed heterozygous mutation c.13913G > A (p.G4638D) of the RYR1 gene.

Our cases confirm the clinical and histological variability of RYR1 gene mutations associated disorders.

Down regulation of myomiRNAs and myostatin in DM1 after physical rehabilitation

Pegoraro V., Giaretta L., Cudia P., Baba A., Angelini C.
San Camillo Hospital IRCCS, Venice, Italy

Myotonic dystrophy type 1 (DM1), a multi-systemic autosomal dominant disorder, is the most common inherited muscular dystrophy in adulthood. DM1 is characterized mainly by progressive muscular weakness, myotonia, respiratory failure, cardiac defects, cataracts and cerebral involvement. MicroRNAs (miRNAs) are small non-coding RNAs that regulate post-transcriptional mRNA typically by binding to the 3' untranslated region of the complementary mRNA sequence, resulting in translational repression and gene silencing. MiRNAs are known to be secreted by various cell types and, unlike most mRNAs, they are markedly stable in circulating body fluids due to proteic protection from ribonucleases. MiR-1, miR-206, miR-133a and miR-133b are called "myomiRNAs" and are involved in myogenesis, maintenance and recovery of muscles. Myostatin, also known growth factor 8 (GDF8), acts as negative regulator of muscle. MyomiRNAs and myostatin are considered possible biomarkers of muscle atrophy. Rehabilitative intervention is useful to optimize muscle trophism and to prevent additional disuse muscle atrophy.

In this study we collected serum and plasma of 10 DM1 patients (9 male, 1 female) before (T0) and after (T1) a period of 3-6 weeks of physical FES/aerobic rehabilitation. We measured serum myomiRNA by qRT-PCR and myostatin by ELISA test. To evaluate endurance and gait speed we used the 6-minute walking test and the time 10-m walk test respectively. Both myomiRNA (miR-1, miR-206, miR-133a and miR-133b) and myostatin significantly decreased after aerobic/FES rehabilitation. Our study suggest that myomiR and myostatin levels could support clinical data. MicroRNAs should be considered good serum biomarkers of functional response to rehabilitation.

AGC-1 deficiency, a rare genetic demyelinating and neurodegenerative disease: from cell lines and a mouse model to human iPS-derived brain cells

Pena L.¹, Petralla S.¹, Bentivogli M.¹, Poeta E.¹, Sbrana L.², Danese A.², Corricelli M.², Giorgi C.², Pinton P.², Lasorsa F.M.³, Monti B.¹

¹ Dept. Pharmacy and BioTechnology, University of Bologna, Bologna, Italy; ² Dept. of Morphology, Surgery and Experimental Medicine, Section of Pathology, Oncology and Experimental Biology, Laboratory for Technologies of Advanced Therapies (LTIA), University of Ferrara, Ferrara, Italy; ³ Institute of Biomembranes and Bioenergetics IBBE, CNR, Bari, Italy

AGC-1 deficiency is a rare genetic syndrome caused by mutations in the SLC25A12 gene which encodes for the mitochondrial aspartate-glutamate carrier 1 (AGC-1). The disease is characterized by profound developmental delay and low levels of N-acetyl aspartate, myelin precursor in the CNS.

After observing an alteration in oligodendrocyte precursor cell (OPC) proliferation in the in vitro model (control and AGC-1-silenced OliNeu cells), we focused on the in vivo model (AGC-1 wild-type and heterozygous C57BL6N mice) confirming our previous results. Our data showed an increase in differentiation inducing factors (TGF- β) and a decrease in prolifera-

tion inducing factors (PDGF- α). Because our aim was to study proliferation defects in OPCs, in addition to analyzing adult animals we also focused on 21-day old mice since OPCs reach a peak in proliferation at this stage. We hypothesize that alterations of the analyzed pathways may disrupt the physiological cross-talk between neurons and OPCs, crucial for OPC proliferation and differentiation into oligodendrocytes and for myelin synthesis in the CNS.

Moreover, we focused on whether the reduction of AGC1 activity entailed with correct proliferation/growth of undifferentiated and mature neurons derived from Neural Stem Cells (NSCs) in an AGC1-deficiency mouse model (neurospheres obtained from adult mice subventricular zone (SVZ)). The aim of this research is to understand whether neural stem cell proliferation and differentiation into neurons, oligodendrocytes and astrocytes are affected in AGC-1 deficiency patients and eventually modulate normal neuronal stem proliferation and differentiation.

Does albuterol have an effect on neuromuscular junction dysfunction in spinal muscular atrophy?

Pera M.C.¹, Luigetti M.², Sivo S.¹, Lapenta L.¹, Granata G.², Antonaci L.¹, Coratti G.¹, Forcina N.¹, Pane M.¹, Mercuri E.¹

¹ Paediatric Neurology Unit, Catholic University and Centro Clinico Nemo, Rome, Italy; ² UOC Neurologia, Fondazione Policlinico Universitario A. Gemelli. Institute of Neurology, Catholic University, Rome, Italy

Background. Spinal muscular atrophy is a neuromuscular disease characterized by degeneration of α -motor neurons in the spinal cord. There has been increasing evidence that, in addition to muscle weakness, SMA patients may also experience fatigue and signs of impaired neuromuscular junction. The identification of fatigue may help to target patients who may benefit from drugs that facilitate neuromuscular transmission.

Methods/results. We report two type 3 SMA patients who were prospectively investigated with clinical and neurophysiological assessments following the introduction of albuterol.

The first patient was a 10 years old female, the second a 48 years old male patient.

Six minute walk test and low-rate repetitive nerve stimulation test were performed. The peak-to peak amplitude of the compound muscle action potential (CMAP) was measured.

Following the introduction of albuterol there was an improvement on both clinical and neurophysiological signs. These findings are concordant with the subjective reporting of patients on albuterol who often report an increase in stamina and less fatigability.

The concordance between clinical and neurophysiological findings appears to indicate a possible benefit of albuterol on neuromuscular junction.

Conclusions. Although these results should be interpreted with caution considering the small number of patients examined, our findings suggest to explore more systematically the role of neuromuscular junction as a potential therapeutic target in SMA patients.

Evaluation of multifrequency bioimpedance analysis (BIA) as a potential outcome measure for muscle involvement in myotonic dystrophy type 1 (DM1): a small pilot study

Perna A.¹, Rinninella E.², Cintoni M.², Ricci M.¹, Nicoletti T.F.¹, Rossi S.¹, Miggiano G.², Gasbarrini A.³, Mele M.C.², Silvestri G.¹

¹ Dept of Neurology, Fondazione Policlinico Gemelli, Università Cattolica Del Sacro Cuore, Roma; ² Clinical Nutrition and Dietetics, Fondazione Policlinico Gemelli, Università Cattolica Del Sacro Cuore, Roma; ³ Dept of Internal Medicine, Gastroenterology Area, Fondazione Policlinico Gemelli, Università Cattolica Del Sacro Cuore, Roma

Introduction. Muscular Impairment Rating Scale (MIRS), hand-held dynamometer, and muscle MRI represent validated clinical tools to assess the severity of muscle impairment in myotonic dystrophy type 1 (DM1). However, none of these tools appears sensitive enough to detect progression of muscle deterioration in DM1 patients in a relatively short time span characteristic of clinical trials. Therefore we performed a pilot study in a small cohort of DM1 patients aiming to test the reliability of multifrequency bioimpedance analysis (BIA) in correlation with MIRS.

Methods. 30 DM1 patients (50% males), stratified according to MIRS, underwent a multifrequency bioimpedance analysis (BIA) carried out using BodyStat 5000 (Bodystat LTD), evaluating two lean body mass measures, Phase Angle (PhA) at 50 kHz and Impedance Ratio (IR) at 200 kHz and at 5 kHz. Nutritional risk screening (NRS-2002) and body mass index (BMI) were also assessed as malnutrition predictors. Results were analyzed using Kruskal-Wallis test ($p < 0.05$ significant).

Results. Median age at the visit was 49 ys (range 37-60). 10% of DM1 patients had MIRS score = 2, 43.3% = 3, 30% = 4 and 16.7% = 5. 83.3% of DM1 patients had an NRS < 3, meaning a low nutritional risk, and only one patient was undernourished (BMI < 18.5). Statistical analysis documented a highly significant correlation between MIRS score, PhA and IR values [$p = 0.0001$].

Conclusions. Malnutrition risk and undernutrition were unfrequent in our DM1 population, so the tight correlation between BIA parameters and severity of muscular involvement, suggests that BIA might be a useful outcome measure of muscle progression in DM1.

Anti PABPN1 ABS in the diagnosis of OPMD

Peeverelli L.¹, Tironi R.¹, Scali M.¹, Lerario A.¹, Del Bo R.², Galimberti V.¹, Fagioli G.¹, Mora M.³, Rodolico C.⁴, Sciacco M.¹, Toscano A.⁴, Comi G.P.², Moggio M.¹

¹ Neuromuscular and Rare Diseases Unit, Department of Neuroscience Fondazione IRCCS Ca' Granda Ospedale Maggiore Policlinico, Milan, Italy; ² Dino Ferrari Center, Neuroscience Section, Department of Pathophysiology and Transplantation, University of Milan, Neurology Unit, IRCCS Foundation Ca' Granda Ospedale Maggiore Policlinico, Milan, Italy; ³ Division of Neuromuscular Diseases and Neuroimmunology, Fondazione IRCCS Istituto Neurologico "C. Besta", Milano, Italy; ⁴ Department of Clinical and Experimental Medicine, University of Messina, Italy

Oculopharyngeal muscular dystrophy (OPMD) is caused by an abnormal triplet expansion within PABPN1. Mutations in PABPN1 lead to protein aggregate deposition in muscle cell nuclei. Diagnosis of OPMD is so far mainly genetic. Muscle biopsy is considered unnecessary in OPMD diagnosis, due to

poor specificity of histological findings. Given the above the immunofluorescence recognition of PABPN1 protein nuclear aggregates is a well known immunostain technique so far used mainly for research purposes. Recently, few PABPN1 accumulations were also detected in a patient affected by IBMPFD (Inclusion body myopathy associated with Paget disease of bone and frontotemporal dementia) due to VCP mutation.

Preliminary we checked PABPN1 ab sensitivity and specificity in biopsies from patients with genetically confirmed OPMD showing in all of them diffuse nuclear positivity. We also test the abs on a patient affected by IBMPFD showing few positive nuclei. Hence immunostain was performed in a group of 50 patients presenting with at least one within ptosis, dysphagia or rimmed vacuoles at muscle biopsy. We found in 16 of them a diffuse nuclear positivity, followed by genetic OPMD confirmation; in 8 patients we only detected a scattered nuclear positivity, but genetic analysis made for VCP mutation was normal.

In conclusion, the immunofluorescence recognition of PABPN1 allowed us to discover 16 cases of OPMD previously misdiagnosed due to poor clinical-histological presentation. We could not confirm the association of PABPN1 positivity and VCP mutations. We also detect the presence of a group of undiagnosed patients with scattered, nuclear positivity still genetically unresolved.

Dampening of skeletal muscle excitability by carbonic anhydrase inhibitors through enhancement of chloride conductance

Pierno S.¹, Fonzino A.¹, Altamura C.¹, Imbrici P.¹, Liantonio A.¹, Carratù M.R.², Conte D.¹, Desaphy J.-F.²
¹ Dept. of Pharmacy, Drug Sciences, University of Bari Aldo Moro;
² Dept of Biomedical Sciences and Human Oncology, University of Bari Aldo Moro, Bari, Italy

The carbonic anhydrase (CA) inhibitor, acetazolamide (ACTZ), is empirically used in nondystrophic myotonia (Griggs et al., 1978). Its mechanism of action is not fully understood and may include metabolic acidosis, kaliuresis, or direct opening of Ca^{2+} activated K^{+} channels (Statland et al., 2018). ACTZ can also increase the activity of hCIC-1 chloride channels expressed in HEK293T cells (Eguchi et al., 2006; Desaphy et al., 2013). Whether other CAI exert a similar effect on hCIC-1 channels and whether such effect actually occurs in skeletal muscle is unknown. In this study, patch-clamp experiments show that, similarly to ACTZ, dichlorophenamide (DCP) increases chloride currents in HEK cells transfected with hCIC-1 channels, due to a negative shift of the open probability voltage dependence and slowing of deactivation kinetics. Bendroflumethiazide (BFT), structurally related to DCP but lacking CA inhibition, had no significant effect. In isolated rat muscle fibers, current-clamp studies with intracellular microelectrodes show a ~ 20% increase of the resting chloride conductance induced by 50-100 μM of ACTZ or DCP, but BFT. ACTZ also reduced by 39% the maximal number of action potentials in mouse muscle fibers. Fluorescence imaging of BCECF dye in rat muscle fibers indicated that ACTZ reduces intracellular pH to 6.8. Altogether, these results demonstrate that CAI can reduce muscle excitability by increasing CIC-1 channel activity, likely through intracellular acidification. Such a mechanism may contribute to the clinical effects of these drugs in myotonia and other muscle excitability disorders. Supported by Telethon-Italy (GGP14096) and Association Française contre les Myopathies (#19020).

Diagnostic approach in primary mitochondrial myopathy in the era of genomic medicine

Primiano G.¹, Carrozzo R.², Cuccagna C.¹, Colacicco G.¹, Marotta J.¹, Sancricca C.¹, Torraco A.², Verrigni D.², Servidei S.¹
¹ Institute of Neurology, Catholic University of the Sacred Heart, Rome, Italy; ² Unit of Neuromuscular and Neurodegenerative Disorders, Bambino Gesù Children's Research Hospital, Rome, Italy

Background. Mitochondrial myopathy is one of the most common manifestation of adult mitochondrial diseases (MDs), a group of disorders under the dual genetic control of nuclear (nDNA) and mitochondrial DNA (mtDNA). The predominant involvement of skeletal muscle characterize a group of a genetically heterogeneous conditions recently defined as Primary Mitochondrial Myopathy (PMM).

Purpose. In the era of the extensive use of next-generation sequencing (NGS) in the routine practice (with a yield of about 50% of negative results), we aim to demonstrate that clinical and laboratory phenotyping is essential to successfully obtain a genetic diagnosis.

Methods. We studied a cohort of 160 consecutive adult patients with PMM in which we have oriented genetic analysis on the basis of a clinical-laboratory algorithm. We then reviewed all the data in the light of the genetic results. Genetic studies encompassed mtDNA analysis or a targeted NGS panel including POLG, TWNK/PEO1, SLC25A4/ANT1, DGUOK, TYMP, OPA1.

Results. 121 (75.6%) had a mtDNA change, mtDNA deletion (62, 38.7%) or mtDNA point mutations (59, 36.9%); pathogenic nDNA changes were detected in 33 patients (20.6%): 16 POLG, 5 TWNK, 3 SLC25A4/ANT1, 2 DGUOK, 5 TYMP, 2 OPA1. Only 6 patients with autosomal dominant or recessive inheritance and multiple mtDNA deletions were negative with the panel and are undergoing NGS.

Conclusions. With this approach and the appropriate selection of the patients we have reached a final genetic diagnosis in 96% in the whole cohort of PMM and in 33/39 (84.6%) of patients harboring multiple mtDNA deletions.

Small fibre neuropathy in mitochondrial diseases explored with sudoscan

Primiano G., Luigetti M., Cuccagna C., Bernardo D., Sauchelli D., Vollono C., Servidei S.
 Institute of Neurology, Catholic University of the Sacred Heart, Rome, Italy

Objective. Polyneuropathy in mitochondrial diseases (MDs) is relatively common and widely investigated, but few data are instead reported about small fibres involvement.

Methods. To investigate the involvement of small fibres in MDs we performed extensive neurophysiological test (nerve conduction studies; sympathetic skin response; sudoscan) in 27 patients with genetic diagnosis of MD (7 m.3243A > G; 4 m.8344A > G; 9 single mtDNA deletion; 7 multiple mtDNA deletions).

Results. NCS showed a polyneuropathy in 11/27 cases (41%). The incidence was very high in POLG1 (100%), m.8344A > G (75%) and m.3243A > G (43%), while only 11% of patients with single deletion had evidence of large fibres involvement. Sympathetic skin response was abnormal only in three patients (one progressive external ophthalmoplegia with single mtDNA deletion; one patient with m.3243A > G mutation; one patient with POLG1 mutation). Sudoscan revealed the presence of an autonomic small fibres dysfunction in 9/27 cases (33%), most of them

(7/9) carrying a single mtDNA deletion. Sudoscan data were also confirmed in a sub-group of patients by laser evoked potentials study. Considering only patients with single mtDNA deletion 7/9 (78%) showed abnormal results at sudoscan.

Conclusions. Small fibre neuropathy is another feature to investigate in mitochondrial diseases and seems specifically associated with the presence of single mtDNA deletion.

Significance. The correct identification through specific neurophysiological tests of small fibres involvement in MDs represents another tile in this challenging diagnosis.

Effects of defective insulin signalling on skeletal muscle of myotonic dystrophy patients

Renna L.V.¹, Bosè F.¹, Brignonzi E.², Fossati B.³, Meola G.^{1,2,3}, Cardani R.¹

¹ Laboratory of Muscle Histopathology and Molecular Biology, IRCCS-Policlinico San Donato, Milan, Italy; ² Department of Biomedical Sciences for Health, University of Milan, Milan, Italy; ³ Department of Neurology, IRCCS Policlinico San Donato, Milan, Italy

Myotonic dystrophies (DM) are neuromuscular multisystemic disorders characterized by metabolic dysfunctions such as insulin resistance and a higher risk of developing Diabetes mellitus type 2 (T2DM). Insulin resistance is a risk factor for cardiovascular disease, neuropathy and loss of muscle mass, thus metabolic changes in DM patients might contribute to worsen some aspects of the disease at heart, skeletal muscle and brain level. Splicing alteration of insulin receptor (IR) gene is considered one of the causes of metabolic dysfunctions, however it cannot be excluded that post-receptor signalling abnormalities may be involved. The aim of this study is to investigate whether post-receptor abnormalities contribute to insulin resistance in DM patients and whether deregulated metabolism pathways might be involved in muscle alterations. Insulin pathway activation has been investigated in insulin stimulated skeletal muscle biopsies obtained from 8 DM1, 2 DM2, 6 CTR and 1 T2DM patients. Histopathology and alternative splicing pattern of several genes involved in skeletal muscle function have been analysed. ERK1/2 involvement has been investigated in myotubes treated with the MEK inhibitor U0126. Our results indicate that DM skeletal muscle exhibits high basal phosphorylation of AKT, GSK3 β and ERK1/2. Moreover, insulin action appears to be impaired in DM samples as compared to CTR. Glucose uptake performed in DM myotubes has shown that the specific decrease of ERK activity can lead to an increase in insulin dependent glucose uptake. In conclusion, our studies show an alteration in activation of several proteins of insulin pathway that might contribute to DM insulin resistance.

Clinical variability of Becker muscular dystrophy: tools to identify phenotypic subgroups

Ricci G.¹, Florio F.¹, Astrea G.², Baldanzi A.¹, Simoncini C.¹, Rocchi A.¹, Baldinotti F.³, Giannoni A.³, Aquaro G.D.³, Emdin M.³, Siciliano G.¹

¹ Department of Clinical and Experimental Medicine, University of Pisa, Pisa, Italy; ² Department of Developmental Neuroscience, IRCCS Stella Maris, Calambrone (Pisa), Italy; ³ Laboratory of Medical Genetics, Azienda Ospedaliero-Universitaria Pisana, S. Chiara Hospital, Pisa, Italy; ⁴ Cardiology Division, University of Pisa, Italy; Fondazione Toscana Gabriele Monasterio, Pisa, Italy

Becker muscular dystrophy (BMD) is characterized by a heterogeneous clinical expression. Genotype-phenotype cor-

relation studies and biomarkers of progression are needed to better define prognosis and outcome measures toward trial readiness. Here, we present a detailed characterization of 28 BMD patients (aged 20-70 years) and correlation analysis between genotype, clinical outcome and muscle MRI qualitative evaluation. Patients were stratified based on the type of dystrophin deletion/point mutation, the degree of motor impairment (Fatigue Severity Scale, MRC scale, Walton&Gardner-Medwine Scale, North Star Ambulatory Assessment, 6-Minutes Walking Test) and cardiac involvement (echocardiography and cardiac MRI). Cognitive-behavioral profiles were also evaluated. Qualitative analysis of standard muscle MRI was performed to study the distribution of muscle fatty substitution in pelvic girdle and lower limb (Mercuri scale). A quantitative muscle MRI protocol was also developed in order to obtain an automatic analysis of anatomical features such as geometry and signal intensity of muscle and fat tissues. Our analysis confirmed some genotype-phenotypes correlations, showing that patients with deletion of exon 48 or multi-exon deletions bordering exon 51 are associated to a mild muscle phenotype, but it failed to identify a clear correlation with the cardiac involvement.

Dystrophinopathies in couples of brothers: take the differences, if any

Rossi M.^{1,2}, Scalise R.³, Ricci F.⁴, Bello L.⁵, Rolle E.⁶, Balottin U.^{1,2}, Mongini T.⁶, Mercuri E.³, Pegoraro E.⁵, Berardinelli A.¹

¹ Unit of Child and Adolescence Neurology, National Neurological Institute C. Mondino, Pavia; ² Dept. of Brain and Behavioural Sciences, Unit of Child Neurology and Psychiatry, University of Pavia, Italy; ³ Department of Pediatric Neurology, Catholic University, Rome, Italy; ⁴ Department of Neurosciences "Rita Levi Montalcini", University of Turin, Turin, Italy; ⁵ Department of Neurosciences, University of Padua, Padua, Italy; ⁶ Neuromuscular Center, SG. Battista Hospital, University of Turin, Turin, Italy

Dystrophinopathies (Duchenne and Becker muscular dystrophy) are X-linked inherited neuromuscular disorders due to mutations in the dystrophin gene, which respectively cause complete or partial lack of dystrophin in muscle fibers.

It is well known that dystrophinopathies can vary in clinical expression between patients and attempts have been done to correlate these differences with molecular defects. Very few data are available in literature about couples of brothers/twins as to the clinical evolution in this cohort of patients.

We describe here clinical and laboratory data of 19 couples and 3 trio of brothers affected by DMD and 23 couples and 3 trio of brothers affected by BMD, accounting for 92 patients affected by dystrophinopathies. All of these patients have definite diagnosis of DMD/BMD based upon histological study and/or molecular analysis of dystrophin gene.

We propose a phenotypic analysis based on the first signs of disease, early neurodevelopmental milestones and the presence and the degree of muscular, cardiac and respiratory impairment (age at onset and progression) and brain involvement (described by the type and the severity of cognitive impairment). Aim of this work is to highlight phenotypic variability within the natural history of the disease or similarity among siblings, guiding future phenotype-genotype correlations and analysis of modifier genes and epigenetic factors.

Complex IV deficiency due to a novel SCO2 mutation associated with progressive cavitating leukoencephalopathy

Rubegni A.¹, Nesti C.¹, Doccini S.¹, Morani F.¹, D'Amore F.¹, Pasquariello R.², Canapicchi R.², Ferrari A.R.³, Santorelli F.M.¹

¹ Molecular Medicine, IRCCS Stella Maris, Pisa; ² Neuroradiology, IRCCS Stella Maris, Pisa; ³ Child Neurology, IRCCS Stella Maris, Pisa

Recessive mutations in the mitochondrial copper-binding protein SCO2, involved in cytochrome c oxidase (COX) assembly, have been reported in several cases with different phenotypes ranging in severity from fatal cardio-encephalo-myopathy to early-onset axonal Charcot-Marie-Tooth disease.

We describe the case of a 3-year-old girl born to neurologically healthy, consanguineous parents. Family history was significant for a brother who died at the age of 12 months for an undiagnosed cardiac malformation. At the age of 13 months, the patient had a global regression of motor and language skills after a febrile episode. She was first referred to us when she was age 2 due to apostural tetraparesis, diffuse muscle atrophy with absent speech and severe mental retardation. At that time, brain MRI showed diffuse cavitating leukoencephalopathy.

Histochemical and cytochemical analyses of muscle biopsy and skin fibroblasts showed a diffuse reduction of COX stain in the patient. Biochemically, we observed about 40% reduction of the activity of complex IV in muscle compared to controls. Using a targeted resequencing panel in next generation sequencing, we identified a homozygous missense mutation in SCO2. This variant was heterozygous in the parents and has predictably damaging effects when examined in silico. Western blot analysis showed a reduction of subunit COII on patient's fibroblasts.

The presence of cavitating leukoencephalopathy, a condition associated with defects of the mitochondrial energy metabolism, is a novel finding associated with mutations in SCO2, expanding the phenotypic spectrum in COX-deficiency disorders.

NGS in diagnosis: identification of causative mutations in cases with misleading clinical phenotype

Ruggieri A.¹, Saredi S.¹, Gibertini S.¹, Peverelli L.², Lerario A.², Bernasconi P.¹, Brugnoli R.¹, Savarese M.³, Udd B.³, Maggi L.¹, Mora M.¹

¹ Neuromuscular Diseases and Neuroimmunology Unit, Fondazione IRCCS Istituto Neurologico C. Besta, Milano, Italy; ² Neuromuscular and Rare Diseases Unit, Department of Neuroscience, Fondazione IRCCS Ca' Granda, Ospedale Maggiore Policlinico, Milano, Italy; ³ Folkhälsan Research Center, University of Helsinki, Helsinki, Finland

Thanks to the use of NGS in our diagnostic practice, we were able to genetically define some cases in which the clinical phenotype was misleading. Here we present a few illustrative cases.

The first patient, a 70-year-old woman, with long history of asymptomatic hyperckemia since her 40s, began complaining of mild pelvic girdle weakness at age 68. Screening with a LGMD-related gene panel detected mutations in GAA. Subsequent specific test confirmed mild reduction of muscle acid maltase activity.

Two 55-year-old twins presenting in their early infancy with proximal upper and lower limb weakness had for long-time a diagnosis of unspecified vacuolar myopathy due to a muscle biopsy showing several autophagic vacuoles. A further EMG analysis

suggested a neuromuscular junction disease, which was finally confirmed with NGS showing a novel DPAGT1 mutation.

The third case was a 54-year-old woman considered as possible sIBM according to the ENMC criteria. Her muscle biopsy indeed presented rimmed vacuoles, but also non-rimmed vacuoles. NGS revealed a mutation in CACNA1S, and non rimmed vacuoles were reconsidered as related to hypokaliemic periodic paralysis, which however she had never experienced.

Indeed the introduction of NGS strategies in the routine clinical settings, in addition to faster and cost effective diagnosis, allows the resolution of cases with clinical misleading phenotype, further confirming the great phenotypic variability associated to a single gene in neuromuscular disorders.

Multidisciplinary care in infant neuroaxonal dystrophy-related symptoms: a case report of two twins

Salmin F.¹, Carraro E.¹, Moscardi M.¹, Moretini V.¹, Albamonte E.¹, Sansone V.A.^{1,2}

¹ NEuroMuscular Omnicentre (NEMO) Fondazione Serena Onlus, Milano, Italy; ² Neurorehabilitation Unit, Department Biomedical Sciences for Health, University of Milan, Milan, Italy

Introduction. Infant neuroaxonal dystrophy (INAD) or Seitelberger disease is an autosomal recessive and neurodegenerative disease with onset in early childhood; it presents rapid motor and cognitive decline or loss of neurodevelopmental skills. INAD has been reported to exhibit numerous phenotype features, including problems associated with vision, hearing, seizures and physical coordination.

Clinical cases. We present a case of two 8 years old twins with Seitelberger disease, daughters of consanguineous parents. The children were born from normal-term pregnancy, from c-section. First symptoms occurred around two years of age, with delayed psychomotor development followed by regression, initial which ataxic and extrapyramidal syndrome associated with pyramidal signs resulting in a spastic tetraplegia. Molecular exam showed two mutations in homozygosity of the PLA2G6 gene (exons 12 and 15). There was a generalized disorganization of the EEG activity. MRI showed cerebellar atrophy and hypointensity of the basal ganglia.

Current examination reveals several tetraplegia, mental delay, visual problems related to optic disc pallor, nutritional problems requiring gastrostomy, and neurogenic bladder treated with intermittent catheterization.

Discussion. The treatment of INAD-related symptoms is of paramount importance when taking care of these patients. In this case-study article we show the crucial importance of a multidisciplinary team facing these diseases.

An RNA-Seq-based picture of splicing pattern in adult human skeletal muscle

Savarese M.¹, Jonson H.¹, Huovinen S.², Paulin L.³, Auvinen P.³, Udd B.^{1,2,4}, Hackman P.¹

¹ Folkhälsan Research Center, University of Helsinki, Helsinki, Finland; ² Department of Pathology, Fimlab Laboratories, Tampere University Hospital, Tampere, Finland; ³ Institute of Biotechnology, University of Helsinki, Helsinki, Finland; ⁴ Vaasa Central Hospital

A high number of multi-exonic genes undergo alternative splicing events (ASEs) which are often tissue-specific or differentiation stage-dependent. The differential splicing is part of a complex process able to modulate protein-protein interactions

and, similarly, affect the protein length modifying its structural and functional properties.

We performed a RNA-Sequencing experiment on 42 human biopsies collected from 12 anatomically different skeletal muscles of 11 individuals without any muscle disorders in order to map ASEs in adult human skeletal muscles.

Largest human genes are highly expressed in skeletal muscles. The 364-exon TTN gene, for example, encodes titin, a giant protein with multiple functions in skeletal and cardiac muscles. We have identified and partly characterized a large number of titin ASEs, providing the first RNA-Seq-based picture of TTN splicing pattern in adult human skeletal muscle. Moreover, by using a long-read sequencing technology (PAC-BIO), we mapped several ASEs along the same molecule.

By using a similar approach, we demonstrated a similar complex splicing pattern for other muscle transcripts and we identified previously unreported exons in well-known muscle disease genes.

A comprehensive expression profiling in different muscular tissues (heart and skeletal muscles) and/or different pathological and physiological states (e.g., fetal versus adult) would further deepen our understanding of genotype-phenotype correlations.

Homozygous deletion of AGTPBP1 in a child with motor neuron disease and cerebellar atrophy

Scala M.¹, De Marco P.¹, Merello E.¹, Tassano E.¹, Ronchetto P.¹, Lanteri P.², Picco P.³, Severino M.S.⁴, Fiorillo C.⁵, Capra V.¹

¹ Neurogenetic and Neurosurgery, Istituto G.Gaslini, Genoa; ² Neurophysiology Unit, Istituto G.Gaslini, Genova; ³ Pediatric Clinic, Istituto G.Gaslini, Genova; ⁴ Neuroradiology Unit, Istituto G.Gaslini, Genova; ⁵ Pediatric Neurology and Neuromuscular Disorders, Istituto G.Gaslini, Genoa

AGTPBP1 encodes for a cytosolic carboxypeptidase, involved in neuronal regeneration, embryonic nervous tissue differentiation and dendritic development of cerebellar cells. To date, mutations of this gene have been described in an murine model of hereditary ataxia and in sheep with lower motor neuron disease (LMND). In human, the functions of AGTPBP1 are unclear and no distinctive phenotype has been associated, albeit a role in the pathogenesis of amyotrophic lateral sclerosis has been suggested.

Here we report the first human patient with homozygous deletion of AGTPBP1, presenting a fatal motor neuron disease phenotype combined with cerebellar atrophy.

A 6-month-old child was evaluated for severe hypotonia and failure to thrive since age 3 months. Neurological examination revealed severe flaccid tetraparesis with generalized muscular hypotrophy, areflexia and tongue fasciculation. Electromyography revealed polyphasic motor unit potentials with increased amplitude and duration, suggestive of a neurogenic damage. Brain MRI showed hypoplasia of the pons and cerebellar atrophy involving the anterior lobe and the vermis.

A CGH-array detected a homozygous 174-kb deletion of 9q21.33, which contained AGTPBP1. The homozygous deletion was confirmed by PCR and FISH detected the heterozygous deletion in parents.

The similarities between the animal models and our patient phenotype advocate a role of AGTPBP1 in human cerebellar development and in the survival of lower motor neurons.

These findings widens the spectrum of the genes involved in LMND and recommend to search for AGTPBP1 mutations in children with rapidly progressive LMND combined with cerebellar atrophy.

Isolated, long-standing weakness in jaw closure as presenting symptom of myasthenia gravis

Schirinzi E.¹, De Rosa A.¹, Maestri M.¹, Ricciardi R.², Siciliano G.¹

¹ Department of Clinical and Experimental Medicine, Neurological Clinic, University of Pisa; ² Cardiothoracic and Vascular Surgery Department, University of Pisa

If masticatory function is rarely compromised in Myasthenia Gravis (MG), even more the exclusive involvement of the masticatory muscles is an uncommon finding.

Here we describe the unusual presentation of difficulty in achieving jaw closure causing masticatory bite force reduction, which prompted the investigation and recognition of the diagnosis of MG.

A 68-year-old man with a poor clinical history progressively had been unable to comfortably and completely chew his food because he could not close his jaws and he used his hand to push the mandible superiorly

He denied the presence of dysphagia, dysarthria or pain in the region of the temporomandibular joint and associated muscles. Several dental consultations and imaging studies excluded temporomandibular joint dysfunction.

On neurological examination, any weakness, clinical symptoms of internal derangement or a myofascial component or range motion problem of the temporomandibular joint resulted. Bilateral masseter and temporal muscle atrophy was noticed. There was no evidence of ptosis or eyes movements deficit or weakness in other muscle districts. The electromyography study, including that of the facial district, was normal.

Based on these results, MG was suspected and confirmed by the specific antibodies search, which revealed a slight increase of acetylcholine receptor antibodies and moderate of anti-titin ones.

A CT scan of the chest did not reveal evidence of a thymoma. Definitive medical management included daily administration of pyridostigmine with an improvement of the clinical picture.

MG is an uncommon auto-immune disorder with a typical initial presentation which includes ocular symptoms of ptosis, diplopia, or both. Herein, we describe a case of isolated, long-standing weakness in jaw closure which is uncommon for a patient with MG, underlying the importance to consider this disease within the differential diagnoses when the common etiologies of difficult chewing are eliminated.

International DMD: a PTC therapeutics-supported project to widely identify dystrophin mutations using NGS technology

Selvatici R., Trabanelli C., Neri S., Rossi R., Fini S., Rimessi P., Falzarano M.S., Venturoli A., Neri M., Gualandi F. and Ferlini A.

Unit of Medical Genetics, Dept. Medical Sciences - University of Ferrara (Italy)

Extensive molecular diagnosis in genetic diseases is vital to confirm clinical diagnosis and to enable genetic counseling and personalized management. Duchenne muscular dystrophy

(DMD) is a rare genetic neuromuscular disease affecting 1 in 5.000 male births worldwide, due to a variety of dystrophin gene mutations. Since 2016, PTC Therapeutics International Ltd. and the University of Ferrara, Italy, have established a collaboration focused on identifying patients affected by rare genetic disorders through increased genetic testing activities, with an initial focus on DMD. Genetic testing is available to patients throughout European countries and other regions.

Diagnostic settings include MLPA (MRC-Holland) and NGS dystrophin gene sequencing (Multiplicom).

Currently, DNAs from Poland (50), Hungary (17), Lithuania (6), Romania (7), Russia (1), Bosnia (4), Croatia (2) Bulgaria (13) Cyprus (2), Ucraina (1) and Algeria (40) were collected for a total of 143 samples.

Analyses have been completed in 125 patients. MLPA screening identified 35 samples with large deletions/duplications, while NGS analysis identified 31 nonsense, 15 small del/dup, 15 splice site and 3 missense mutations. Twenty-six (26) patients were negative for both MLPA and NGS analyses, suggesting the presence of atypical mutations.

Notably, among the small mutations identified so far (64), 50% are nonsense and 25% are canonical splice site mutations.

The early identification of the underlying genetic mutation is critical for the standard of care including treatment choice and eligibility for clinical trials. Genetic counselling can also be offered to patients and families via a telegenetics service (www.ospfe.it/medicalgenetics).

A transitional care experience with 3 patients affected different neuromuscular disorders

Siciliano G.¹, Astrea G.², Santorelli F.², Baldanzi S.¹, Ricci G.¹

¹ Department of Clinical and Experimental Medicine, University of Pisa; ² IRCCS Stella Maris, Calambrone, Pisa

Neuromuscular disorders (NMDs) are multisystem disorders with different etiologies that raised in the last years high interest because of the high variable clinical spectrum and related disability. Individuals with NMDs are affected not only by muscle weakness and progressive motor impairment, but frequently present also behavioural problems and intellectual disability, finally impacting on their degree of engagement in family, work and leisure activities.

The transition phase, representing the process of moving from adolescence to adulthood, can be severely affected by growing up with a neuromuscular disorder, with significant impact on patient's and families' quality of life. Although conceptual models of health assistance for individual with genetic disorders have already been proposed, the burden for the patient and his family is still relevant. Therefore to afford this critical condition it would be suitable to plan proper educational and psychosocial programs, identifying areas of unmet needs and targeted health objectives that ensure the right support to NMD population.

Here we present 3 different neuromuscular case reports, one with spinal muscular atrophy (SMA), another with myotonic dystrophy type 1 (DM1) and a third affected by Duchenne muscular dystrophy (DMD), describing a feasible clinical management strategy to improve compliance to treatments and effective psychological support to patients and their relatives, with the final aim to properly bridge the gap between childhood and adult age in this critical field of healthcare.

Non-skeletal canonic muscle involvement as prominent feature in Pompe disease: two case reports

Simoncini C.¹, Ricci G.¹, Montano V.¹, Chico L.¹, Calì Cassi L.², Ali G.³, Comi G.⁴, Baldinotti F.⁵, Cosini C.⁵, Lembo F.⁵, Siciliano G.¹

¹ Department of Clinical and Experimental Medicine, University of Pisa; ² Department of Musculoskeletal and Skin Diseases, and Hand Surgery, University of Pisa, Pisa; ³ Unit of Pathological Anatomy, University of Pisa, Pisa; ⁴ Neurology Unit, IRCCS Fondazione Ca' Granda Ospedale Maggiore Policlinico, University of Milan, Milan, Italy; ⁵ Laboratory of Molecular Genetics, Department of Laboratory Medicine, Azienda Ospedaliero Universitaria Pisana, Pisa, Italy

Case 1. A 44 year old man arrived to our attention with one-year history of low back pain and mild hyperCKemia (300 UI/L). In anamnesis, he referred only hearing loss. Neurological examination showed asymmetric winged scapula. DNA testing for FSHD was negative. Respiratory muscle function was normal, however the muscle magnetic resonance imaging revealed a mild edema and fatty infiltration in right thigh and leg.

Case 2. A 43 year old woman came to our attention for acute respiratory failure and hyperCKemia (500 UI/L). She reported a one year history of progressive lower limb edema and dyspnea. Neurological examination also revealed pelvic girdle weakness. Cardiovascular examination showed right heart failure. Respiratory muscle function demonstrated FVC values of 66% (sitting) and 34 % (supine). Muscle magnetic resonance imaging (MRI) revealed prominent edema of the thigh and leg and fatty infiltration of the adductors, paraspinal and quadriceps.

Both patients performed muscle biopsy, that showed several fibres with vacuoles that stained positively for glycogen and acid phosphatase. The GAA activity in muscle was reduced and genetic test confirmed the diagnosis of Pompe disease. Only Patient 2 started enzyme replacement therapy (ERT).

Discussion. The late-onset form is characterized by wide variability in residual enzyme activity, disease progression and phenotypical spectrum. Although the pathological process mainly affects the skeletal muscle, several other tissues can be involved in the course of the disease.

Generation of induced pluripotent stem cells (hiPSCs) as cellular model to study the central nervous system pathogenesis of Myotonic Dystrophy type 2 (DM2)

Spitalieri P.¹, Talarico V.¹, Murdocca M.¹, Fontana L.¹, Campione E.², Massa R.³, Meola G.⁴, Novelli G.¹, Sangiuolo F., Botta A.¹

¹ Department of Biomedicine and Prevention, Division of Genetics, University of Rome Tor Vergata, Rome, Italy; ² Department of Systems Medicine, Division of Dermatology, University of Rome Tor Vergata, Italy; ³ Department of Systems Medicine, Division of Neurology, University of Rome Tor Vergata, Italy; ⁴ ????

Human induced pluripotent stem cells (hiPSCs) are an innovative tool to study multisystemic disorders because this cell type can be derived from patients as a renewable source for unlimited cells that are difficult to acquire. Myotonic dystrophy type 2 (DM2) is caused by an unstable (CCTG)_n expansion in intron 1 of the CNBP gene leading to a progressive multisystemic disease with muscle, heart and central nervous dysfunctions. The pathogenesis of CNS involvement in DM2 is poorly understood since no cellular or animal

models fully recapitulate the molecular and clinical neurodegenerative phenotype of patients. In this study, we generated for the first time two DM2 and two wild type hiPSC lines from dermal fibroblasts by lentiviral transduction using the hSTEMCCA-loxP polycistronic vector (containing hOct4, hSox2, hKlf4, and hc-Myc sequences). The stemness of DM2 and wild type-derived hiPSCs has been confirmed by specific morphological, molecular, immunocytochemical markers and by their teratogenic potential when inoculated in vivo. These cells can self-renew indefinitely but in the same are able to differentiate into neuronal population (NP) expressing tissue specific markers. HiPSCs-derived NP cells maintain the major specific DM2 hallmarks such as CCTG expansion and intranuclear RNA foci, pathognomonic of the disease. The availability of reprogrammed hiPSCs represent an important tool for the study of CNS pathogenesis and potential drug discovery of DM2.

Myotonic dystrophy in Abruzzo

Telese R.¹, Carlino R.¹, Barbone F.¹, Vitale M.¹, Rastelli E.², Lozzi F.², Massa R.², Di Muzio A.¹

¹ Center for Neuromuscular Disease, Chieti, Italy; ² Unità Malattie Neuromuscolari, Policlinico Tor Vergata, Rome, Italy

Myotonic dystrophy (DM) is the second most common muscular dystrophy, the most common among adult Caucasians. Two genetically and clinically different MD types are distinguished: DM1 and DM2. They are autosomal dominant multisystem disorders, caused by expansion of CTG and CCTG unstable repeats in the DMPK and the ZNF9 gene, respectively.

The MD prevalence among Europeans has been estimated at 12.5 per 100,000. In Italy, only two epidemiological study of DM has been performed, with an overall prevalence estimate of 9.311 and 9.652 per 100,000, in Padova and North-West Tuscany and in the Rome province, respectively.

The aim of our study is to collect data about DM patients and evaluate DM prevalence in Abruzzo.

Methods. We reviewed data of DM patients resident in Abruzzo. We have considered genetically determined DM1 and DM2 with their clinically affected relatives. We used ISTAT data on Abruzzo population.

Results. By March 2018, 109 alive MD patients of the Neuromuscular Center of Chieti and 12 from the Tor Vergata DM Network Registry were diagnosed (121 in total, 68 females). On estimated population of 1,322,760 people in Abruzzo, the disease prevalence is 9.15 per 100,000. **CONCLUSION:** our data suggest a prevalence of DM on Abruzzo similar than previously reported in Italian population. This collection of data is the essential basis for a more extensive national disease register and important for establishing patients' database and performing power calculation studies for future clinical trials.

Involvement of interleukin-6 and vitamin D interplay in controlling visceral adiposity in myotonic dystrophy type 1.

Terracciano C.^{1,2}, Frezza E.¹, Greco G.¹, Rastelli E.¹, Bernardini S.², Nuccetelli M.², Massa R.¹

¹ Neuromuscular Unit, Division of Neurology; ² Clinical Biochemistry Unit, University of Rome Tor Vergata, Rome

Several features of metabolic syndrome may be present in Myotonic Dystrophy type 1 (DM1) including increased visceral adiposity. Inadequate vitamin D status has been associated with obesity and we recently demonstrated a reduction of circulating 25-hydroxyvitamin D (25(OH)D) in DM1 patients. Moreover, in vitro and animal studies suggest that vitamin D has modulating effects on pro-inflammatory cytokines, among them interleukine-6 (IL-6). Inflammation is recognized as an underlying characteristic of obesity, and serum levels of IL-6 have been described to be significantly higher in subjects with obesity.

To verify a relationship between vitamin D, IL-6 and visceral adipose tissue (VAT), we measured serum levels of 25(OH)D and IL-6, and waist circumference in 27 patients with DM1, 15 without and 12 with cholecalciferol supplementation therapy. A chemiluminescent immunoassay was used to assess 25(OH)D levels, while commercially available sandwich enzyme-linked immunoabsorbent assays (ELISA) were used to evaluate IL-6 serum levels.

In the untreated DM1 subgroup, levels of IL-6 were significantly increased compared to normal controls. In both treated and untreated patients, serum IL-6 inversely correlated with 25(OH)D levels and displayed a highly direct correlation with VAT.

In conclusion, in DM1 patients, an increase of circulating IL-6 levels seems to be related to vitamin D deficiency. In addition, IL-6 levels appear to contribute to the presence of increased visceral adiposity described in DM1 patients. Treatment with cholecalciferol seems to reduce IL-6 levels but larger studies are necessary to ascertain whether vitamin D supplementation might ameliorate metabolic-endocrine dysfunctions typical of DM1.

The nation-wide Italian collaborative network of mitochondrial diseases: a cross-sectional survey on mitochondrial epilepsies

Ticci C.¹, Ardisson A.², Bertini E.³, Carelli V.⁴, Diodato D.³, Di Vito L.⁴, Filosto M.⁵, La Morgia C.⁴, Lamperti C.², Martinelli D.³, Moroni I.², Musumeci O.⁶, Pancheri E.⁷, Peverelli L.², Primiano G.⁸, Rubegni A.¹, Servadei S.⁸, Siciliano G.⁹, Simoncini C.⁹, Tonin P.⁷, Toscano A.⁶, Mancuso M.⁹, Santorelli F.M.¹

¹ IRCCS Stella Maris, Calambrone, Pisa; ² The Foundation "Carlo Besta" Institute of Neurology-IRCCS, Milan, Italy; ³ Bambino Gesù Hospital IRCCS, Rome, Italy; ⁴ IRCCS Institute of Neurological Sciences of Bologna, Bellaria Hospital, Bologna, Italy; ⁵ University Hospital Spedali Civili, Neurological Clinic, Brescia, Italy; ⁶ Department of Clinical and Experimental Medicine, University of Messina, Messina, Italy; ⁷ Neurological Clinic, University of Verona, Verona, Italy; ⁸ Institute of Neurology, Catholic University, Rome, Italy; ⁹ Neurological Clinic, University of Pisa, Pisa, Italy

The "Nation-wide Italian Collaborative Network of Mitochondrial Diseases" is the largest database collecting clinical and molecular characteristics in mitochondrial disorders (MDs) patients. Clinical studies using the database have already helped to define better genotype-phenotype correlations in Italian MD patients.

Having prepared an online questionnaire using Google Form® to explore epilepsy features, our goal was to perform a cross-sectional study to explore main clinical and EEG features in a population of patients with MDs adopting a multicenter dataset.

Retrospective data were collected in 100 patients. Patients were genetically heterogeneous; the most frequent mtDNA mutations were the m.3243A > G (41%) and the m.8344A > G (17%); nDNA mutations were found in 9% of the patients. In our cohort, epilepsy started at a mean age of 28 years with generalized (44%) or focal (37%) seizures, and was the first clinical manifestation in 46/98 individuals. Most patients (93%) displayed multiple seizures, with sporadic/monthly frequency in 73%, and a higher rate ($\geq 1/\text{week}$) in 27%. EEG abnormalities were seen in 70/78 individuals, with abnormal background in 48, and multifocal/diffuse or focal paroxysms in 53. Ninety-four patients were under AEDs (monotherapy in 44% and polytherapy in 56%).

Patients harboring mutations in nuclear genes presented an earlier onset of epilepsy ($p = 0.001$), a higher frequency of seizures ($p = 0.0001$), and a worse response to AEDs ($p = 0.04$).

Epilepsy is a major feature of MD. This study further displays the success of truly data sharing and represents the first Italian multicenter survey of epilepsy in MDs.

The mitochondrial DNA m.10197G > A mutation in three children with Leigh Syndrome

Tolomeo D.¹, Rubegni A.¹, Cassandrini D.¹, Pochiero F.², Bruno C.³, Di Rocco M.³, Doccini S.¹, Madeo A.³, Donati M.A.², Rossi A.³, Santorelli F.M.¹, Nesti C.¹

¹ IRCCS Fondazione Stella Maris, Pisa; ² Meyer Children Hospital, Florence; ³ G. Gaslini Institute, Genova

Complex I is the largest complex of the mitochondrial respiratory chain (MRC) and it is made of 7 mitochondrial DNA (mtDNA)-encoded and 38 nuclear DNA-encoded subunits. Isolated complex I deficiency is the most common single enzyme defect in the heterogeneous group of MRC disorders and a relatively common etiology in Leigh-like syndrome (LS).

Here we describe three unrelated Italian children who had different clinical presentations and harbored the homoplasmic m.10197G > A mutation in MT-ND3 associated with a reduction of the enzyme activity of complex I in muscle. The first patient was a 7-year-old boy presenting with subacute onset of dystonia, which had remitting-relapsing clinical course. The second boy, aged 5, presented diffuse hypotonia with limb dystonia, strength reduction and muscle atrophy. The third child, a 4-year-old-boy, presented with pes valgus, speech impairment, progressive left-sided hemiparesis, postural instability and gait difficulty. In all the children neuroimaging findings were consistent with the features of LS.

Among the variable clinical presentations of mitochondrial disorders, to date only few patients harboring the m.10197G > A in MT-ND3 have been described. Clinical presentations is wider than expected and spans from severe encephalopathies falling under the umbrella of LS spectrum to single tissue involvement as in Leber Hereditary Optic Neuropathy. Our results confirm that m.10197G > A mutation, initially reported as a rare polymorphism depicting specific mtDNA haplogroup, could be relevant to patients' clinical and biochemical phenotypes.

Laminopathy caused by a novel missense mutation

Torchia E.^{1,2}, Garibaldi M.^{1,2}, Bucci E.^{1,2}, Ficili S.¹, Bertini E.S.³, Fattori F.³, Pennisi E.M.¹

¹ San Filippo Neri Hospital, Neurology Unit, Rome; ² S.Andrea Hospital, Neurology Unit, La Sapienza University; ³ Neuromuscular and Neurodegenerative Diseases Unit, Bambin Gesù Pediatric Hospital, IRCCS

Laminopathies are a group of heterogeneous disorders associated with mutations of lamin A/C gene (LMNA), that encodes for nuclear envelop proteins, encompass a wide spectrum of clinical phenotypes, presenting as distinct or overlapping clinical syndromes, including cardiac, metabolic, neuromuscular or progeroid syndromes. Mutations on LMNA gene cause mainly three forms of autosomal dominant myopathy: limb-girdle phenotype (LGMD 1B), Emery Dreyfuss congenital myopathy (EDMD2) or cardiomyopathy (LMNA-CMD).

We describe a 38-year-old female of Rumanian origin, who complained about pelvic weakness, with difficulties in rising from the floor and myalgias since the age of 20 years. The clinical examination showed short stature, cushingoid morphotype and distal hypotrophy of lower limbs. No contractions or scapular winging were detected. Respiratory function was normal. Laboratory findings revealed a normal CK level. EMG showed chronic myopathic alterations. MRI she presented substitution in brachial and femoral biceps, glutei, vasti, semitendinosus, semimembranosus, adductor major and brevis muscles. Muscle biopsy revealed just minimal myopathic changes. No worsening of muscle weakness was observed during seven years of clinical follow up. By contrast, the patient suffered of atrio-ventricular block and at the age of 37 had a cardioembolic stroke because of atrial fibrillation. She is waiting for defibrillator implantation.

Molecular screening for LMNA gene revealed a novel heterozygous missense mutation c.938T > C (p.L313P) falling in coil-1b domain. This mutation causes in our patient most prominent cardiac features, unlike most other described missense mutations. The muscle phenotype differs from classical LGMD phenotype for his mainly expression in lower limb and axial muscles. Our report expand the genetic spectrum on laminopathies.

Novel TRIM32 mutation in sarcotubular myopathy

Traverso M.¹, Panicucci C.¹, Baratto S.², Gazzero E.⁴, Iacomino M.³, Pozzolini G.³, Broda P.¹, Madia F.³, Zara F.³, Gazzero E.⁴, Bruno C.², Minetti C.¹, Fiorillo C.¹

¹ Neurologia Pediatrica e Malattie Muscolari, Istituto G.Gaslini e Università di Genova, Genova; ² Centro di Miologia Traslazionale e Sperimentale, Istituto G.Gaslini, Genova; ³ Laboratorio di Neurogenetica, Istituto G.Gaslini, Genova; ⁴ Experimental and Clinical Research Centre, Charité Universitäts Medizin, Berlin

otif-containing protein 32 (TRIM32) is a member of the TRIM ubiquitin E3 ligases, characterized by a RING finger, B-box, and coiled-coil domains. TRIM32 also possesses a unique NHL domain at the C-terminus. Main role of TRIM32 in muscle is ubiquitination of different substrates in muscle including sarcomeric proteins such as desmin and myotilin.

Mutations in TRIM32 are associated with Limb-Girdle Muscular Dystrophy 2H, a very rare form of autosomal recessive muscular dystrophy, initially described in the Manitoba Hutterite population.

In a 66 old woman with disto-proximal myopathy and in his deceased brother, we identified a novel homozygous mutation of TRIM32 c.1781G > A, p.Ser594Asn localised in the c-terminus NHL domain. Molecular modelling showed that this mutation alters specifically the correct conformation of the NHL domain. Mutations of this domain have been also associated to Sarcotubular Myopathy (STM), a form of distal myopathy with peculiar features in muscle biopsy, now considered in the spectrum of LGMD2H. Indeed muscle biopsy of our patients revealed severe abnormalities of the myofibrillar network with core like areas, lobulated fibres, whorled fibres and multiple vacuoles. Desmin and myotilin staining also pointed to accumulation as in myofibrillar myopathy, conversely western blot analysis showed only modest reduction of TRIM32 expression. We interpreted these findings as result of altered ubiquitination of these proteins which are known substrates of TRIM32.

This report further confirm that STM and LGMD2H represent the same disorder and suggest to consider TRIM32 mutations in the genetic diagnosis of myofibrillar myopathies.

In conclusion, muscle biopsy study albeit considered an invasive procedure, is important to confirm or exclude the clinical suspect and to successfully target the genetic investigations.

TRPV4-associated disorders: intrafamilial variability.

Tripodi S.M., Martinelli I., Semplicini C., Bello L., Sorarù G., Pegoraro E.

Neuromuscular Center, Department of Neurosciences, University of Padova, Padova.

The TRPV4 gene encodes a transient receptor potential (TRP) cation channel of the vanilloid subfamily, which is implicated in the regulation of physiological processes in multiple systems. The expression pattern of TRPV4 includes brain, motor neurons, spinal roots, and cartilage. TRPV4 mutations have been identified in a spectrum of autosomal-dominant osteodysplastic and neuromuscular disorders: Charcot-Marie-Tooth disease type 2C (CMT2C), scapuloperoneal spinal muscular atrophy (SPSMA) and congenital distal spinal muscular atrophy (CDSMA). We report a 36-year-old female patient, born with arthrogryposis, talipes equinovarus, scoliosis, and severe proximal and distal lower limb muscle weakness. She acquired the ability to ambulate with double support at age of six. No clinical progression was observed over time. Electromyography and muscle biopsy performed during childhood showed a neurogenic pattern. The test for deletion of SMN1 gene was negative. A NGS panel of genes involved in non-5q spinal muscular atrophies (SMA) revealed the heterozygous c.806G > A; p.Arg269His mutation in the TRPV4 gene. Neither parent carried the c.806G > A mutation, consistent with a de novo event.

The patient gave birth to three children, two of whom were affected. A 5-year-old boy presented with clubfoot and cervico-axial hypotonia, while his 4-year old brother presented with congenital arthrogryposis.

The c.806G > A TRPV4 gene mutation has been previously reported in familial cases of SPSMA, CDSMA and CMT2C. Phenotypic features in this family are consistent with a lower-limb-predominant motor neuron disease associated with arthrogryposis, and are representative of the clinical heterogeneity of TRPV4-related diseases.

Novel COL6A3 mutation in two sibs with congenital muscular dystrophy

Trovato R.¹, Rubegni A.¹, Melani F.², Sorbo M.², Cassandrini D.¹, Baldacci J.¹, Doccini S.¹, Santorelli F.M.¹

¹ IRCCS Fondazione Stella Maris, Pisa; ² Meyer Children Hospital, Florence

Collagen VI-related myopathy, caused by variants in the genes encoding collagen VI (COL6A1, COL6A2, and COL6A3), represents a clinical continuum from Ullrich congenital muscular dystrophy to Bethlem myopathy. Here we describe two siblings, born from healthy consanguineous parents, presenting with neonatal hypotonia and congenital contractures, and harboring a novel mutation in COL6A3.

The first child was a 4-year old girl presenting at birth with respiratory distress, hip dislocation and diffuse hypotonia. Last neurological examination showed diffuse muscle atrophy with limb girdle and wrists weakness. Respiratory and cardiac functions were normal.

The 14-month-old brother came to our attention for diffuse muscle hypotonia, hyperlaxity of distal joints and respiratory insufficiency.

Muscle biopsy in the first child showed severe variation in fiber size with internal nuclei and increased connective tissue. Immunofluorescence labeling revealed reduced level of Collagen VI in muscle fibers.

We used MuscleChip, a targeted molecular tool in next-generation sequencing (NGS) designed to analyze 241 genes known to be responsible of different inherited myopathies. We identified a novel homozygous mutation in COL6A3 gene that was confirmed by Sanger sequencing in both siblings. This variant was heterozygous in the parents and has predictably damaging effects when examined in silico with Polyphen2 and SIFT.

Collagen VI immunofluorescence staining in skin fibroblast from the elder sister showed that the protein is not detectable in the extracellular matrix.

Our report confirm the importance of NGS screening combined with the use of muscle biopsy as powerful and faster tool for genetic diagnosis in highly heterogeneous neuromuscular diseases.

Congenital myopathy due to RYR1 mutations: early findings at muscle biopsy and muscle MRI in neonatal cases

Velardo D.¹, Magri F.¹, Govoni A.¹, Brusa R.¹, Sciacco M.², Peverelli L.², Fagioli G.², Cinnante C.³, Piga D.², Dilella R.⁴, Cassandrini D.⁵, Corti S.¹, Bresolin N.¹, Moggio M.², Comi G.P.¹

¹ Dino Ferrari Centre, Neuroscience Section, Department of Pathophysiology and Transplantation, Neurology Unit, IRCCS Foundation Ca' Granda Ospedale Maggiore Policlinico, University of Milan, Milan; ² Neuromuscular and Rare Diseases Unit, Department of Neuroscience, IRCCS Foundation Ca' Granda Ospedale Maggiore Policlinico, Dino Ferrari Centre, University of Milan, Milan; ³ Neuroradiology Unit, IRCCS Foundation Ca' Granda Ospedale Maggiore Policlinico, Milan, Italy; ⁴ Pediatric Epileptology Service, Clinical Neurophysiology Unit, IRCCS Foundation Ca' Granda Ospedale Maggiore Policlinico, Milan, Italy; ⁵ Molecular Medicine, IRCCS Fondazione Stella Maris, Pisa, Italy.

Congenital myopathies (CM) due to mutations in RYR1 gene, encoding ryanodine receptor, are characterized by high heterogeneity regarding inheritance, clinical presentation, disease progression and histopathological features.

Among a cohort of 9 patients affected by CM with pathogenic RYR1 mutations we focused on 4 severe congenital cases. Diagno-

sis was obtained through Sanger Sequencing or Next Generation Sequencing. All subjects underwent neurological evaluation, muscle biopsy and muscle magnetic resonance imaging (MRI).

Patients presented at birth with severe weakness and hypotonia. The most severe cases required long-term artificial ventilation and percutaneous endoscopic gastrostomy. RYR1 study showed 3 novel mutations. Muscle biopsies showed a heterogeneous pattern, occasionally with unusual signs (mitochondrial oxidative activity deficiency, neurogenic features). Interestingly two biopsies were performed at a very young age, respectively at 5 and 37 days of life, and revealed abnormalities at ultrastructural analysis. Muscle MRI showed predominant involvement of gluteus maximus, adductor magnus, vastus and soleus muscles, with rectus femoris relative sparing. Intrauterine brain MRI imaging was available for one patient.

Since now only few cases of neonatal RYR1-related myopathies with early muscle biopsy and MRI have been described. We report four neonatal cases with precocious evaluations. Muscle biopsy was not always specific, but typical features could be detected also at few days of life. Muscle MRI generally showed a typical pattern. These findings further enlarge our knowledge on this heterogeneous disorder.

Monozygotic twins with reduced D4Z4 fragment on chromosome 4 and different phenotype: which other factors in etiopathology?

Vercelli L., Tupler R., Bortolani S., Ponzalino V., Mele F., Govi M., Mongini T.

Department of Neuroscience University of Turin, Turin; Miogen Lab, Department of Biomedical Sciences, University of Modena and Reggio Emilia

Two 12-years-old female monozygotic twins came to our observation for the presence of facial muscle weakness in one sister; their birth was preterm to the 34 week of gestational age and APGAR score was 9/9 for both newborns. Motor and cognitive milestones were normal for both sisters. At the age of 6, one sister developed a neurosensorial hearing loss and later visual deficits with bilateral retinal angiomas. Brain MRI did not show other vascular abnormalities. Neurological examination revealed bilateral facial and eyes muscles weakness, and weakness in leg extension; scapular winging or foot drop were not present. Muscle MRI showed bilateral fatty infiltration in biceps femoris, semimembranosus,

vastus lateralis, adductor and soleus muscles as well as in gluteus muscles; inflammatory changes in STIR (short tau inversion recovery) sequences were also evident. Neurological evaluation was negative for the other sister. Molecular analysis on chromosome 4 showed a marked reduced fragment in both children (12 kb). Genetic analysis was extended to their parents who were negative for D4Z4 deleted fragments. Secondary factors (rheumatological, infectious, endocrinological diseases) were currently excluded. Visual defect progressed and now the young girl has lost her vision in the right eye. We are proceeding to perform muscle biopsy to exclude abnormalities in other structural proteins and possibly whole generation sequences to evaluate the genetic pattern.

Mutations in the SYNE1 gene cause autosomal recessive CMD: the first case report

Vita G.L., Sframeli M., Astrea G., D'Amico A., Bertini E., Santorelli F.M., Vita G., Messina S.

The synaptic nuclear envelope protein-1 gene (SYNE1) encodes nesprin-1, which presents two major isoforms, alpha and beta. Nesprin-1 alpha has been shown to be highly expressed in skeletal and heart muscles. Nesprin-1 interacts with proteins involved in myopathies like the muscle specific-tyrosine kinase (MuSK), lamin A and emerin.

Autosomal dominant mutations in SYNE1 have been associated with Emery-Dreifuss muscular dystrophy (EDMD) type 4 and intellectual disability with spastic paraplegia whereas several autosomal recessive mutations have been identified in patients with a diagnosis of spinocerebellar ataxia or myogenic multiplex arthrogryposis congenital.

We describe a patient with the diagnosis of congenital muscular dystrophy (CMD) with cerebellar involvement (CMD-CRB) in whom we identified biallelic mutations in the SYNE1 gene.

The disease showed a progressive course, the patient developed severe kyphoscoliosis at 7 years, and also showed a restrictive lung disease requiring a permanent tracheotomy and ventilator assistance since he was 12-year-old, he never had heart involvement. The patient tolerated oral alimentation until 11 years of age, when a Percutaneous Endoscopic Gastrostomy (PEG) was positioned and the nutrition support was managed exclusively via the enteral route.

XVIII CONGRESSO NAZIONALE

AIM Associazione Italiana di Miologia

Informazioni Scientifiche



SESSIONI POSTER

I poster - dimensioni cm 95 di larghezza x cm 238 di altezza - potranno essere affissi a partire da Mercoledì 6 Giugno ore 13.00 e rimanere esposti per tutta la durata del Congresso.

I poster dovranno essere ritirati entro le ore 14.00 di Sabato 9 Giugno.

I poster che non saranno ritirati a fine evento non saranno restituiti.

Un pannello numerato sarà riservato ad ogni poster ed il materiale per l'affissione sarà disponibile presso la Segreteria del Congresso.

Gli autori sono pregati di essere presenti nell'area poster per la presentazione dei loro contributi nelle fasce orarie dedicate.

La presentazione dei contributi scientifici è subordinata all'iscrizione al Congresso.

CENTRO SLIDE

I Relatori potranno caricare le proprie presentazioni (salvate su penna USB) presso il Centro Slide, localizzato al primo piano, dopo aver concluso le pratiche di registrazione e comunque almeno un'ora prima del proprio intervento. Il formato ottimale per le presentazioni è la videoproiezione di presentazioni in Power Point. Non sono previsti altri formati.

Le presentazioni saranno trasferite direttamente dal Centro Slide al computer di sala. I PC del Centro Congressi utilizzano Microsoft Office 2013.

I file di eventuali filmati/video e di eventuali immagini dovranno essere nella stessa cartella di Power Point e dovranno essere copiati nella cartella prima di essere inseriti nella presentazione.

Per i filmati e i video sono consigliate le estensioni ".avi" e ".mpeg".

Non è previsto l'uso di PC personali per la presentazione nella sala.

Genova 6 - 9 Giugno 2018 | Magazzini del Cotone



ACCREDITAMENTO ECM



Il Programma Scientifico di questo Congresso ha ottenuto dal Ministero della Salute **n. 6 crediti formativi**. Il numero massimo di partecipanti è 300.

Professione	Discipline
Farmacista:	<i>Farmacia Ospedaliera; Farmacia Territoriale;</i>
Biologo:	<i>Biologo;</i>
Logopedista:	<i>Logopedista;</i>
Terapista Occupazionale:	<i>Terapista Occupazionale;</i>
Psicologo:	<i>Psicoterapia; Psicologia;</i>
Medico Chirurgo:	<i>Cardiologia; Genetica Medica; Malattie Metaboliche e Diabetologia; Malattie Dell'apparato Respiratorio; Medicina Fisica e Riabilitazione; Neonatologia; Neurologia; Neuropsichiatria Infantile; Pediatria; Chirurgia Pediatrica; Neurochirurgia; Ortopedia e Traumatologia; Anestesia e Rianimazione; Laboratorio di Genetica Medica; Neurofisiopatologia; Neuroradiologia; Pediatria (pediatri di libera scelta); Scienza dell'alimentazione e dietetica;</i>
Infermiere Pediatrico:	<i>Infermiere Pediatrico</i>
Fisioterapista:	<i>Fisioterapista</i>
Infermiere:	<i>Infermiere</i>
Dietista:	<i>Dietista;</i>
Tecnico di Neurofisiopatologia	<i>Tecnico di Neurofisiopatologia; Terapista della Neuro e Psicomotricità dell'età Evolutiva; Terapista della Neuro e Psicomotricità dell'età Evolutiva</i>

Avranno diritto ai crediti ECM solo coloro che saranno presenti almeno al 90% delle ore totali previste dal Congresso ed avranno compilato il questionario di apprendimento e di valutazione nonché la scheda anagrafica. La rilevazione delle presenze avverrà attraverso la firma di presenza, da apporre ad inizio e fine giornata.

Il questionario dovrà essere riconsegnato al personale addetto all'uscita della sala al termine del Congresso. Sarà cura del partecipante ritirare il materiale ECM al desk registrazioni.

XVIII CONGRESSO NAZIONALE

AIM Associazione Italiana di Miologia




Sede Congressuale

SEDE DEL CONGRESSO

Porto Antico di Genova - Magazzini del Cotone

Centro Congressi, SALA MAESTRALE

Via Magazzini del Cotone - modulo 10

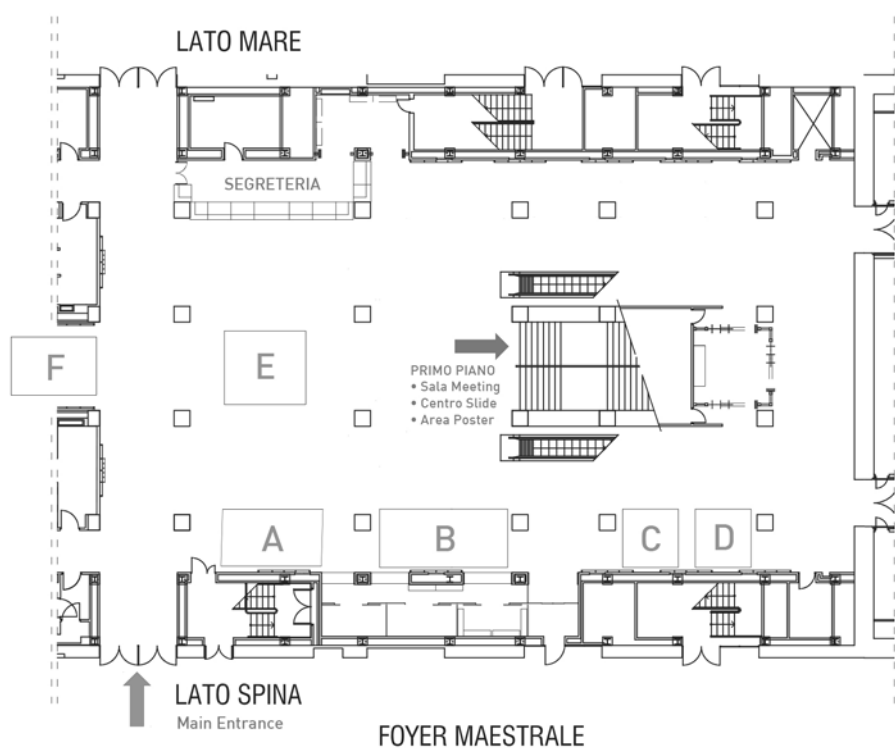


PORTO ANTICO DI GENOVA
CENTRO CONGRESSI

Genova 6 - 9 Giugno 2018 | Magazzini del Cotone



Area Congressuale



Legenda

A: PTC Therapeutics
B: BIOGEN
C: ROCHE

D: Sarepta
E: Sanofi-Genzyme
F: Deposito bagagli

XVIII CONGRESSO NAZIONALE

AIM Associazione Italiana di Miologia

Informazioni generali

Sito web del Congresso:

www.fclassevents.com/it/aim2018/

ISCRIZIONI:

	In sede congressuale <i>(IVA inclusa)</i>
*Socio AIM	€ 355,00
Non Socio AIM	€ 385,00
Under 35	€ 230,00
Accompagnatore	€ 215,00

**Socio AIM in regola con le quote associative*

La quota di iscrizione include:

Ammissione alle sessioni scientifiche

Coffee break e colazioni di lavoro

Attestato di partecipazione, kit congressuale, badge nominale, programma

La quota prevede l'invito alla cena sociale dell'AIM, Venerdì 8 Giugno

La quota di iscrizione per gli Accompagnatori include:

Accesso all'area espositiva ed aree pubbliche

Coffee break e colazioni di lavoro

1 biglietto per la Cena Sociale di Venerdì 8 Giugno

Segreteria Organizzativa e Provider ECM 362

First Class srl

Viale Italia, 173 - 57128 Livorno

Tel. 0586.849811 - Fax 0586.349920

email: elena.falciola@fclassevents.com



La Segreteria Organizzativa First Class

sarà a disposizione dei partecipanti in Sede Congressuale nei seguenti orari:

Mercoledì, 6 Giugno	 h.13.00 – h.19.30
Giovedì, 7 Giugno	 h. 07.00 – h. 19.00
Venerdì, 8 Giugno	 h. 07.00 – h. 19.00
Sabato, 11 Giugno	 h. 07.45 – 14.00

Genova 6 - 9 Giugno 2018 | Magazzini del Cotone



BADGE

Il badge nominativo è incluso nella documentazione congressuale da ritirare presso il desk della Segreteria Organizzativa, all'atto della registrazione.

I Congressisti sono pregati di indossarlo durante tutti i lavori scientifici perché è prova della regolare iscrizione al Congresso e dà accesso a tutti gli spazi della sede congressuale ed ai servizi catering.

ATTESTATI DI PARTECIPAZIONE

Gli attestati di partecipazione saranno disponibili per tutti i partecipanti a partire dalle ore 10.00 di Sabato 9 Giugno.

CENA SOCIALE

La cena sociale si terrà Venerdì 8 Giugno ore 20:30.

La partecipazione alla serata è riservata agli iscritti al Congresso.

Si prega di ritirare l'invito presso il desk della Segreteria Congressuale entro **Mercoledì 6 Giugno, alle ore 19:30**. L'ingresso sarà consentito solo dietro presentazione del relativo invito.



XVIII CONGRESSO NAZIONALE

AIM Associazione Italiana di Miologia

Con la sponsorizzazione non condizionante di

SANOFI GENZYME 





XVIII CONGRESSO NAZIONALE

AIM Associazione Italiana di Miologia

Con la sponsorizzazione non condizionante di

BioMARIN
BioMarin Europe Ltd.



GRIFOLS 





BOLOGNA

NEWS FROM AROUND THE WORLD

AIM

The 18th Congress of the Italian Association of Myology will be held in Genoa on 6-9 June 2018, organised by Prof. Carlo Minetti. The symposium was in the traditional three-days format with selected topics. The final program can be found at page 9 of the present issue.

MSM

The 13th Congress of the Mediterranean Society of Myology will be held in Avanos, Turkey on 27-29 June 2018, organised by Prof. Haluk Topaloglu. The symposium was in the traditional three-days MSM format with selected topics. The meeting will focus on the recent advances in genetic, clinical and therapeutic approach in Limb-girdle muscular dystrophies. The program is available on page 101 of this issue.

WMS

The 23rd International Congress of the World Muscle Society will be held in Mendoza, Argentina from 2 to 6 October 2018. The symposium will follow the traditional format with 3 selected topics:

- New developments in genetic and acquired disorders of the neuromuscular junction.
- Mitochondrial function and dysfunction in neuromuscular disorders: pathogenesis and therapies.
- Advances in the treatment of neuromuscular disorders.

One day of the symposium will be dedicated to each of the selected topics. Invited keynote speakers will summarize the state of the art on the selected topics, covering clinical, molecular and other aspects. The sessions will comprise selected oral papers and poster presentations with guided discussions. Contributions will also be welcome on new advances across the neuromuscular field. The 16th WMS Pre-Congress Teaching Course will be held on 1-2 October 2018. Please note only 45 places are available. Early booking is advised.

FORTHCOMING MEETINGS

2018

March 8-9

Orphan Drugs & Rare Diseases Global Congress 2018 Europe, London, UK. Information: website: www.orphandrugscongress.com

May 20-24

ISBER 2018 Annual Meeting & Exhibits. Dallas, Texas, USA. Information: website: <http://meetings.isber.org>

June 1-3

236 ENMC Workshop: Bone protective therapy in Duchenne Muscular Dystrophy: Determining the feasibility and standards of clinical trials (BONE). Organisers: Prof Volker Straub, Dr. Jarod Wong, Prof Leanne Ward and Dr. Ros Quinlivan. Information: website: <http://www.enmc.org>

June 6-9

18th National Congress of Italian Association of Myology. Genua, Italy. Information: website: www.miologia.org

June 16-19

European Human Genetics Conference 2018. Milan, Italy. Information: website: conference@eshg.org

June 16-19

4th Congress of the European Academy of Neurology. Lisboa, Portugal. Information: website: www.ean.org

June 27-29

XIII Congress of Mediterranean Society of Myology. Avanos, Cappadocia, Turkey. Information: msm2018@flaptour.com.tr; htopalog@hacettepe.edu.tr

July 6-10

15th International Congress on Neuromuscular Diseases (ICNMD2018), Wien, Austria. Information: www.icnmd2018.org

August 25-29

European Society of Cardiology (ESC). Munich, Germany. Information: website: <https://www.escardio.org/>

September 4-7

Europe Biobank Week: Biosharing for scientific discovery. Antwerp, Belgium. Information: website: <http://europebiobankweek.eu>

September 14 - 16

237 ENMC workshop: GNE myopathy (also known as HIBM, Nonaka disease, and quadriceps sparing myopathy) (GNEM). Organisers: Prof Hanns Lochmüller,

Dr. Andoni Urtizberea, Prof Zohar Argov and Prof Ichizo Nishino. Information: website: <http://www.enmc.org>

October 2-6

23rd Congress of World Muscle Society. Mendoza, Argentina. Information: website: www.worldmusclesociety.org

October 16-20

ASHG Annual Meeting. San Diego, CA, USA. Information: website: www.ashg.org

October 17-21

Asia Pacific Heart Rhythm Society (APHRS). Taipei, Taiwan. Information: website: <http://www.aphrs.org/>

October 24-25

9th World Congress on Targeting Mitochondria, Berlin, Germany. Information: website: <https://targeting-mitochondria.com/>

October 31-November 02

World Congress on Human Genetics. Valencia, Spain. Information: website: <http://humangenetics.conferenceseries.com/>

November 9-10

9th International Conference & Exhibition on Tissue Preservation and Biobanking. Atlanta, USA. Information: website: <http://biobanking.conferenceseries.com>

November 30-December 2

238 ENMC Workshop: Updating management recommendations of cardiac dystrophinopathy (CARDIAC). Organisers: Dr. John Bourke, Prof Denis Duboc, Dr. Michela Guglieri and Dr. Teresinha Evangelista. Information: website: <http://www.enmc.org>

2019

May 2019

Heart Rhythm 40th Annual Scientific Sessions (HRS). Chicago, IL. Information: website: <http://www.hrsessions.org/>

June 15-18

The European Human Genetics Conference 2019. Gothenburg, Sweden. Information: conference@eshg.org

September 24-28

24th Congress of World Muscle Society. Copenhagen, Denmark. Information: website: www.worldmusclesociety.org

October 22-26

ASHG Annual Meeting. Toronto, Canada. Information:
website: www.ashg.org

To be announced

Asia Pacific Heart Rhythm Society (APHRS). Bangkok,
Thailand. Information: website: <http://www.aphrs.org/>

October 27-31

ASHG Annual Meeting. San Diego, CA, USA. Information:
website: www.ashg.org

To be announced

25th Congress of World Muscle Society. Toronto, Canada.
Information: website: www.worldmusclesociety.org

2020**June 6-9**

The European Human Genetics Conference 2020, Berlin,
Germany. Information: conference@eshg.org



13th Meeting of the Mediterranean Society of Myology

This congress is memory of our late Professor Giovanni Nigro, one of the first pioneers for neuromuscular research in the Mediterranean area

in connection with the

2nd Congress of the Turkish Neuromuscular Society

27-29 June 2018

Avanos, Cappadocia, Turkey



Organization Secretariat



Podgoritsa Caddesi No:1, 06610
Birlik-Çankaya-Ankara / Turkey
Phone: +90 312 454 0000
Fax: +90 312 454 0001

Topics of the congress: Limb-girdle muscular dystrophies, Advances in the field

Extra activity 1: 26-27 June 2018, Clinical neuromuscular course for physicians

Extra activity 2: 27 June 2018, Outcome measures course for physiotherapists

CONTENTS

A grayscale background image showing a large hot air balloon with a checkered pattern in the foreground on the left. In the distance, other smaller hot air balloons are visible against a hazy sky. The foreground also shows rocky, uneven terrain.

3

INVITATION

4

COMMITTEES & KEY FIGURES

5

SCIENTIFIC PROGRAMME

7

**TOPICS & PARTICIPANTS &
IMPORTANT DATES**

8

CAPPADOCIA

9

BENEFITS OF SPONSORS

10

SPONSORSHIP CATEGORIES

11

SPONSORSHIP ITEMS

15

APPLICATION FORM

INVITATION

Dear Colleagues,

Thirty-six years ago, a group of researchers with interest in the field of muscular dystrophies felt the need to promote a mutual cooperation among the people of the Mediterranean area, and created the Mediterranean Society of Myology in 1993, in Ischia.

The initiative had a rapid success with the accession of the representatives of 22 Mediterranean Countries and was a model to establish other International Societies of Myology, such as the European NeuroMuscular Center-ENMC (established in 1992 by Ysbrandt Portman, Reinhardt Rudel and myself) and the Word Muscle Society (established in 1995 by Victor Dubowitz, Luciano Merlini and myself)

The presence of the Turkish delegates has always enriched the value of the Society, and the organization of the 13th Congress attests their contribution.

Therefore I am very pleased and grateful to Prof. Haluk Topaloglu for accepting the task (and load) of the Congress organization, and I'm convinced it will be a successful event.

I hope that many of you will be present next year in Cappadocia.

Giovanni Nigro
30 April 2017

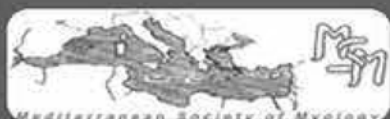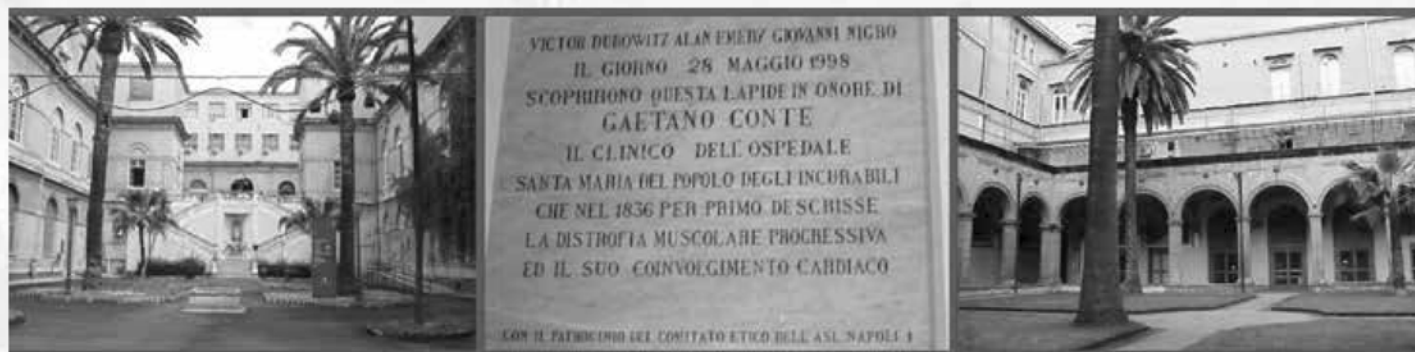
Dear Colleagues,

We invite you to attend the 13th Meeting of the Mediterranean Society of Myology (MSM) in Cappadocia, Turkey, June 27-29 2018. MSM has been originated in Italy, rapidly escalated, and within a decade has become an internationally renown group of enthusiasts. Bi-annual meetings have been traditional. With the spirit we have received from the past congresses of the Society, it will be our aim to bring researchers together with interest in basic and clinical science. The special topic for this congress has been chosen as "limb-girdle muscular dystrophies". We shall try our best to create an exciting programme. This congress will jointly be done with the 2nd Turkish Myology meeting.

Cappadocia which was the population zone of the Assyrian civilization later has hosted the Hittite, Frig, Pers, Byzantine, Seljuk and Ottoman civilizations. Cappadocia is an important tourism site in Turkey.

We think that your visit to Cappadocia in the summer of 2018 will be rewarding academically and educationally, and also from the social aspects.

Prof. Haluk Topaloglu
President of the Mediterranean Society of Myology



**13th Meeting of the Mediterranean Society of Myology
in connection with the
2nd Congress of the Turkish Neuromuscular Society**

28-30 June 2018 | Avanos, Cappadocia, Turkey

COMMITTEES & KEY FIGURES

Congress Presidents

Giovanni Nigro, Haluk Topaloğlu

Local Organizing Committee

İpek Alemdaroğlu (secretary)

Hayat Erdem

Göknur Haliloğlu

Ayşe Karaduman

Müjgan Sönmez

Beril Talim

Öznur Yılmaz

Uluç Yiş

Board of the Mediterranean Society of Myology

President

H. Topaloglu

Vice-Presidents

L.T. Middleton and G. Siciliano

Secretary

K. Christodoulou

Treasurer

L. Politano

Members

E. Abdel-Salam

M. Dalakas

F. Deymeer

F. Hentati

G. Meola

Y. Shapira

E. Tizzano

A. Toscano

J. Zidar

Board of the Turkish Neuromuscular Society

President

G. Kale

Secretary

M. Sönmez

Treasurer

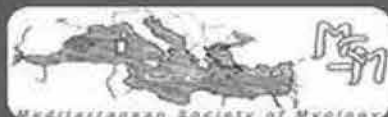Ö. Yılmaz

Members

A. Karaduman

B. Talim

H. Topaloğlu



13th Meeting of the Mediterranean Society of Myology
in connection with the
2nd Congress of the Turkish Neuromuscular Society

28-30 June 2018 | Avanos, Cappadocia, Turkey

SCIENTIFIC PROGRAMME

27 June 2018, Wednesday

19.00 – 19.30 Welcoming Lecture Followed by Reception

28 June 2018, Thursday

Limb-Girdle Dystrophies

Session 1. Genetics and Classification of Limb-Girdle Dystrophies

08.30 – 09.00 Classification and Pathophysiology
Marco Savarese, IT

09.00 – 09.30 Solve the Unsolved LGMDs: the Next Approach
Vincenzo Nigro, IT

09.30 – 10.00 The Gene Therapy Field in LGMD
Isabelle Richard, FR

10.00 – 10.30 Oculopharyngeal Muscular Dystrophy: From Bench to Bedside And Back Again
G Butler-Browne, FR

10.30 – 11.00 Break

Session 2. Clinical features of limb-girdle dystrophies

11.00 – 11.30 Clinical Features of Limb Girdle Dystrophies: an Overview
Jordi Diaz-Manera, SP

11.30 – 12.00 Metabolic Myopathies Mimicking Limb Girdle Dystrophy
Corrado Angelini, IT

12.00 – 12.30 Myofibrillar Myopathies
Duygu Selcen, USA and TR

12.30 – 13.00 Muscular Dystrophies with Mental Retardation
Haluk Topaloglu, TR

13.00 – 14.00 Lunch, Poster Viewing

14.00 – 15.30 Oral Presentations

15.30 – 16.00 Break

16.00 - 17.30 Posters

17.30 - 19.00 MSM General Assembly

20.00 – 24.00 Gala Dinner

**13th Meeting of the Mediterranean Society of Myology
in connection with the
2nd Congress of the Turkish Neuromuscular Society**

28-30 June 2018 | Avanos, Cappadocia, Turkey



SCIENTIFIC PROGRAMME

29 June, Friday

Session 3. Advances and Therapies I

- 09.00 – 09.30 Genetic Diagnosis**
Roula Cristodoulou, Cyprus
- 09.30 – 10.00 Laminopathies**
Giselle Bonne, FR
- 10.00 – 10.30 Dysferlinopathy, Calpainopathy and Imaging**
Giorgio Tasca, IT
- 10.30 – 11.00 Contribution of Muscle Biopsy in Diagnosis of LGMD in the Third Millennium**
Rita Baresi, UK
- 11.00 – 11.30 Break**

Session 4. Advances and therapies II

- 11.30 – 12.00 Future of genetics**
Judith Melki, FR
- 12.00 – 12.30 Clinical and Molecular Heterogeneity in Limb-Girdle Muscular Dystrophies**
Giacomo Comi, IT
- 12.30 – 13.00 Cardiac Involvement in Muscular Dystrophies: Contribution of the Naples's School**
Luisa Politano, IT
- 13.00 – 13.30 Treatment of Pompe Disease**
Antonio Toscano, IT
- 13.30 – 14.30 Lunch, Poster Viewing**

Session 5. Advances and therapies III

- 14.30 – 15.00 Update in spinal muscular atrophy treatment**
Eugenio Mercuri, IT
- 15.00 – 15.30 Therapy of GNE Myopathy**
Zohar Argov, IL
- 15.30 – 16.00 Duchenne Muscular Dystrophy: Future Perspectives**
Yoram Nevo, IL
- 16.00 – 16.30 Sarcoglycanopathies, Therapeutic Approaches**
Dorianna Sandona, IT

Closure of the meeting



**13th Meeting of the Mediterranean Society of Myology
in connection with the
2nd Congress of the Turkish Neuromuscular Society**

28-30 June 2018 | Avanos, Cappadocia, Turkey

TOPICS & PARTICIPANTS & IMPORTANT DATES

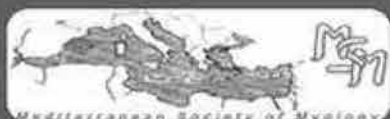Topics of the congress:
Limb-girdle muscular dystrophies
Advances in the field

Extra activity 1: 26-27 June 2018
Clinical neuromuscular course for physicians

Extra activity 2: 27 June 2018
Outcome measures course for physiotherapists

World Muscle Society members are highly specialised professionals active in the neuromuscular field, are on research for neuromuscular disorders or involved in the management of patients with these disorders.

IMPORTANT DATES	
Beginning of Abstract Submission & Registration	1 January 2018
Abstract Submission Deadline	30 April 2018
Early Bird Registration Deadline	30 April 2018
Pre-Congress Course Registration Deadline	15 May 2018



**13th Meeting of the Mediterranean Society of Myology
in connection with the
2nd Congress of the Turkish Neuromuscular Society**

28-30 June 2018 | Avanos, Cappadocia, Turkey

CAPPADOCIA



Cappadocian Region displays a beautiful combination of nature and history.

Some three million years ago, violent volcanic eruptions covered the plateau in this area with tufa, a soft stone comprised of lava, ash and mud. Subsequently, the wind and rain have eroded the brittle rock to form a spectacular surrealistic landscape of rock cones and capped pinnacles, called “fairy chimneys” that are painted in colors ranging from warm reds and gold to cool greens and grays. Fairy chimneys and carved houses and churches inside these formations and adorned these settlements with frescos, carrying the traces of the thousands of years of their civilizations. During Byzantine times, Christian chapels and monasteries were hollowed out of the rock, and later these dwellings served as refuge for Christians, persecuted by the Romans.

Göreme National Park and Cappadocia were placed on the UNESCO World Heritage List in 1985 as 7 parts: Göreme National Park, Derinkuyu Underground City, Kaymaklı Underground City, Karlı Church, Theodore Church, Karain Güvercinlikleri (Karain Columbaries) and Soğanlı Archaeological Site.

Hot-air ballooning is very popular in Cappadocia and is available in Goreme. Daily hot-air balloon tours are organized in various concepts (from an hourly trip to lunch&dinner trips) and you can enjoy the fascinating view from the wonderful sky.

BENEFITS OF SPONSORS

- Sponsor companies will be show-casing in front of a elite, highly specialised professional group
- With its geographical outreach, Cappadocia is accesible for participants from all around Europe and Middle - Near East
- Participating companies will book their place in setting that will shape the future trends in development of drugs and equipment in the field
- Brand awareness for participating companies will be raised during the all event and will be set for a higher level for it will be a unique and vivid meeting
- Direct contact with trend-setters
- Direct exposure to possible clients

For application or renewal to MSM

MEDITERRANEAN SOCIETY OF MYOLOGY* (MSM)

H. Topaloglu, *President*

L.T. Middleton, G. Siciliano, *Vice-Presidents*

K. Christodoulou, *Secretary*

L. Politano, *Treasurer*

APPLICATION/RENEWAL FORM

Application/Renewal for 1yr 2 yrs

☐☐

Prof. Luisa Politano, Cardiomiologia e Genetica Medica, Primo Policlinico, piazza Miraglia, 80138 Napoli, Italy

Fax: 39 081 5665101 E-mail: actamyologica@gmail.com • luisa.politano@unicampania.it

Fax or Mail to the above address. Type or print.

Name _____ Degree(s) _____
Last First

Department _____

Institution _____

Street Address _____

City, State, zip, country _____

Tel (_____) _____ Fax (_____) _____
Area code Area code

* Amount payable: 1 year Euro 100
2 years Euro 150



I enclose copy of the bank transfer to:

Bank name: Banco di Napoli – Filiale 00660

Bank address: Via Riviera di Chiaia, 131 – 80122 Napoli, Italy

Account holder: MSM – Mediterranean Society of Myology

IBAN code: IT48T0101003488100000100680

BIC code (for foreign countries): IBSPITNA



AUTHOR INDEX

A

Alaimo S. 73
Albamonte E. 57, 61, 81, 85, 91
Ali G. 67, 93
Al-Khalidi R. 61
Allegorico L. 72
Altamura C. 77, 81, 89
Amati A. 61
Ambati J. 61
Ambati K. 61
Ambrosi A. 64
Angela A. 80
Angelini C. 60, 62, 63, 66, 83, 87
Angheben A. 86
Anna L. 80
Ansone V.A. 77
Antonaci L. 68, 88
Antonini G. 54, 65, 67
Aquaro G.D. 90
Ardissone A. 94
Arkle S. 61
Armaroli A. 55
Armstrong G. 69, 74, 83
Arrigo R. 56, 57, 86
Assereto S. 47
Astrea G. 55, 57, 68, 76, 82, 85, 90, 93, 97
Auvinen P. 91
Avanti C. 78

B

Baba A. 87
Bagnato M.R. 84
Baldacci J. 60, 84, 85, 96
Baldanzi A. 90
Baldanzi S. 63, 68, 93
Baldassari S. 47
Baldelli E. 56, 69
Baldinotti F. 67, 90, 93
Balottin U. 90
Bandettini R. 76
Baranello G. 43, 57, 69, 83
Baratto S. 47, 95
Barbone F. 70, 94
Barison A. 67
Barresi R. 86
Bassez G. 43
Battezzati A. 43
Battini R. 76, 82
Bellacchio E. 74, 77
Bello L. 57, 59, 65, 70, 71, 79, 85, 90, 96
Benedetti L. 73, 75
Benedetti S. 55, 67
Bengtsson N. 43
Bentivogli M. 87

Berardinelli A. 55, 57, 90
Bergauer T. 74
Bernardini S. 94
Bernardo D. 89
Bernasconi P. 48, 77, 81, 91
Beronio A. 73
Berti B. 77
Berti G. 87
Bertini E. 55, 57, 61, 66, 74, 77, 79, 85, 94, 97
Bertini E.S. 67, 95
Bertoli S. 43
Bettica P. 59
Beuvin M. 54
Bevilacqua J. 54
Bharucha-Goebel D.X. 65
Bicciato S. 60
Bobeica E. 78, 79
Boccone L. 85
Bohm J. 55
Bombardieri L. 79
Bonaldi P. 64
Bonanno C. 70
Bordoni A. 86
Bordugo A. 82
Borgione E. 85
Borlenghi E. 69
Bortolani S. 66, 97
Bortolotti C. 67
Boschi S. 66
Bosè F. 78, 90
Botta A. 93
Bovis F. 68
Bozzetti S. 71
Bozzoni V. 71
Bracci Laudiero L. 83
Brakovic S. 81
Bravver E. 65
Bresolin N. 59, 96
Brigati G. 71, 74, 79
Brigonzi E. 90
Brizzi T. 56, 70, 72, 77
Brocard J. 54
Brochier G. 54, 55, 67
Broda P. 54, 95
Brugnoni R. 81, 91
Bruno C. 47, 54, 57, 61, 71, 74, 76, 78, 79, 80, 84, 85, 95
Bruno G. 72
Brusa R. 59, 96
Bruzzone S. 47
Bucci E. 65, 67, 95
Buchbjerg J. 83
Bushby K. 65

C

Cabona C. 73
Cali Cassi L. 67, 93
Caligo M.A. 67
Camerino G.M. 73, 81
Camilot M. 82
Campione E. 93
Canapicchi R. 91
Canti V. 64
Capitanio D. 60
Cappellari O. 48, 52
Capra V. 92
Caramori S.G. 57
Carboni N. 55
Cardani R. 78, 90
Carelli V. 94
Caria F. 56, 64, 69
Carlino R. 94
Carnicella S. 77
Carraro E. 81, 91
Carratù M.R. 77, 89
Carrozzo R. 89
Casiraghi J. 81
Cassandrini D. 68, 87, 95, 96
Castori M. 85
Catanzaro S. 73
Catteruccia M. 61, 66, 74
Cau M. 85
Cavalli M. 78
Cava M. 64
Cazzaniga S. 59
Cecchi P. 63
Cecconi A. 55
Cenacchi G. 60, 67, 71
Cescon M. 64
Chamberlain J.R. 43
Chamberlain J.S. 43
Chartner V. 55
Chiadò-Piat L. 66
Chico L. 67, 93
Chira N. 61
Chiriboga C. 74
Cinnante C. 59, 81, 96
CINRG DNHS Investigators 58
Cintoni M. 88
Cioni G. 82
Ciranni A. 56, 86
Cleary Y. 69, 74, 83
Coirault C. 44
Colacicco G. 89
Collotta A.D. 73
Colombo B. 67
Colombo M. 64
Comi G. 81, 93

Comi G.P. 44, 57, 59, 79, 81, 82, 85, 86, 88, 96
 Conte Camerino D. 77
 Conte D. 81, 89
 Conte E. 73, 81
 Coratti G. 68, 88
 Corricelli M. 87
 Corti S. 44, 59, 81, 96
 Cosini C. 93
 Cosottini M. 63
 Costa R. 60, 67, 71
 Cotti Piccinelli S. 56, 64, 69
 Cox P. 61
 Cravero A. 82
 Crudele J. 43
 Cuccagna C. 89
 Cudia P. 87
 Czech C. 69, 83

D

D'Abbicco D. 61
 D'Ambrosio P. 74, 75
 D'Amico A. 45, 55, 57, 61, 66, 74, 77, 79, 81, 85, 97
 D'Amore F. 76, 85, 91
 Danese A. 87
 D'Angelo G. 57, 67, 79
 D'Angelo M.G. 59
 Daniotti M. 76
 Darras B. 68, 69
 Day J.W. 65, 68, 69
 Dazzi F. 54
 De Amicis R. 43
 De Antonio M. 43
 De Bellis M. 73
 De Benedetti F. 83
 De Cobelli F. 64
 Deconinck N. 69
 De Cosmo L. 80
 De Fino C. 58
 Del Bo R. 85, 88
 De Lorenzo R. 64
 De Luca A. 73
 De Luca F. 86
 De Marco P. 92
 De Mattia E. 57, 75
 Demichelis C. 75
 De Rosa A. 92
 De Rosa G. 77
 De Sanctis R. 68, 77
 Desaphy J.-F. 45, 77, 89
 Desaphy J.F. 81
 De Vivo D.C. 68
 Diana M. 76
 Díaz-Manera J. 65
 Dickson G. 59, 62
 Di Donato I. 87

Di Iorio G. 72
 Dilena R. 96
 Di Muzio A. 70, 94
 Diodato D. 94
 Di Pasquale A. 65, 67
 Di Rocco M. 95
 Di Stefano V. 70
 Di Vito L. 94
 Dobrowolny G. 73
 Doccini S. 91, 95, 96
 Dogan C. 43
 Doglio L. 84
 Domingos J. 59, 62
 Donati A. 54, 55
 Donati M.A. 76, 84, 95
 Dosi C. 76
 Dotti M.T. 87
 Duchen M.R. 52
 Dugar A. 58
 Dunaway Young S. 68
 Duong T. 68, 70

E

Eabrook T. 69
 Eglon G. 86
 Emdin M. 90
 Eschenhagen T. 52
 Evangelista T. 45, 78

F

Fabbri S. 73, 80
 Fabris M. 85
 Fagiolari G. 88, 96
 Falcier E. 75
 Falsaperla R. 54, 73
 Falzarano M.S. 60, 85, 92
 Fang M. 60
 Faraone C. 63
 Fardeau M. 55
 Farinato A. 77
 Fattori F. 66, 67, 74, 77, 95
 Fazio R. 64
 Feng L. 55
 Ferlini A. 46, 55, 60, 64, 71, 78, 85, 92
 Fernandez-Torrón R. 65
 Ferrante C. 70
 Ferrantini G. 77
 Ferrari A.R. 91
 Ferrari G. 52
 Ferrari N. 78
 Ferrari S. 86
 Ferretti M. 78, 79
 Ferri L. 76
 Festa S. 85
 Ficili S. 95
 Filosto M. 46, 50, 56, 59, 64, 69, 77, 94
 Fini S. 92

Finkel R.S. 68
 Fionda L. 65
 Fiorillo C. 47, 54, 55, 60, 68, 71, 73, 74, 76, 80, 83, 85, 92, 95
 Fischer D. 74
 Fiumara A. 77
 Florio F. 90
 Fontana L. 93
 Fonzino A. 73, 89
 Foppiani A. 43
 Forcina N. 68, 77, 88
 Fortunato F. 78, 85, 86
 Fossati B. 78, 90
 Fragiotta G. 65
 Francesco G. 80
 Francini-Pesenti F. 47
 Frank D.E. 59, 62
 French Myotonic Dystrophy Study Group 43
 Frezza E. 94
 Frosini S. 68, 82
 Fusto A. 79

G

Gaeta M. 57, 72
 Gagliardi D. 81
 Gal A. 55
 Galimberti V. 79, 88
 Gallizzi R. 86
 Gallo Cassarino S. 56, 64, 69
 Galvagni A. 56
 Gandolfo C. 79
 Gandossini S. 57, 59
 Garibaldi M. 54, 62, 65, 67, 95
 Gasbarrini A. 88
 Gazzero E. 47, 54, 61, 95
 Gelblin K. 69
 Gelfi C. 60
 Gemelli C. 73, 80
 Genova C. 75
 Gerber M. 69, 74, 83
 Ghezzi D. 55
 Giannini M. 61
 Giannoni A. 90
 Giannotta M. 50
 Giaquinto E. 43
 Giardina E. 85
 Giaretta L. 60, 87
 Gibertini S. 80, 91
 Giliani S. 56
 Giorgi C. 87
 Girolamo F. 61
 Glanzman A.M. 68
 Goemans N. 83
 Gordish-Dressman H. 58, 70
 Górecki D.C. 61
 Gorni K. 69, 74, 83

Gotti E. 81
 Govi M. 97
 Govoni A. 59, 81, 96
 Gragnani F. 62
 Granata G. 88
 Grandi C. 81
 Grandis M. 73, 75, 80
 Greco G. 94
 Gregorio I. 64
 Grilli A. 60
 Grisanti S. 75
 Grossi A. 65
 Grossi F. 75
 Gualandi F. 60, 64, 78, 85, 92
 Guglielmi V. 71
 Guglieri M. 59, 62

H

Hackman P. 91
 Hall J. 43
 Hamroun D. 43
 Han L. 58
 Harbaran S. 48
 Hauschka S.D. 43
 Heinig K. 63
 Henderson A.B.H. 52
 Henricson E. 58, 70
 Hoffman E.P. 70
 Huovinen S. 91

I

Iacomino M. 95
 Iannone F. 61
 Imbrici P. 77, 81, 89
 Incontrera A. 79
 Italian EAP working group 61
 Italian Network for Laminopathies 48, 55

J

Jones K.J. 65
 Jonson H. 91

K

Khan N. 58
 Khedr M. 52
 Khwaja O. 69, 74, 83
 Kiriko G. 55
 Kirschner J. 83
 Klein A. 69
 Kletzl H. 69, 74, 83
 Kotiadis V.N. 52
 Kraus S. 74

L

Labasse C. 54, 55, 67
 Labate V. 78
 Lacene E. 54
 La Foresta S. 63
 Laforêt P. 47
 Laforgia N. 80
 Laganà G. 63
 La Morgia C. 94
 Lamperti C. 94
 Lanteri P. 92
 Lanzafame M. 86
 Lanzi G. 56
 Lanzillotta V. 57
 Lapenta L. 88
 Laporte J. 55
 Lapucci C. 75
 Laschena F. 84
 Lasorsa F.M. 87
 Lattanzi G. 48, 55
 Lelli S. 71
 Lembo F. 93
 Lenzi S. 82
 Leonardi L. 65
 Leone A. 43
 Lerario A. 79, 82, 88, 91
 Levy-Borsato F. 54
 Lia A. 61
 Liantonio A. 73, 89
 Lizio A. 75, 81
 Lo Giudice M. 85
 Lo Monaco L. 57
 Lo Monaco M. 77, 81
 Longo A. 74
 Lornage X. 55
 Lozzi F. 94
 Lubieniecki F. 54
 Lucchiari S. 81, 86
 Lucchini M. 58
 Luigetti M. 88, 89
 Lu-Nguyen N. 48
 Lupica A. 56, 72
 Lu Z. 60

M

Maccarrone G. 71
 Macchione F. 71, 82
 Madelaine A. 54, 55
 Madeo A. 95
 Madia F. 95
 Maestri M. 92
 Maffioletti S.M. 52
 Maggi L. 48, 55, 67, 77, 80, 81, 91
 Magnusson O.T. 55
 Magri F. 57, 59, 81, 85, 96
 Main M. 68
 Malandrini A. 87

Malerba A. 48
 Malfatti E. 54, 55
 Mancardi G.L. 73
 Mancuso M. 94
 Mandich P. 80
 Mannhardt I. 52
 Mannironi A. 73
 Mantegazza R. 77, 81
 Marchesi M. 56, 64, 69
 Marica M. 85
 Marini F. 84
 Marni J. 65
 Marotta J. 89
 Marozzo R. 60, 66, 83
 Marrosu G. 55
 Martinelli D. 94
 Martinelli I. 96
 Martinuzzi A. 57
 Marty I. 54
 Massa R. 93, 94
 Masson R. 69
 Mastella C. 43
 Mastrangelo M. 82
 Mauro A. 78, 85
 Mayhew A. 68
 Mayhew A.G. 65
 Mazzone E.S. 68
 McDonald C.M. 58, 70
 McGeehan R.E. 61
 Mela J. 85
 Melani F. 96
 Mele F. 97
 Mele M.C. 88
 Melis M.A. 85
 Mendell J.R. 65
 Meola G. 78, 81, 90, 93
 Mercuri E. 55, 57, 59, 61, 62, 68, 69, 74, 77, 79, 83, 85, 88, 90
 Merello E. 92
 Merla G. 85
 Messina S. 57, 61, 72, 79, 85, 97
 Miggiano G. 88
 Mignarri A. 87
 Milone M. 49
 Minetti C. 47, 50, 54, 68, 71, 76, 78, 79, 80, 83, 95
 Mirabella M. 58
 Missaglia S. 62
 Mitchell J.S. 52
 Moggio M. 59, 74, 79, 80, 81, 82, 85, 86, 88, 96
 Mollar E. 75
 Moneta G.M. 83
 Monforte M. 58, 59, 62, 84
 Monges S. 54
 Mongini T. 55, 57, 66, 81, 90, 97
 Montano V. 67, 93
 Montes J. 68

Monti B. 87
 Montobbio G. 79
 Mora M. 62, 67, 80, 88, 91
 Morandi L. 80
 Morani F. 76, 91
 Morasso P. 84
 Moretti E. 82
 Morettini V. 91
 Moretti P. 84
 Morgan J. 59, 62
 Moriggi M. 60
 Morino S. 65, 67
 Mori-Yoshimura M. 65
 Moro F. 84
 Moroni I. 49, 94
 Morrone A. 76
 Moscardi M. 91
 Moyle L.A. 52
 Mueller L. 63
 Mugnosso M. 84
 Muni Lofra R. 68
 Muntoni F. 55, 59, 62, 68
 Murdocca M. 93
 Musarò A. 73
 Musumeci O. 56, 57, 70, 86, 94

N

Naryshkin N. 63
 Nasca A. 55
 Neri M. 55, 60, 78, 85, 92
 Neri S. 92
 Nesti C. 71, 76, 85, 91, 95
 Nicolai R. 83
 Nicoletti T.F. 88
 Nigro V. 49, 74, 80, 85
 Novelli G. 93
 Nuccetelli M. 94

O

Orsini C. 75
 Osman H. 60
 Oteri R. 86
 Ottaviani P. 84

P

Padovani A. 56, 64, 69
 Pagliarani S. 81, 86
 Palladino A. 75
 Pancheri E. 71, 86, 94
 Pane M. 55, 57, 61, 68, 77, 79, 88
 Panicucci C. 47, 61, 84, 95
 Papa V. 60
 Paradas C. 65, 67
 Parkhurst Y. 86
 Pasquariello R. 76, 91

Pasquini E. 76
 Passamano L. 75
 Pasternak A. 68
 Pastorino M. 85
 Patani R. 52
 Pati A.R. 87
 Paulin L. 91
 Paushkin S. 63
 Pecini C. 82
 Pedemonte M. 50, 54, 57, 61, 74, 76, 78, 79
 Pegoraro E. 55, 57, 59, 65, 71, 79, 81, 85, 90, 96
 Pegoraro V. 60, 66, 83, 87
 Pena L. 87
 Pennisi E.M. 62, 67, 95
 Pera M.C. 68, 83, 88
 Perna A. 88
 Pestronk A. 65
 Petillo R. 75
 Petralla S. 87
 Peverelli L. 50, 59, 79, 82, 88, 91, 94, 96
 Phadke R. 55
 Pharmaceutical Sciences,
 Roche Pharma Research and
 Early Development,
 Roche Innovation Center, 63
 Picco P. 92
 Pichiecchio A. 56, 84
 Piemontese M.R. 85
 Pierno S. 73, 81, 89
 Piga D. 81, 96
 Pini A. 50, 76, 79
 Pinton L. 52
 Pinton P. 87
 Piras R. 85
 Pires Marafo D. 83
 Pirola A. 75
 Pochiero F. 76, 84, 95
 Poeta E. 87
 Pogoryelova O. 86
 Poirier A. 63
 Poli C. 50
 Politano L. 48, 50, 55, 57, 74, 75, 79, 81, 85
 Ponzalino V. 97
 Popplewell L. 59, 62
 Pozzolini G. 95
 Previtali S. 55, 57, 59
 Previtali S.C. 64, 67
 Primiano G. 66, 89, 94
 Primiano G.A. 58
 Procopio E. 76, 84
 Pulvirenti A. 73

Q

Queirolo P. 75

R

Raffaghello L. 47
 Ragazzi M. 52
 Ramirez G.A. 64
 Ramsey D. 68
 Rao F. 57, 75
 Rastelli E. 94
 Ratni H. 63
 Ravelli A. 53, 83
 Rendu J. 54
 Renna L.V. 90
 Renna L.V. 78
 Resta N. 80
 Ricciardi R. 92
 Ricci E. 58, 84
 Ricci F. 90
 Ricci G. 55, 57, 63, 67, 68, 81, 90, 93
 Ricci M. 88
 Rimessi P. 64, 71, 85, 92
 Rinninella E. 88
 Ripolone M. 79, 86
 Risato R. 71
 Rocchi A. 90
 Rodia M.T. 60
 Rodolico C. 51, 55, 56, 70, 72, 77, 86, 88
 Róg J. 61
 Rolle E. 90
 Roma E. 75
 Romano C. 54, 73
 Romero N.B. 54, 55, 67
 Ronchetto P. 92
 Ronchi D. 81
 Rosina S. 53, 83
 Rossi A. 95
 Rossi M. 90
 Rossi R. 55, 60, 64, 85, 92
 Rossi S. 88
 Rosso T. 71
 Roth F. 48
 Rovere Querini P. 64
 Rubegni A. 68, 71, 76, 84, 85, 91, 94, 95, 96
 Ruggeri P. 57
 Ruggieri A. 67, 80, 91
 Ruggieri M. 73
 Ruggiero L. 60

S

Sabatelli P. 48
 Sacchini M. 76

Sahbani D. 81
 Salmaso F. 71
 Salmin F. 91
 Salort-Campana E. 65
 Salvatore S. 87
 Salviati L. 82
 Sampaolo S. 72
 Sancricca C. 89
 Sandri M. 51
 Sangiuolo F. 93
 Sansone V. 57, 59, 61, 75, 81
 Sansone V.A. 81, 85, 91
 Santorelli F. 50, 93
 Santorelli F.M. 52, 60, 68, 71, 76, 84, 85, 87, 91, 94, 95, 96, 97
 Santoro L. 60
 Sarcas S. 52
 Saredi S. 80, 91
 Sartoris S. 86
 Sauchelli D. 89
 Savarese M. 68, 91
 Savasta S. 54
 Sbanò L. 87
 Scala M. 92
 Scali M. 79, 88
 Scalise R. 90
 Scarlato M. 64, 67
 Scaturro G. 76
 Schena E. 48
 Schenone A. 73, 75, 80
 Schirinzi E. 92
 Schnell F. 59, 62
 Sciacco M. 79, 82, 88, 96
 Scotto M. 68
 Scotton C. 55
 Scuderi C. 85
 Scutifero M. 75, 79
 Seferian A. 59, 62
 Selvatici R. 55, 60, 85, 92
 Semplicini C. 55, 59, 65, 71, 96
 Serlenga L. 61, 80
 Servais L. 59, 62, 69, 83
 Servidei S. 58, 66, 89, 94
 Severino M.S. 71, 92
 Sewry C. 55
 Sframeli M. 61, 97
 Siciliano G. 50, 55, 57, 63, 67, 68, 77, 81, 90, 92, 93, 94
 Silvestri G. 88
 Simoncini C. 63, 68, 90, 93, 94
 Sivo S. 88
 SKIP-NMD Study Group 59, 62
 Smith F. 65
 Sorarù G. 96
 Sorbo M. 96
 Sormani M.P. 68

Spazzini L. 82
 Spitalieri P. 93
 Spuler S. 65
 Stancanelli C. 61, 63
 Steele-Stallard H. 52
 Stefan C. 57
 Sternberg D. 77
 Stojkovic T. 65
 Straub V. 59, 62, 65, 86
 Strings-Ufombah V. 48

T

Tacchetti P. 57, 74, 78
 Talarico V. 93
 Tampoia M. 61
 Tanda E. 75
 Taratuto A.L. 54
 Tasca G. 84
 Tasfout H. 43
 Tassano E. 92
 Tassinari C. 71
 Tavian D. 62
 Tedeschi S. 85
 Tedesco F.S. 52
 Telese R. 70, 94
 Teofoli F. 82
 Terracciano C. 94
 Tessa A. 85
 The Jain COS Consortium 65
 Thompson N. 74
 Ticci C. 94
 Tironi R. 79, 82, 88
 Tolomeo D. 95
 Tonin P. 71, 82, 86, 94
 Torchia E. 67, 95
 Torella A. 80
 Torracco A. 89
 Torretta E. 60
 Torri F. 68
 Toscano A. 53, 56, 57, 70, 72, 81, 86, 88, 94
 Trabanelli C. 85, 92
 Travaglini L. 85
 Traverso M. 68, 95
 Trevisan L. 80
 Trevisi E. 57
 Tripodi S.M. 96
 Trojano M. 61, 80
 Trovato R. 96
 Trucco F. 78
 Tubili F. 76
 Tupler R. 65, 97
 Tyzack G.E. 52

U

Udd B. 91
 Ulzi G. 81, 86

V

Vanoli F. 65
 Varone A. 72
 Vattemi G. 71, 82, 86
 Vavla M. 57
 Velardo D. 59, 64, 67, 81, 96
 Venturoli A. 92
 Verardo M. 67, 74, 77, 83
 Vercelli L. 66
 Vercelli L. 55, 81, 97
 Verrigni D. 89
 Vezzulli P. 67
 Vial C. 77
 Vianello A. 57
 Vicario G. 71
 Villa M. 57
 Vincenzi M. 82
 Violano R. 86
 Vita G. 56, 61, 63, 70, 72, 97
 Vita G.L. 57, 63, 79, 85, 97
 Vitale M. 70, 94
 Vitaliti G. 73
 Vollono C. 89
 Volta S. 56

W

Wake R. 86
 Walter M.C. 65
 Wang W. 52
 Weaver D. 55
 Weetall M. 63
 Wells D.J. 52
 Wells K.E. 52

Y

Young C.N.J. 61

Z

Zabłocki K. 61
 Zaharieva I. 55
 Zammit P.S. 52
 Zamò A. 86
 Zara F. 95
 Zenzeri J. 84
 Zeviani M. 55
 Zirilli G. 86
 Zoni L. 50

INSTRUCTIONS FOR AUTHORS

Acta Myologica publishes articles related to research in and the practice of primary myopathies, cardiomyopathies and neuromyopathies, including observational studies, clinical trials, epidemiology, health services and outcomes studies, and advances in applied (translational) and basic research.

Manuscripts are examined by the editorial staff and usually evaluated by expert reviewers assigned by the editors. Both clinical and basic articles will also be subject to statistical review, when appropriate. Provisional or final acceptance is based on originality, scientific content, and topical balance of the journal. Decisions are communicated by email, generally within eight weeks. All rebuttals must be submitted in writing to the editorial office.

On-line submission

Manuscript submission must be effected on line: **www.actamyologica.it** according to the following categories:

Original articles (maximum 5000 words, 8 figures or tables). A structured abstract of no more than 250 words should be included.

Reviews, Editorials (maximum 4000 words for Reviews and 1600 words for Editorials). These are usually commissioned by the Editors. Before spontaneously writing an Editorial or Review, it is advisable to contact the Editor to make sure that an article on the same or similar topic is not already in preparation.

Case Reports, Scientific Letters (maximum 1500 words, 10 references, 3 figures or tables, maximum 4 authors). A summary of 150 words may be included.

Letters to the Editor (maximum 600 words, 5 references). Letters commenting upon papers published in the journal during the previous year or concerning news in the myologic, cardio-myologic or neuro-myologic field, will be welcome. All Authors must sign the letter.

Rapid Reports (maximum 400 words, 5 references, 2 figures or tables). A letter should be included explaining why the author considers the paper justifies rapid processing.

Lectura. Invited formal discourse as a method of instruction. The structure will be suggested by the Editor.

Congress Proceedings either in the form of Selected Abstracts or Proceedings will be taken into consideration.

Information concerning new books, congresses and symposia, will be published if conforming to the policy of the Journal.

The manuscripts should be arranged as follows: 1) Title, authors, address institution, address for correspondence; 2) Repeat title, abstract, key words; 3) Text; 4) References; 5) Legends; 6) Figures or tables. Pages should be numbered (title page as page 1).

Title page. Check that it represents the content of the paper and is not misleading. Also suggest a short running title.

Key words. Supply up to three key words. Wherever possible, use terms from Index Medicus – Medical Subject Headings.

Text. Only international SI units and symbols must be used in the text. Tables and figures should be cited in numerical order as first mentioned in the text. Patients must be identified by numbers not initials.

Illustrations. Figures should be sent in .jpeg or .tiff format. Legends should be typed double-spaced and numbered with Arabic numerals corresponding to the illustrations. When symbols, arrows, numbers, or letters are used to identify parts of the illustrations, each should be explained clearly in the legend. For photomicrographs, the internal scale markers should be defined and the methods of staining should be given.

If the figure has been previously published a credit line should be included and permission in writing to reproduce should be supplied. Colour photographs can be accepted for publication, the cost to be covered by the authors.

PATIENTS IN PHOTOGRAPHS ARE NOT TO BE RECOGNISABLE

Tables. Tables should be self-explanatory, double spaced on separate sheets with the table number and title above the table and explanatory notes below. Arabic numbers should be used for tables and correspond with the order in which the table is first mentioned in the text.

References. Reference numbers in the text must be in brackets. References in the list must be numbered as they appear in the text.

Standard journal article: Figarella-Branger D, Bartoli C, Civatte M, et al. Cytokines, chemokines and cell adhesion molecules in idiopathic inflammatory myopathies. *Acta Myol* 2000;19:207-8.

Books and other monographs: Dubowitz V. Muscle disorders in childhood. London: WB Saunders Company Ltd; 1978.

Please check each item of the following checklist before mailing:

- Three index terms, short title for running head (no more than 40 letter spaces) on the title page.
- Name(s) of the author(s) in full, name(s) of institution(s) in the original language, address for correspondence with telephone and fax numbers and email address on the second page.
- Summary (maximum 250 words).
- References, tables and figures cited consecutively as they appear in the text.
- Figures submitted actual size for publication (i.e., 1 column wide or 2 columns wide).
- Copyright assignment and authorship responsibility signed (with date) by all Authors.
- References prepared according to instructions.
- English style.
- Patients in photographs not recognisable.

